

The Use of Resin Cements in Restorative Dentistry to Overcome Retention Problems

(Utilisation des résines-ciments en dentisterie restauratrice pour surmonter les problèmes de rétention)

• Omar El-Mowafy, BDS, PhD, FADM •

S o m m a i r e

L'utilisation des résines-ciments avec des agents de liaison dentinaire peut renforcer l'adhésion des prothèses à la structure de la dent. Cet article décrit 4 cas cliniques dans lesquels les résines-ciments liées à la dentine ont été utilisées pour surmonter les problèmes de rétention. Dans le premier cas, une prothèse partielle fixe décimentée, en bon état une fois détachée, a été recimentée aux dents-piliers avec un angle de convergence moins qu'idéal. Dans le deuxième cas, une couronne décimentée tout céramique a été recimentée avec une résine-ciment liée à la dentine après que la surface ait été adéquatement traitée. Dans le troisième cas, une couronne céramo-métallique a été cimentée à une couronne clinique courte sans recours à un allongement chirurgical de la couronne. Dans le quatrième cas, une prothèse partielle fixe à 3 unités a été recimentée à des piliers dont les caractéristiques de support étaient moins qu'idéales. Les résines-ciments liées à la dentine peuvent aider à prolonger la durée de vie des prothèses décimentées jusqu'à ce que le patient soit financièrement prêt à se faire remplacer la dent ou peuvent permettre d'éviter l'allongement chirurgical de couronnes cliniques courtes.

Mots clés MeSH : crowns; dental prosthesis retention; resin cements

© J Can Dent Assoc 2001; 67:97-102
Cet article a fait l'objet d'une révision par des pairs.

Resin cements are gaining popularity in the dental profession for a number of reasons. The vast majority of non-metallic restorations, which are also utilized more at the present time than before, can be cemented only with resin cements. These restorations include ceramic and resin composite inlays and onlays as well as ceramic crowns and porcelain veneers. Resin cements are also the only cement material that can be used for cementation of resin-bonded fixed partial dentures.

Typically, resin cements are used in conjunction with enamel and dentin bonding agents and, as a result, are capable of micro-mechanical attachment to both structures through the bonding agent. They can also bond to appropriately treated fitted surfaces of restorations. This bonding is usually micro-mechanical in nature and occurs when the fitted surface of the restoration — ceramic, resin composite or metallic — has been microetched. Some resin cements are formulated in such a way that they possess an additional chemical agent to enable them to bond chemically to cast restorations made of non-precious metal alloys. Unlike resin cements, non-polymeric cements, such as zinc phosphate cement, generally cannot bond to either the tooth structure or the fitted surface of the restoration. One exception is glass ionomer cement, which can bond chemically to both dentin and enamel;

however, the strength of the bond is far less than what can be achieved with resin cements.

Another use of resin cements that has evolved and been adopted by dentists is the cementation of posts, both metallic and non-metallic. One study recommended the use of resin cements with dentin bonding agents when the length of the channel hole is less than ideal or when the hole is not rounded.¹ When the canal is short, the extra retention that the bonding produces compensates for the reduced length. When the canal is not rounded, the resin cement fills in the spaces and eliminates the need for a cast post.

In another study, a resin cement used in conjunction with a dentin bonding agent to attach crowns to teeth with short clinical crowns achieved approximately 3 times the attachment effected by phosphate cement.² For teeth with crown preparations with less-than-ideal angle of convergence, the attachment of crowns bonded with one resin cement was more than 6 times higher than the attachment achieved with zinc phosphate cement.² This implies that bonded resin cements can be useful as alternative cement material in clinical situations where retention of crowns or fixed partial dentures is compromised. In the case of a short clinical crown, the standard treatment would typically involve

surgical intervention to lengthen the clinical crown; however, the use of a resin cement in conjunction with a dentin bonding agent should be considered as a viable alternative. It would enable the dentist to avoid the surgical procedure and reduce the overall cost and complexity of the treatment, which might help to convince some apprehensive patients to accept the treatment.

Another frequently encountered clinical situation is when there is an edentulous space anterior to the lower first or second molar and the mesial drifting of the tooth caused it to become malaligned, with a consequent problem in the provision of a fixed partial denture. Typical treatment would involve a course of orthodontic treatment to straighten the malaligned molar before the prosthodontic work. Alternatively, elective root canal treatment of the molar tooth might be considered to enable sufficient reduction of the proximal surfaces such that they fall in parallel with those of the anterior abutment. The use of a bonded resin cement offers the possibility of avoiding such lengthy pre-prosthetic preparation of the case, and the molar abutment can be prepared with a less-than-ideal angle of convergence, thus avoiding causing pulpal injury.

The following selected cases illustrate how resin cements and dentin bonding agents can be used to overcome post-treatment retention problems.

Case 1

A 3-unit fixed partial denture replacing a maxillary left lateral incisor detached just one year after insertion. The initial luting agent was not known, however, the prosthesis was well fabricated with good colour match and was in good condition when separated (Fig. 1). Examination of the abutment teeth revealed that they had been prepared with less-than-ideal angle of convergence. The canine abutment was conical in shape, and the incisor abutment had an increased angle of convergence (Fig. 2). The work had been performed by a dentist in another city, and it was inconvenient for the patient to go back to that dentist for follow-up. The patient was not prepared to pay for a replacement prosthesis and wondered if there was a way to cement the original prosthesis back in place with a better result.

The only way by which enhancement of retention could be achieved in this situation would be through the use of a dentin-bonded resin cement. The fitted surface of the casting was cleaned of cement remnants and microetched using 50 µm aluminum oxide powder. This created the microscopic roughness necessary to ensure improved attachment of the casting to the resin cement. The dentin surfaces of the abutment teeth were pumiced, rinsed and acid-etched (Ultraetch, Ultradent, South Jordan, UT) for 20 seconds (Fig. 3). After rinsing with water for 10 seconds, the etched dentin surfaces were gently dried with a weak stream of air to avoid over-drying. A layer of Prime and Bond NT (Dentsply, Milford, DE), a primer/bonding resin, was then applied to the dentin surfaces and left undisturbed for 30 seconds. A weak stream of air was applied to aid evaporation of the solvent. Light-curing followed, and the dentin surfaces developed a shiny appearance (Fig. 4). Equal portions of Enforce (Dentsply, Milford, DE) were mixed following manufacturer's instructions. Enforce is a dual-cure resin cement that has a strong chemical-curing component.^{3,4} Excess cement that oozed at the marginal areas was subjected to brief light-curing for 5 seconds, which resulted in initial hardening of the excess and made it easy to

remove with an explorer. The prosthesis was maintained under pressure until cement hardening took place. Figure 5 shows the final result. Alternatively, a chemical-cure resin cement could have been used.

Case 2

A maxillary central incisor with an all-porcelain crown dislodged just one year after initial placement (Fig. 6). Examination revealed that the preparation had a less-than-ideal angle of convergence, which may have been the cause of failure. Another important factor that may have predisposed to failure was the treatment of the fitted surface of the crown. Unless thorough roughening of the fitted surface is achieved through microetching or other means, retention may suffer. The adjacent central incisor had an all-porcelain crown made at the same time. The cementing medium for these 2 crowns was not known. The patient wanted the dislodged crown recemented, as it was in excellent shape (Fig. 7). The fitted surface of the all-porcelain crown was first cleaned of cement debris and then microetched with 50 µm aluminum oxide powder. The tooth surfaces were treated as above and the crown was cemented with a resin cement. This crown continues to remain in place since it was recemented almost 4 years ago.

Case 3

A female patient presented with a lower left second molar that had a crown dislodged. The original crown was not available, and the treating dentist suggested surgical crown lengthening of the tooth to increase the height of the short clinical crown before provision of a replacement crown (Fig. 8). The patient was hesitant about the surgery and wondered if there was a way to avoid it. She was then referred by the treating dentist to the author. Following examination, it was explained to the patient that an alternative way to overcome the problem would involve improving the existing preparation, fabricating a new crown and using a bonded resin cement.

The tooth was first built up with a resin composite restorative, and the margins of the crown preparation were driven subgingivally to increase the height of the preparation walls (Fig. 9). The patient requested a porcelain-fused-to-metal crown with a porcelain occlusal surface similar to the one she had on the first molar; however, it was explained to her that to maintain the height of the crown at the maximum, which was of prime importance in this case, a metal surface (which requires minimal occlusal reduction) must be used. A porcelain-fused-to-metal crown was fabricated and its fitted surface was microetched. Following acid etching and priming of the dentin (All-Bond 2, Bisco Inc., Itasca, IL), the crown was cemented with a chemical-cure resin cement (All-Bond Crown and Bridge Cement, Bisco Inc., Itasca, IL) following manufacturer's instructions (Fig. 10). It has now been more than 4 years since this crown was cemented, and it continues to stay in place and to function satisfactorily.

Case 4

The patient presented with a dislodged lower 3-unit porcelain-fused-to-metal fixed partial denture that had been inserted 5 years earlier. Examination of the prosthesis revealed that it was intact; however, the marginal fit was less than ideal. The distal abutment was a vital tooth with an amalgam restoration, but the tooth had

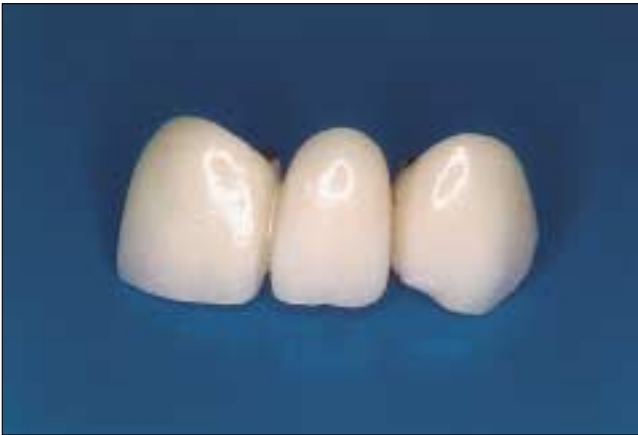

Figure 1: Dislodged anterior porcelain-fused-to-metal fixed partial denture one year after initial insertion. The prosthesis is in excellent condition, but the supporting structure had design errors.

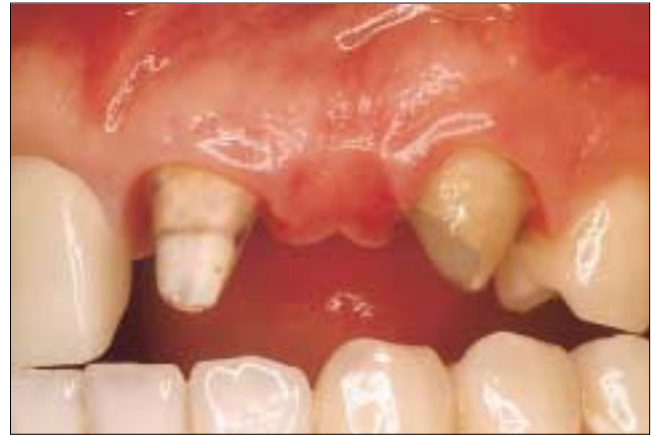

Figure 2: The abutment teeth supporting the fixed partial denture shown in Fig. 1. Note the conical shape of the canine abutment and the excessive angle of convergence of the incisor abutment.

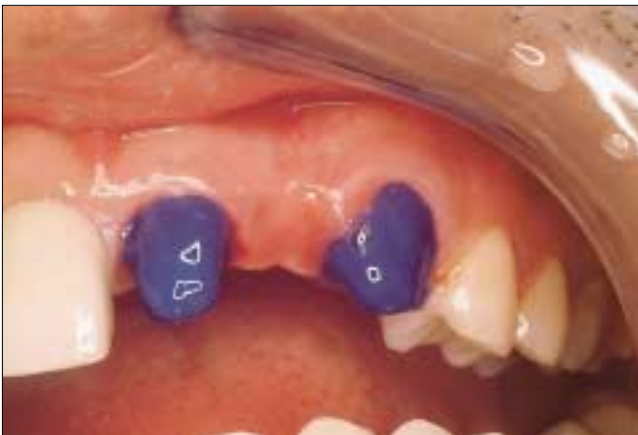

Figure 3: Following cleaning, the surfaces of the abutment teeth were etched with a phosphoric acid etchant gel for 20 seconds.

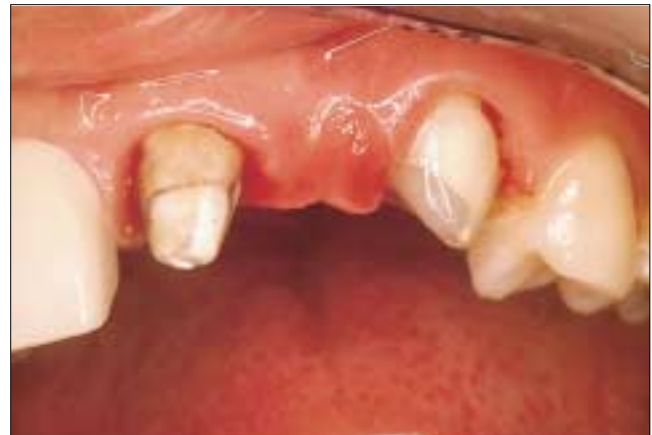

Figure 4: Following etching of the abutment teeth, the surfaces were primed with a dentin bonding agent. Note the shiny appearance of the dentin surfaces after this step. The shine is a good indication of thorough priming.

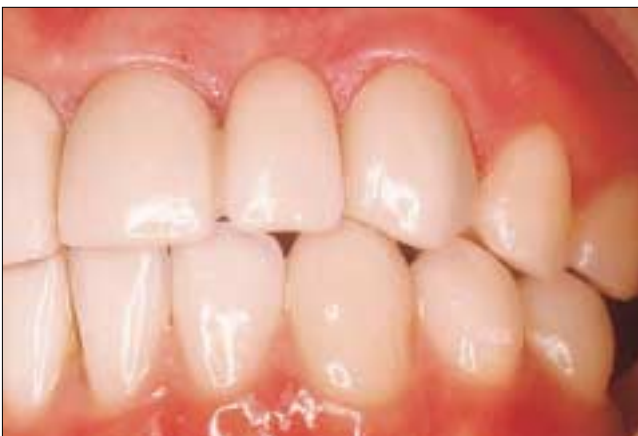

Figure 5: Post-operative view after cementation of the original prosthesis with a resin cement. Note the excellent colour match.

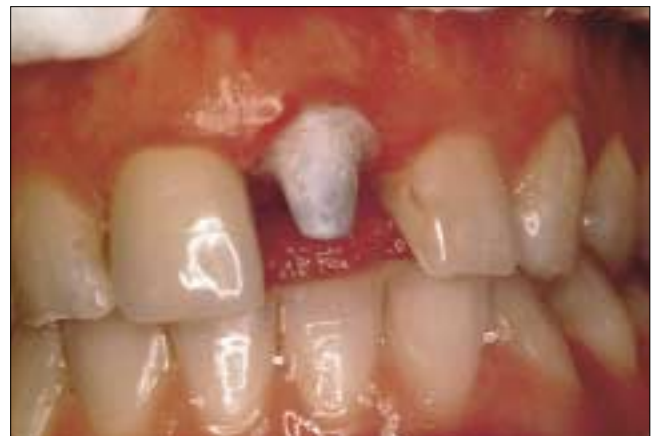

Figure 6: This maxillary central incisor had an all-porcelain crown that dislodged just one year after initial insertion. The tooth was prepared with an excessive angle of convergence.

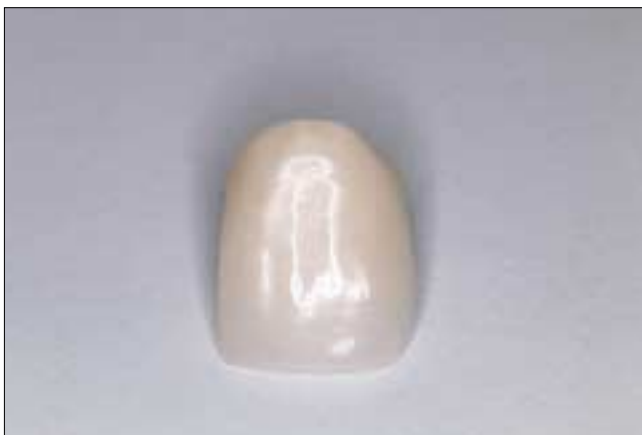

Figure 7: This all-porcelain crown belonged to the tooth in Fig. 6. Note the excellent condition of the crown.

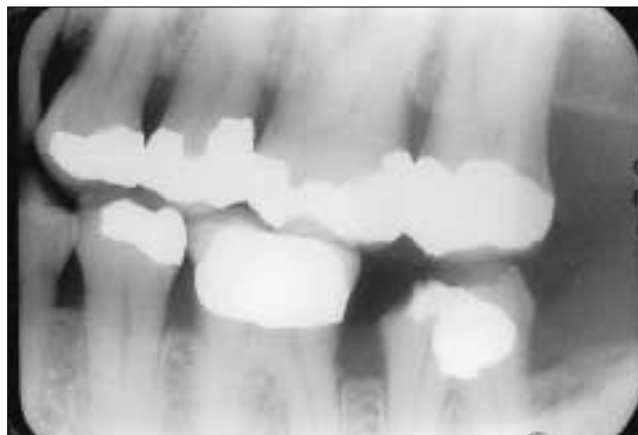


Figure 8: Bitewing radiographic image of mandibular second molar tooth from which a crown dislodged.

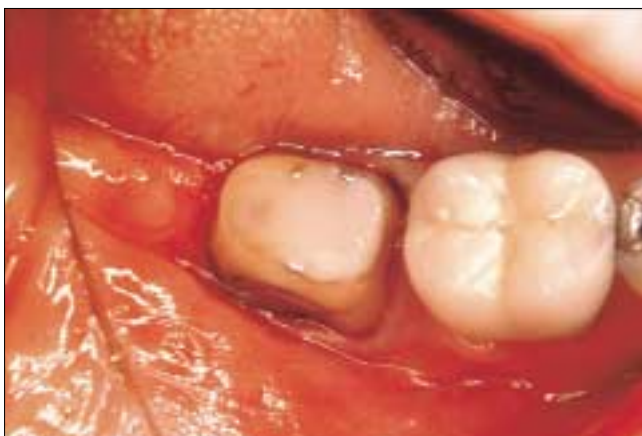

Figure 9: The mandibular second molar shown in Fig. 8 after restoration with a resin composite material and extending the original crown preparation subgingivally.

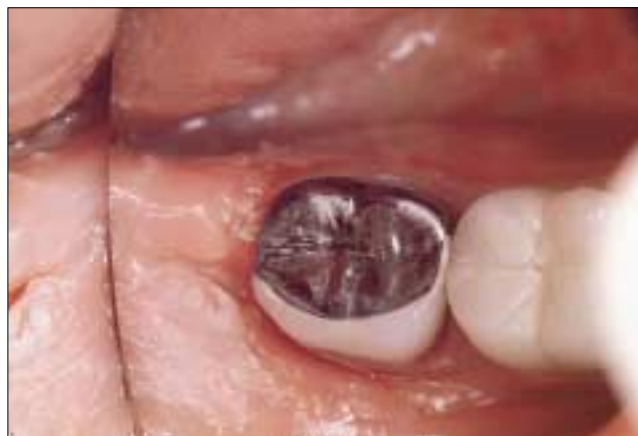

Figure 10: The fabricated porcelain-fused-to-metal crown was cemented with a resin cement following a bonding procedure to enhance retention. The occlusal surface of the crown had to be made in metal to minimize occlusal reduction and thus maximize crown height.

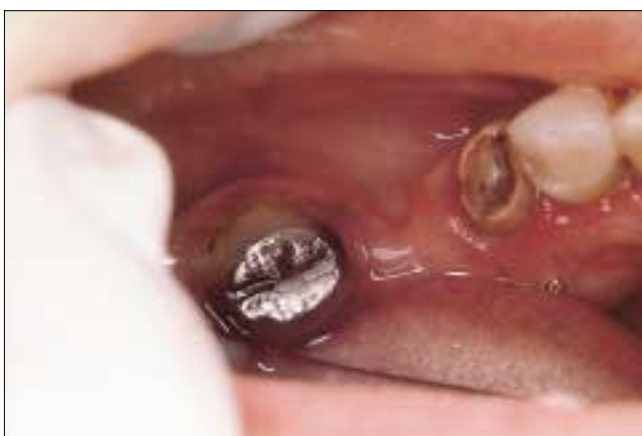

Figure 11: A posterior porcelain-fused-to metal fixed partial denture dislodged in this case due to recurrent caries in the mesial abutment.

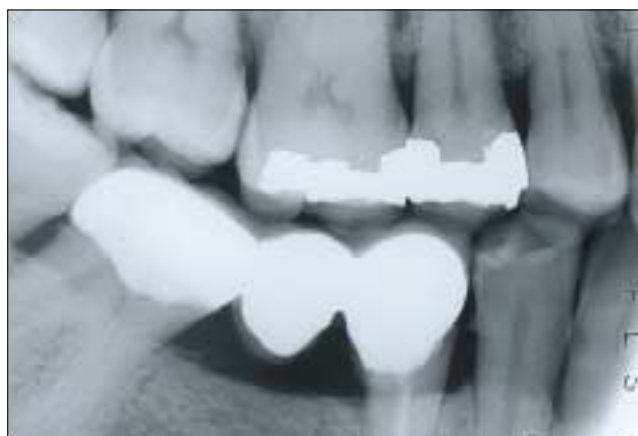

Figure 12: Radiographic image of the fixed partial denture just over 7 years after initial recementation with a dentin-bonded resin cement. The recementation helped to maintain the integrity of the dental arch over the years and preserved the abutment teeth from caries.

been under-prepared for the porcelain-fused-to-metal retainer. The mesial abutment had endodontic therapy, but the core material dislodged because of recurrent caries (Fig. 11). The initial cementing medium was of the non-polymeric type and had washed out totally on the mesial retainer. The patient was told that she needed a new prosthesis made after the premolar abutment was rebuilt with a post-and-core restoration and the preparation of the distal abutment was modified to create sufficient room for the porcelain-fused-to-metal retainer and to optimize parallelism of the walls.

Due to financial constraints, the patient was unable to afford the recommended treatment and requested that the existing prosthesis be cemented back in place. This was done using zinc phosphate cement, but the patient was warned about the unreliability of this procedure. One week later the patient informed the office of the author that the prosthesis had dislodged. A second attempt at recementation with zinc phosphate cement lasted another 2 weeks. After failure of the second attempt, a different approach was taken. The fitted surface of the prosthesis was cleaned of cement debris and microetched with a microetcher. The dentin surfaces of the abutment teeth were cleaned with a slurry of pumice in a rubber cup. They were then etched with an acid etchant gel and primed with a primer (All-Bond 2, Bisco Inc., Itasca, IL). A chemical-cure resin cement (All-Bond Crown and Bridge Cement, Bisco Inc., Itasca, IL) was dispensed and mixed according to the manufacturer's instructions. The retainers were loaded with the mixed cement, and the prosthesis was placed in position. Excess cement was removed and the occlusion was checked before the patient was dismissed. Following this alternative cementation method, the fixed partial denture remained cemented in position for 2 years and 8 months. When it dislodged after this period, it was recemented using a similar bonding procedure; however, this time the mesial abutment was first restored with a resin composite material in such a way that it did not interfere with the seating of the prosthesis and a different bonding system was used (Bond-It/Cement-It, Synca – Jeneric Pentron, Wallingford, CT). This second cementing procedure took place over 4 years ago. **Figure 12** shows a radiographic image of this bridge just over 7 years after original recementation with bonded resin cement.

Discussion

According to Tylman, the angle of convergence for ideal crown and fixed partial denture preparation should be between 2 and 5 degrees.⁵ Clinically, however, this ideal taper is seldom achieved. In one study, the mean angle of convergence of crown preparations made by final-year dental students was reported to be of the order of 21 degrees.⁶ In another study, the mean angle of convergence of crown preparations made by general dental practitioners and by specialists was reported to be 20 degrees.⁷ Some of the preparations in the cases discussed above either had angles of convergence significantly exceeding these numbers or were too short. Therefore, failure was inevitable when a conventional cement was used. Microetching of the fitted surface of the crown/retainer, whether it is made of a metal alloy or of a ceramic material, provides microscopic roughness of the surface and thus enhances bonding with the resin cement. On the other side of the interface, acid etching of the dentin removes the smear layer, opens the dentinal tubules and renders the intertubular dentin

rough due to selective demineralization of the inorganic substance. This enhances the condition for infiltration of the etched surface with the primer resin leading to the formation of the so-called hybrid layer. The formed hybrid layer bonds chemically with the resin cement. Such bonding can be so effective that in vitro separation of bonded crowns is frequently associated with cohesive dentin fracture.² Thus, in case 4, when the dislodged fixed partial denture was recemented with zinc phosphate cement, it dislodged after only one week in service, but when cementation was repeated with a bonded resin cement, the fixed partial denture remained in place for more than 2 and a half years (first time) and more than 4 years (second time) in spite of the unresolved problems of the supporting structure. Although this would not have been the ideal treatment option under normal conditions, it was, nevertheless, useful in maintaining the integrity of the dental arch until the financial position of the patient improved.

The bonded procedure was very useful in cases 1 and 2 and resulted in overcoming preparation design errors that could be corrected only when a replacement prosthesis was made. The procedure was convenient and less expensive for the patients, who appreciated the alternative cementing method. However, in case 3, rebuilding and reparing the molar tooth resulted in improvements in both the height and the angle of convergence of the preparation, which would normally enhance the potential for retention significantly. The use of a bonded resin cement acted as an adjunct to retention rather than being the primary provider for retention in this case. Surgical intervention for clinical crown lengthening was avoided, which was very much appreciated by the patient, who was apprehensive about the surgery.

It must be stressed that when the basic principles of retention, angle of convergence and height are followed accurately, non-polymeric cements have always worked well without the need for added retention through bonding. However, in situations where the retention is compromised for one reason or another, the use of an appropriate resin cementing medium in conjunction with a reliable bonding procedure can help overcome retention problems. It can also be very useful in salvaging existing prostheses until the patient is ready to have a replacement made.

Unlike non-polymeric cements, resin cements are typically expensive, and some products have a shorter shelf life. Some commercially available resin cements are more technique-sensitive than others, and in inexperienced hands their use can lead to undesirable results. Dentists must make an informed decision about selecting a resin cement/bonding system to use in their office based on evidence published in peer-reviewed periodicals. Great care must be taken when using these products, and the manufacturers' instructions must be followed meticulously. Careful use will help dentists to avoid such commonly encountered problems as premature setting of the cement before complete seating of the prosthesis and post-operative sensitivity. In addition, incomplete setting of the cement may occur if a dual-cure resin cement with a weak chemical-curing component is used under metallic restorations.^{3,4}

Conclusions

Resin cements used in conjunction with dentin bonding agents have led to the development of new alternative treatment modalities that could never be achieved with conventional cements.

Nonetheless, their use for routine dental work where retention is not compromised is not recommended. Excessive attachment might make it impossible to remove crowns and fixed partial dentures should this become necessary in the future without damaging the underlying supporting structure. Glass ionomer cements are less technique-sensitive in their use than are resin cements and perform well with routine crown and fixed partial denture work. The use of carefully selected resin cements in conjunction with reliable bonding agents can help to salvage dislodged crowns and fixed partial dentures when lack of retention is due to faulty preparation designs, and can help patients maintain their original prosthesis until they are ready to receive a replacement. ➤

Le Dr El-Mowafy est professeur agrégé de dentisterie restauratrice, Faculté de médecine dentaire, Université de Toronto.

*Écrire au : Dr Omar El-Mowafy, Université de Toronto, 124, rue Edward, Toronto, ON M5G 1G6. Courriel : oel.mowafy@utoronto.ca.
L'auteur n'a aucun intérêt financier déclaré.*

Références

1. El-Mowafy OM, Milenkovic M. Retention of paraposts cemented with dentin-bonded resin cements. *Oper Dent* 1994; 19(5):176-82.
2. El-Mowafy OM, Fenton AH, Forrester N, Milenkovic M. Retention of metal ceramic crowns cemented with resin cements: effects of preparation taper and height. *J Prosthet Dent* 1996; 76(5):524-9.
3. El-Mowafy OM, Rubo MH. Influence of composite inlay/onlay thickness on hardening of dual-cured resin cements. *J Can Dent Assoc (Online)* 2000; 66(3):147. Disponible au URL: www.cda-adc.ca/jcda/vol-66/issue-3/147.html.
4. El-Mowafy OM, Rubo MH, El-Badrawy WA. Hardening of new resin cements cured through ceramic inlay. *Oper Dent* 1999; 24(1):38-44.
5. Tylman SD. Relationship of structural design of dental bridges and their supporting tissues. *Int Dent J* 1963; 13:303-17.
6. Ohm E, Silness J. The convergence angle in teeth prepared for artificial crowns. *J Oral Rehabil* 1978; 5(4):371-5.
7. Nordlander J, Weir D, Stoffer W, Ochi S. The taper of clinical preparations for fixed prosthodontics. *J Prosthet Dent* 1988; 60(2):148-51.