

# Ameloblastic Carcinoma: Case Report and Literature Review

- Sylvie Louise Avon, DMD, MSc •
- John McComb, DDS, MSc, FRCD(C) •
- Cameron Clokie, DDS, PhD, FRCD(C) •

## A b s t r a c t

*Ameloblastic carcinoma is a rare malignant lesion with characteristic histologic features and behaviour that dictates a more aggressive surgical approach than that of a simple ameloblastoma. However, reliable evidence of its biologic activity is currently unavailable due to the scarcity of well-documented cases. It occurs primarily in the mandible in a wide range of age groups; no sex or race predilection has been noted. It may present as a cystic lesion with benign clinical features or as a large tissue mass with ulceration, significant bone resorption and tooth mobility. Because the lesion is usually found unexpectedly after an incisional biopsy or the removal of a cyst, a guide to differential diagnosis is not usually useful. The identifying features of ameloblastic carcinoma must be known and recognized by dental practitioners. Our understanding of the histologic features of ameloblastic carcinoma is somewhat vague. The tumour cells resemble the cells seen in ameloblastoma, but they show cytologic atypia. Moreover, they lack the characteristic arrangement seen in ameloblastoma. The clinical course of ameloblastic carcinoma is typically aggressive, with extensive local destruction. Direct extension of the tumour, lymph node involvement and metastasis to various sites (frequently the lung) have been reported. Wide local excision is the treatment of choice. Regional lymph node dissection should be considered and performed selectively. Radiotherapy and chemotherapy seem to be of limited value for the treatment of ameloblastic carcinomas. At the moment, there are too few reported cases to make a definite recommendation regarding treatment. Close periodic reassessment of the patient is mandatory.*

**MeSH Key Words:** ameloblastoma/pathology; carcinoma/pathology; case report

© J Can Dent Assoc 2003; 69(9):573-6  
This article has been peer reviewed.

The ameloblastoma is an odontogenic tumour of the jaws, arising from dental embryonic remnants possibly from the epithelial lining of an odontogenic cyst; dental lamina or enamel organ; stratified squamous epithelium of the oral cavity; or displaced epithelial remnants. The lesion comprises about 1% of all cysts and tumours occurring in the jaws, making it the most common, clinically significant odontogenic tumour. This neoplasm is generally recognized as a locally invasive tumour that demonstrates considerable tendency to recur, but rarely behaves aggressively or shows metastatic dissemination.<sup>1</sup>

The question of malignancy in ameloblastoma has been the subject of considerable discussion and controversy for many years. There can be little argument that an ameloblastoma that metastasizes is malignant, even if the tumour

shows benign histologic features. In other instances, ameloblastomas have been considered to be malignant on the basis of an aggressive clinical course in the absence of metastasis. These lesions often show unusual or atypical histologic features.<sup>2</sup> Carcinomas derived from ameloblastomas have been designated by a variety of terms, including malignant ameloblastoma,<sup>3-5</sup> ameloblastic carcinoma,<sup>6</sup> metastatic ameloblastoma<sup>7</sup> and primary intra-alveolar epidermoid carcinoma.<sup>8</sup>

In 1971, the World Health Organization (WHO)<sup>9</sup> published its classification of odontogenic carcinomas recognizing the following subtypes:

- malignant ameloblastoma
- primary intraosseous carcinoma
- other carcinomas arising from odontogenic epithelium, including those arising from odontogenic cysts.

In this classification, “malignant ameloblastoma” refers to a neoplasm in which typical histologic features of ameloblastoma are seen in the primary tumour located in the jaw as well as in any associated metastatic deposits. “Primary intraosseous carcinoma” (PIOC) refers to a primary carcinoma of the jaw not having features of ameloblastoma and not arising from an odontogenic cyst. The “other carcinomas” category refers to carcinomas arising from odontogenic epithelium, including those arising from odontogenic cysts.<sup>9</sup>

In 1982, Elzay<sup>10</sup> argued that the WHO classification does not make provision for separating tumours that are histologically identical to classic ameloblastoma and metastasize from ameloblastoma-like lesions that are histologically malignant before metastasizing. He proposed a modification of the classification in which all primary intraosseous carcinomas that do not involve the salivary glands would be classified as PIOC, which would then be subclassified as follows:

- Type 1: arising from an odontogenic cyst
- Type 2: arising from an ameloblastoma
  - a. well differentiated (malignant ameloblastoma)
  - b. poorly differentiated (ameloblastic carcinoma)
- Type 3: arising *de novo*
  - a. nonkeratinizing
  - b. keratinizing.

In 1984, Slootweg and Müller<sup>7</sup> further emphasized that ameloblastomas may exhibit malignant features other than metastasis and suggested a modified classification system for malignant tumours with features of ameloblastoma, based on characteristics of malignancy:

- Type 1: PIOC ex odontogenic cyst
- Type 2:
  - a. malignant ameloblastoma
  - b. ameloblastic carcinoma, arising *de novo*, ex ameloblastoma or ex odontogenic cyst
- Type 3: PIOC arising *de novo*
  - a. nonkeratinizing
  - b. keratinizing.

Elzay,<sup>10</sup> Slootweg and Müller<sup>7</sup> use the term ameloblastic carcinoma to convey the presence of cytologic features of malignancy. The degree of differentiation in epithelial neoplasms is usually considered to be significant in predicting biologic behaviour of metastasis. The main difference between Elzay’s and Slootweg and Müller’s schemes relates to the minor point of histogenesis.<sup>2</sup> According to these authors, the term ameloblastic carcinoma should be used to designate lesions that exhibit histologic features of both ameloblastoma and carcinoma.<sup>7,10,11</sup> The tumour may metastasize and histologic features of malignancy may be found in either the primary tumour, the metastases or

both.<sup>7,11,12</sup> The term malignant ameloblastoma should be confined to those ameloblastomas that metastasize despite an apparently typical benign histology in both the primary and the metastatic lesions.<sup>3–5,7,11,13</sup> The incidence of ameloblastic carcinoma is greater than that of malignant ameloblastoma by a 2:1 ratio.<sup>2</sup>

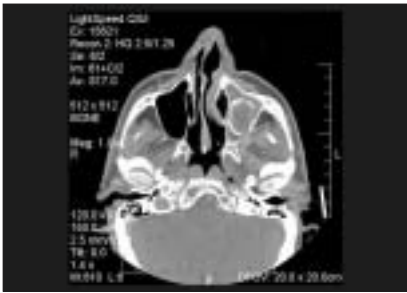### Case Report

A 68-year-old man presented to the Oral and Maxillofacial Surgery Clinic at Toronto General Hospital complaining of a persistent hole in his left posterior maxilla following the extraction of the left maxillary third molar. Clinical examination revealed a persistent oro-antral communication that appeared to be trapping food and, as a result, was secondarily infected. Plain radiographic imaging and axial computed tomography (CT) scans were carried out, revealing an oval corticated lucency occupying a large portion of the left maxillary sinus (Fig. 1). The radiographic report suggested that the sinus was filled with soft tissue, probably representing inflamed sinus membrane or mucus. There was also indication of hypertrophy of the nasal mucosa of the left nasal fossa and deviation to the right side of the maxilla. The alveolar crest in the area of the left maxillary tuberosity was destroyed, and there was some evidence of lateral expansion. Air in the soft tissue sinus was also noted.

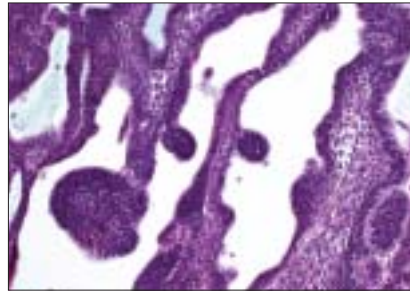
Based on these findings, the diagnosis was a cystic lesion involving the maxillary sinus. The area was surgically excised under local anesthesia. The cavity in the sinus appeared to be well demarcated and was thoroughly curetted at the time of surgery. On gross examination, the tissue within the sinus appeared to be a mucoid material within a central cavity.

Microscopic examination showed an epithelial tumour consisting of a delicately trabecular and plexiform arrangement intermixed with solid epithelial sheets and islands. The stroma contained very pale-staining fibrous connective tissue. In areas, the epithelium had a columnar basal cell configuration bounding a stellate reticulum-like interior that is characteristic of ameloblastoma (Fig. 2). Closer examination of the solid areas revealed cellular variation and variability of nuclear staining from dark to lighter and vesicular, some nuclei with prominent nucleoli. There was some pleomorphism. Numerous apoptotic cells were seen. Although not plentiful, mitoses were found with relative ease at high power (Fig. 3). The specimen also incorporated fragments of vital bone and was in contact with oral surface epithelium. Some of the architecture was that of an ameloblastoma, but the cytology of other areas warranted the designation of ameloblastic carcinoma.

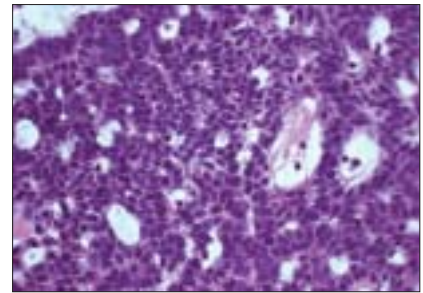
The area was re-examined using both axial and coronal CT scans. This approach revealed a well-circumscribed, predominantly cystic mass in the floor of the left maxillary



**Figure 1:** Computed tomography revealed the presence of a large, oval, partly corticated soft tissue mass occupying a large portion of the left maxillary sinus.



**Figure 2:** Microscopic examination shows the epithelial tumour consisting of strands of epithelial cells in a fibrous connective tissue stroma. The epithelium has a peripheral columnar basal cell configuration bounding a stellate reticulum-like epithelium that is characteristic of ameloblastoma (hematoxylin and eosin stain; magnification  $\times 40$ ).



**Figure 3:** Cellular pleomorphism, apoptotic cells and mitotic figures were found with relative ease at high power (hematoxylin and eosin stain; magnification  $\times 100$ ).

sinus. A small focus of air was apparent in the centre of the lesion. The patient was scheduled for more definitive surgery that included a left posterior maxillectomy and reconstruction with a vascularized free forearm flap. The patient was followed every 3 months. After 2 years follow-up, there was no clinical or radiologic sign of recurrence.

## Discussion

In 1983, Shafer<sup>6</sup> introduced the term ameloblastic carcinoma to describe ameloblastomas in which there had been histologic malignant transformation. Ameloblastic carcinoma occurs in a wide range of age groups, but the mean age of 30.1 years is in agreement with that reported for ameloblastomas.<sup>11</sup> There is no apparent sex predilection.<sup>11</sup> The most commonly involved area is the posterior portion of the mandible.<sup>11</sup> Involvement of the maxilla by ameloblastic carcinoma seems to be less frequent than that of the mandible.<sup>7,11,14-17</sup> The most common sign described has been swelling, although others include associated pain, rapid growth, trismus and dysphonia.<sup>11</sup>

In our case study, the radiographic appearance of the lesion was consistent with that of an ameloblastoma except for the presence of some focal radiopacities, apparently reflecting dystrophic calcifications. These histologic and radiologic features are not generally seen in conventional ameloblastomas. Clinically, these carcinomas are more aggressive than most typical ameloblastomas. Perforation of the cortical plate, extension into surrounding soft tissue, numerous recurrent lesions and metastasis, usually to cervical lymph nodes, can be associated with ameloblastic carcinomas.<sup>11</sup>

The characterization of carcinoma arising centrally within the mandible and the maxilla is an uncommon but complex problem. The first step in the staging process must be the exclusion of metastasis or invasion of bone by tumour from adjacent soft tissue or paranasal sinus. The neoplasm may be derived from a number of different

sources, such as those of odontogenic origin, including ameloblastoma, odontogenic cysts or epithelial odontogenic rests, as well as entrapped salivary gland epithelium or epithelium entrapped along embryonic fusion sites.<sup>11</sup> Carcinomas in the jaws metastasizing from primary locations such as the lung, the breast and the gastrointestinal tract may mimic ameloblastic carcinoma and must always be ruled out clinically before that diagnosis is made.<sup>11,18</sup>

Primary intra-alveolar epidermoid carcinoma must be considered in the differential diagnosis of ameloblastic carcinoma. This tumour, developing within bone, probably originates from odontogenic epithelial remnants.<sup>11</sup> According to Shear,<sup>8</sup> these lesions occur over a wide age range, but most occur in the sixth to seventh decade of life. Ninety percent occur in the mandible, and they are seen twice as often in male patients as in female patients. Although the primary intra-alveolar carcinoma and the ameloblastic carcinoma exhibit some clinical differences, their histologic features are similar enough to suggest a histogenetic relation. It is possible, then, that the primary intra-alveolar carcinoma may represent simply a less-differentiated, usually nonkeratinizing form of ameloblastic carcinoma, both lesions being derived from odontogenic remnants.<sup>11</sup>

Two types of typical ameloblastoma must also be considered in the differential diagnosis of ameloblastic carcinoma. The acanthomatous ameloblastoma exhibits varying degrees of squamous metaplasia and even keratinization of the stellate reticulum portion of the tumour islands; however, peripheral palisading is maintained and no cytologic features of malignancy are found.<sup>11,18</sup> The so-called kerato-ameloblastoma is a rare variant of ameloblastoma that contains prominent keratinizing cysts that may cause some alarm and distract the pathologist from the otherwise ameloblastomatous feature.<sup>11</sup>

An additional consideration in the differential diagnosis is the squamous cell carcinoma arising in the lining of an odontogenic cyst.<sup>18,19</sup> Histologically, this lesion tends to more closely resemble oral squamous cell carcinoma than what we have described for ameloblastic carcinoma. However, it is of interest that ameloblastic carcinoma can apparently arise from a cystic lining.<sup>11</sup>

The squamous odontogenic tumour may also be mistaken for ameloblastic carcinoma.<sup>20</sup> It is composed of islands of squamous epithelium that lack stellate reticulum-like zones and peripheral palisading. In addition, microcystic changes and dystrophic calcifications are occasionally seen in this lesion. However, the epithelium of the squamous odontogenic tumour lacks any cytologic evidence of malignant disease.<sup>11</sup>

Thus, the term ameloblastic carcinoma can be applied to our case, which showed focal histologic evidence of malignant disease including cytologic atypia and mitoses with indisputable features of classic ameloblastoma.

Whether ameloblastoma may transform biologically and histologically from a classic ameloblastoma to a malignant lesion is controversial. Although various authors have shown that metastasizing ameloblastomas are histologically indistinguishable from classic ameloblastomas, others have identified unequivocal malignant features in the recurrent or metastatic tumour, usually many years after repeated surgical excisions.<sup>4,17</sup> It has been suggested that the high rate of recurrence is due to its mode of growth and surgical mismanagement rather than any inherent malignant properties and metastases are "exceedingly rare."<sup>11</sup>

The lesion that we have described as ameloblastic carcinoma falls into a completely different category. This lesion exhibits histologic evidence of malignancy, regardless of whether it has metastasized. We have had no report of metastasis in the case presented in this publication, although we must bear in mind the possibility that this may yet occur. Unfortunately, it is not possible to differentiate clearly between ameloblastic carcinoma and malignant ameloblastomas reported in the literature on a retrospective basis. Nevertheless, it is important that, in the future, these lesions be accurately identified, differentiated from malignant ameloblastoma and followed so that their natural history and prognosis can be further defined.<sup>11</sup>

## Conclusion

It is reasonable to assume that this case illustrates the malignant portion in the spectrum of ameloblastomas. It is possible that ameloblastoma shows a variety of histologic and biologic behaviours ranging from benignity to frank malignancy. Cases of ameloblastoma should thus be studied carefully, correlating their histologic pattern with biologic behaviour to detect subtle changes in histology that may predict aggressive behaviour.

What therapeutic assessments should be considered in cases like these? When the diagnosis of an ameloblastic carcinoma is made, an assessment of nodal metastasis and evidence of distant metastasis is required. A staged work-up consisting of a neck examination, a CT scan of the area and a chest radiograph becomes necessary. The treatment of ameloblastic carcinoma is controversial, but the recommended surgical treatment usually requires jaw resection with 2- to 3-cm bony margins and consideration of contiguous neck dissection, both prophylactic and therapeutic.<sup>21</sup> Documented case reports with meaningful follow-up are rare. Meticulous follow-up is essential because recurrence and metastasis in the lung and regional lymph nodes have been reported.<sup>7,11,17,22</sup> Presurgical radiation therapy has been suggested to decrease tumour size,<sup>16</sup> but chemotherapy is as yet unproven.<sup>22</sup> Reconstruction of the post-resection defect may proceed as one would normally expect following any head or neck carcinoma resection. Sufficient time should be allotted before reconstruction because of potential tumour recurrence. ♦

*Dr. Avon is a specialist in oral pathology and oral medicine, faculty of dentistry, Laval University, Ste-Foy, Quebec.*

*Dr. McComb is head, oral pathology and oral medicine, faculty of dentistry, University of Toronto, Toronto, Ontario.*

*Dr. Clokie is head, oral and maxillofacial surgery, faculty of dentistry, University of Toronto, Toronto, Ontario.*

*Correspondence to: Dr. Sylvie Louise Avon, Faculty of Dentistry, Laval University, Cité universitaire, Ste-Foy, QC G1K 7P4. E-mail: sylvie-louise.avon@fmd.ulaval.ca.*

*The authors have no declared financial interests.*

## References

- Neville BW, Damm DD, Allen CM, Bouquot JE, editors. Oral and maxillofacial pathology. 2nd ed. Philadelphia: WB Saunders Co.; 2002. p. 611–9.
- Regezi JA, Kerr DA, Courtney RM. Odontogenic tumors: analysis of 706 cases. *J Oral Surg* 1978; 36(10):771–8.
- Carr RF, Halperin V. Malignant ameloblastomas from 1953 to 1966. Review of the literature and report of a case. *Oral Surg Oral Med Oral Pathol* 1968; 26(4):514–22.
- Sugimura M, Yamauchi T, Yashikawa K, Takeda N, Sakita M, Miyazaki T. Malignant ameloblastoma with metastasis to the lumbar vertebra: report of case. *J Oral Surg* 1969; 27(5):350–7.
- Herceg SJ, Harding RL. Malignant ameloblastoma with pulmonary metastases. Report of a case and review of the literature. *Plast Reconstr Surg* 1972; 49(4):456–60.
- Shafer WG, Hine MK, Levy BM, editors. A textbook of oral pathology. 4th ed. Philadelphia: WB Saunders Co.; 1983. p. 280–1.
- Slootweg PJ, Müller H. Malignant ameloblastoma or ameloblastic carcinoma. *Oral Surg Oral Med Oral Pathol* 1984; 57(2):168–76.
- Shear M. Primary intra-alveolar epidermoid carcinoma of the jaw. *J Pathol* 1969; 97(4):645–51.
- Pindborg JJ, Kramer IR, Torloni H, editors. Histological typing of odontogenic tumours, jaw cysts, and allied lesions. International Histological Classification of Tumours. World Health Organization (book 5). Geneva; 1971. p. 24–28.
- Elzay RP. Primary intraosseous carcinoma of the jaws. Review and update of odontogenic carcinomas. *Oral Surg Oral Med Oral Pathol* 1982; 54(3):299–303.



11. Corio LR, Goldblatt LI, Edwards PA, Hartman KS. Ameloblastic carcinoma: a clinicopathologic study and assessment of eight cases. *Oral Surg Oral Med Oral Pathol* 1987; 64(5):570–6.
12. Lau SK, Tideman H, Wu PC. Ameloblastic carcinoma of the jaws. A report of two cases. *Oral Surg Oral Med Oral Pathol Oral Radiol Endod* 1998; 85(1):78–81.
13. Nagai N, Takeshita N, Nagatsuka H, Inoue M, Nishijima K, Nojima T, and others. Ameloblastic carcinoma: case report and review. *J Oral Pathol Med* 1991; 20(9):460–3.
14. Lee L, Maxymiw WG, Wood RE. Ameloblastic carcinoma of the maxilla metastatic to the mandible. Case report. *J Craniomaxillofac Surg* 1990; 18(6):247–50.
15. McClatchey KD, Sullivan MJ, Paugh DR. Peripheral ameloblastic carcinoma: a case report of a rare neoplasm. *J Otolaryngol* 1989; 18(3):109–11.
16. Andersen E, Bang G. Ameloblastic carcinoma of the maxilla. A case report. *J Maxillofac Surg* 1986; 14(6):338–40.
17. Daramola JO, Abioye AA, Ajagbe HA, Aghadiuno PU. Maxillary malignant ameloblastoma with intraorbital extension: report of case. *J Oral Surg* 1980; 38(3):203–6.
18. Gandy SR, Keller EE, Unni KK. Ameloblastic carcinoma: report of two cases. *J Oral Maxillofac Surg* 1992; 50(10):1097–102.
19. Gardner AF. The odontogenic cyst as a potential carcinoma: a clinicopathology appraisal. *J Am Dent Assoc* 1969; 78(4):746–55.
20. Pullon PA, Shafer WG, Elzay RP, Kerr DA, Corio RL. Squamous odontogenic tumor. Report of six cases of a previously undescribed lesion. *Oral Surg Oral Med Oral Pathol* 1975; 40(5):616–30.
21. Marx RE, Stern D, editors. Oral and maxillofacial pathology. A rationale for diagnosis and treatment. Illinois: Quintessence Publishing Co, Inc.; 2003. p. 657.
22. Bruce RA, Jackson IT. Ameloblastic carcinoma. Report of an aggressive case and review of the literature. *J Craniomaxillofac Surg* 1991; 19(6):267–71.