

The "Point of Care" section answers everyday clinical questions by providing practical information that aims to be useful at the point of patient care. The responses reflect the opinions of the contributors and do not purport to set forth standards of care or clinical practice guidelines. Readers are encouraged to do more reading on the topics covered. If you would like to contribute to this section, please contact editor-in-chief Dr. John O'Keefe at jokeefe@cda-adc.ca.

QUESTION 1

Why is my patient experiencing persistent pain after a denture adjustment?

Background

Patients may experience persistent pain after their dentures have been adjusted for many reasons, and occlusion is a factor that tends to be overlooked. The best way to address problems of occlusion is to remount the dentures and analyze occlusion and articulation. There may be interference at the position of habitual closure if it differs from a centric relation (retrognathic patients). It may be necessary to remount the denture at the habitual closing position to eliminate the problem.

Other causes of pain include bruxism, inadequate vertical dimension of occlusion, sharp ridges or poor ridge form, nutritional deficiency or reduced tissue tolerance due to systemic diseases and xerostomia. Treatment will depend on the etiology.

Management of the Problem

Clenching and Bruxism

The presence of shiny wear facets on teeth in a recently delivered denture raise the suspicion of bruxism. It is imperative to review the patient's medical and dental history and make the patient aware of this problem. Stretching and relaxation exercises may be recommended. Patients should

also be advised to remove their denture at night or wear a soft mouthguard over the denture.

Inadequate Interocclusal Distance

Examining rest position and using phonetics can help determine whether the vertical dimension of the denture encroaches on the interocclusal distance. If this occurs, the dentures must be remounted and repositioned (**Figs. 1 and 2**) or equilibrated to restore adequate interocclusal space. The patient should be seen again after 48 hours.

Sharp Ridges or Poor Ridge Form

These factors should be assessed during the initial visit and the patient should be advised of potential discomfort. Resilient denture liner may reduce trauma to mucosa compressed between the underlying bone spicules and a hard denture base. If symptoms persist after placement of the soft liner, bone recontouring, alveoloplasty or placement of dental implants may be required.

Low Tissue Tolerance Due to Nutritional Deficiencies

A dietary analysis should be carried out to assess if the patient might have a diet low in protein or vitamin B12. Treatment consists of dietary coun-

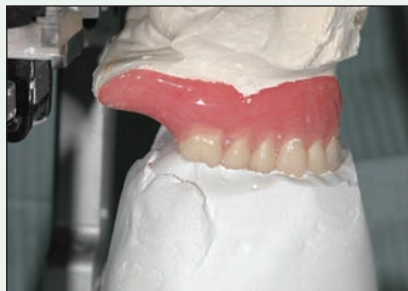

Figure 1: The maxillary denture is remounted using the remount index sent by the laboratory.

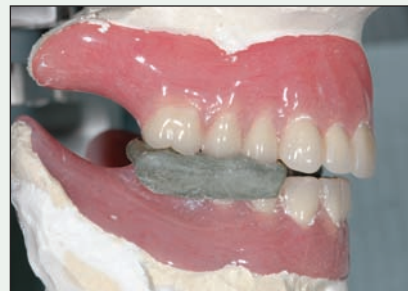

Figure 2: The mandibular denture is remounted against the maxillary denture using the interocclusal record obtained in centric relation. The dentures are ready for occlusal adjustment.

selling and referring the patient to a nutritionist if the problem persists.

Low Tissue Tolerance Due to an Underlying Disease

Low tissue tolerance due to uncontrolled diabetes, pemphigus vulgaris or some other diseases may be the cause of pain. The patient should be referred to a physician for diagnosis and treatment.

Xerostomia

Lack of the antimicrobial and lubricating benefits of saliva will severely compromise tissue tolerance. If xerostomia is drug induced, the physician may be able to adjust the dose or change medications to reduce this side effect. An implant-supported prosthesis may be the solution for a xerostomic edentulous patient.

Dentists should be aware that in dealing with the geriatric population, especially edentulous patients, various factors may lengthen treatment

time. Taking a thorough medical and dental history during the initial consultation will reduce the number and length of follow-up visits in this frequently forgotten population. ♦

THE AUTHOR



Dr. Cecilia Aragon is assistant professor in the division of restorative dentistry, Schulich School of Medicine & Dentistry, The University of Western Ontario, London, Ontario. Email: cecilia.aragon@schulich.uwo.ca

Further Reading

Budtz-Jorgensen E. *Prosthodontics for the elderly: diagnosis and treatment*. Hanover Park, Ill.: Quintessence Publishing; 1999. p. 107–22.

Rhodus NL, Brown J. The association of xerostomia and inadequate intake in older adults. *J Am Diet Assoc* 1990; 90(12):1688–92.

Shigli K, Angadi GS, Hegde P. The effect of remount procedures on patient comfort for complete denture treatment. *J Prosthet Dent* 2008; 99(1):66–72.

Zarb GA, Bolender CL, Eckert S, Jacob R, Fenton A, Meriscke-Stern R. *Prosthodontic treatment for edentulous patients: complete dentures and implant-supported prostheses*. 12th ed. St. Louis: Mosby; 2004. p. 404–15.

QUESTION 2

What should I do if a police officer contacts me and requests the record of one of my patients?

Background

The use of dental records to help identify a presumed deceased person has become routine forensic practice in Canada. Nevertheless, for any dentist, the arrival of a police officer with a request for the release of a dental record is a rare event. When you release personal information for this purpose, you need to consider the following important factors.

Depending on the location of your practice, the local coroner or medical examiner initiates the request for a dental record after the recovery of a body whose identification by visual means, fingerprints or DNA may be problematic. The office of the coroner or medical examiner usually provides a written warrant for the release of a specifically named dental record. A police officer or, in some cases, a coroner's agent executes this warrant. Occasionally, instead of a warrant, the coroner or medical officer may give a verbal order. You can check whether this is the case by calling the coroner's or medical examiner's office.

In the case of a missing person, the police may wish to upload a dental record to one of a number of searchable databases of unidentified bodies. To do this, the police must first produce a general or search warrant obtained from a judge or justice of the peace. Because it is not a crime to go missing, the investigator must convince the issuer of the warrant that the missing person may be dead. You should not release dental records of missing persons without such a warrant.

Management of the Requested Dental Records

Because you do not know which part or parts of the person's body have been recovered, you should provide the entire original dental record, apart from the financial ledger. You should not provide only what you think is the critical component of the person's dental record. It is helpful to :

- include all correspondence
- mount, identify and date all radiographs (if your record contains copies of radiographs, note the right and left sides)

- add a glossary of terms or abbreviations, if you use unique notations
- include study models, lab prescriptions and photographs
- clearly identify treatment done since the last radiograph was made
- provide your contact information

You should keep a list of all the records that you release and make copies for your records. Have the police officer sign and time-stamp a receipt for all the information you provide.

The dental records you supply will be transported to a forensic dentist who will use them in confidence and only for the intended purpose. You do not need to call your regulatory authority, and you should never call the next of kin. You will not be reimbursed for supplying your records, but on occasion, you may be asked to appear in court to testify to their authenticity. Such a request rarely occurs in civil matters, but is more common in

criminal cases. In due course, the records will be returned to you.

It is not unusual for the police to ask for, or for the warrant to read, “provide the dental chart.” Providing only the odontogram is insufficient; you must provide the entire original dental record.

Providing dental records for personal identification can be of great social benefit. In most cases, dental identification can be completed quickly and is both exceedingly accurate and relatively inexpensive. Identification of a person by dental means is dependent on dentists’ timely and full cooperation in the release of their patients’ records. ❖

THE AUTHOR



Dr. Stan Kogon is professor in the division of oral medicine and radiology, Schulich School of Medicine & Dentistry, The University of Western Ontario, London, Ontario. Email: stan.kogon@schulich.uwo.ca

QUESTION 3

Can a regimented 3-month maintenance program be used as a definitive treatment for patients with periodontitis?

Background

Scaling and root planing (SRP), typically used in the initial or maintenance phase of periodontal treatment, is a mainstay of periodontal therapy. SRP is an efficacious treatment used to debride tooth surfaces of the pathogenic bacterial biofilms implicated in the onset and progression of periodontitis. However, conventionally desired outcomes for the treatment of periodontal disease, such as shallow probing depths, minimal inflammation and stable attachment levels, may not be predictably attained with SRP alone.

Clinicians should be aware of the limitations of SRP in achieving thorough subgingival debridement, particularly when probing depths are ≥ 5 mm.^{1,2} These limitations are more pronounced in areas exhibiting complex nonplanar anatomy, such as in root concavities and around multirooted teeth. Failure to remove all etiologic agents will not create conditions favouring healing of the dentogingival complex and will result in the proliferation of pathogenic biofilms and poten-

tially progressive loss of attachment (in one study,³ only 11% of sites with a probing depth > 5 mm reformed a junctional epithelium following SRP).

Indeed, other therapeutic options should be considered if SRP does not provide the desired outcomes, namely shallow probing depths and minimal inflammation. Although bleeding on probing (measure of inflammation) alone appears to be a poor predictor of future progression of periodontal disease, 50% or more of sites with residual probing depths of 5–6 mm combined with the presence of bleeding on probing following initial SRP therapy will worsen over a 3-year time span.⁴ Another study found that, compared with teeth that have probing depths ≤ 3 mm, those with residual probing depths of 5–6 mm have an odds ratio of 7.7–11.0 for tooth loss following 11 years of maintenance therapy.⁵ Therefore, some caution should be exercised before indiscriminately placing patients with residually deep probing depths and inflammation on prolonged 3-month maintenance without consideration of other treatment modalities.

Tailoring a Maintenance Schedule to the Patient

The importance of a periodontal diagnosis and re-evaluation of the results of initial treatment in formulating a treatment plan cannot be overstated. At the very least, dentists should conduct periodontal screening and recording or, ideally, full-mouth probing to derive a periodontal diagnosis before prescribing any treatment. Only following a diagnosis of plaque-induced gingival or periodontal disease and identification of any associated secondary etiologies (i.e., smoking, diabetes) can initial therapy of SRP be prescribed.

Unfortunately many dentists overlook the need to evaluate patient response to this initial therapy and may automatically place the patient on a defined recall or maintenance schedule. *A periodontal re-evaluation appointment should be conducted 4–6 weeks following initial therapy to assess the state of the periodontium, evaluate plaque control and decide on any further treatment.* If shallow probing depths (with or without inflammation) are present at re-evaluation, then consideration can be given to tailoring a maintenance schedule (3, 4, 6, 9 months) to the individual patient, depending on attending risk factors. In cases where a diagnosis of periodontitis was made and response to initial therapy was judged poor as manifested by residually deep probing depths (with or without inflammation), then consideration should be given to other treatment modalities

such as surgical intervention along with modification of any risk factors.

Patients injudiciously placed on long-term 3-month maintenance without consideration of other treatment modalities or surgical therapy may suffer progressive attachment loss, leading ultimately to tooth loss and compromise of their natural dentition. ♦

THE AUTHOR



Dr. Tarek El-Sayegh is assistant professor in the division of periodontics at the Schulich School of Medicine & Dentistry, The University of Western Ontario, London, Ontario. He also maintains a private periodontal practice in Waterloo, Ontario. Email: telsayeg@uwo.ca

References

1. Caffesse RG, Sweeney PL, Smith BA. Scaling and root planing with and without periodontal flap surgery. *J Clin Periodontol* 1986; 13(3):205–10.
2. Stambaugh RV, Dragoo M, Smith DM, Carasali L. The limits of subgingival scaling. *Int J Periodontics Restorative Dent* 1981; 1(5):30–41.
3. Waerhaug J. Healing of the dento-epithelial junction following subgingival plaque control. II: As observed on extracted teeth. *J Periodontol* 1978; 49(3):119–34.
4. Claffey N, Nylund K, Kiger R, Garrett S, Egelberg J. Diagnostic predictability of scores of plaque, bleeding, suppuration and probing depth for probing attachment loss. 3 1/2 years of observation following initial periodontal therapy. *J Clin Periodontol* 1990; 17(2):108–14.
5. Matuliene G, Pjetursson BE, Salvi GE, Schmidlin K, Bragger U, Zwahlen M, and other. Influence of residual pockets on progression of periodontitis and tooth loss: results after 11 years of maintenance. *J Clin Periodontol* 2008; 35(8):685–95.

QUESTION 4

What do I do about a patient who requires extractions and is taking the anticoagulant warfarin?

Background

When a patient who takes warfarin needs an extraction, the key consideration is the balance between the complexity of the procedure and the risk of bleeding, and the risk of reversing anticoagulation.

The purpose of warfarin therapy is to prevent life-threatening clots forming in target organs such as the brain. A patient may be taking warfarin for a number of conditions (**Box 1**).

The degree of anticoagulation your patient needs is measured by the prothrombin time, expressed as the international normalized ratio

Box 1 Conditions treated with warfarin

- atrial fibrillation
- deep venous thrombosis
- pulmonary embolus
- stroke
- artificial heart valve

(INR). An INR of 1 is normal, therapeutic levels for preventing stroke in those with atrial fibrillation is typically between 2.0 and 3.0, and the target value for patients with an artificial heart valve is between

2.5 and 3.5. Although reversing anticoagulation by discontinuing warfarin will improve your patient's surgical hemostasis, such reversals may precipitate a life-threatening blood clot.

Management of Patients Taking an Anticoagulant

The primary objective of managing a patient taking warfarin is first and foremost to avoid catastrophic thromboembolic events while providing optimal dental treatment. You should always consider using less invasive procedures whenever possible, for example, offering endodontics rather than extraction or extracting fewer teeth at a time, if that is reasonable.

Most minimally invasive dental procedures such as restorations can be done without altering the level of a patient's anticoagulation; however, surgical procedures require special consideration. Specifically, the amount of bleeding anticipated is very important. Most single, uncomplicated extractions can be managed with local measures, even when a patient has an INR of up to 3.5. Local measures include suturing, and using electrocautery, packing with an absorbable gelatine sponge, and pressure dressings such as surgical splints.

More complex procedures such as multiple extractions, impactions and periodontal surgery such as gingivectomy involve larger surgical wounds that have increased surface area and create greater difficulty with hemostasis. Further complicating the situation is acute or chronic inflammation with resulting hyperemia caused by vasodilatation. In such situations, temporarily lowering a patient's INR may be beneficial. Under these circumstances, the patient's INR need not be returned to a normal value of 1.0. Instead, reducing the dose of warfarin and confirming an INR of about 2.0, in combination with local measures, is typically adequate. In all such situations, consultation and coordination with the patient's treating physician are required to avoid catastrophic medical complications such as stroke or pulmonary embolus.

Given the relatively long half-life of warfarin, dose reduction is usually started 3 or 4 days before the surgery; the patient's INR is measured in the morning before the surgery. Typically, the normal dose of warfarin is restarted after the procedure on the day of surgery and the patient is carefully monitored for bleeding. These actions should pro-

vide a window of 1 or 2 days of improved coagulation to meet the needs of surgical hemostasis.

Special consideration needs to be taken for patients who have a particularly high risk for thromboembolic events, such as those who have artificial heart valves or those who have had a stroke after discontinuation of prophylactic anticoagulation. In these circumstances, bridging anticoagulation should be considered. This technique involves using subcutaneous heparin to maintain full anticoagulation while reducing the dose of warfarin and the INR falls. The effect of the heparin is monitored with the patient's partial thromboplastin time. About 4 to 6 hours before the surgery, the heparin is discontinued, which, because of its short half-life, briefly reverses anticoagulation. Once hemostasis is obtained, warfarin is restarted. Although this technique involves a greater risk of postsurgical bleeding, this risk is balanced against the decreased risk of catastrophic thromboembolic events. Given the higher medical and surgical risks involved, consultation with the patient's treating physician is again necessary to coordinate this procedure.

What is the bottom line then? You need to balance the risk of bleeding during the procedure against the degree of anticoagulation, and to coordinate any alteration in anticoagulation in consultation with the patient's treating physician. ♦

THE AUTHOR



Dr. Henry Lapointe is associate professor in and chair of the division of oral and maxillofacial surgery and assistant director of post-graduate studies, Schulich School of Medicine & Dentistry, The University of Western Ontario, London, Ontario. Email: henry.lapointe@schulich.uwo.ca

Further Reading

Israels S, Schwetz N, Boyar R, McNicol A. Bleeding disorders: characterization, dental considerations and management. *J Can Dent Assoc* 2006; 72(9):827. Available: www.cda-adc.ca/jcda/vol-72/issue-9/827.pdf.

Little JW, Falace DA, Miller CS, Rhodus NL. Bleeding disorders. In: *Dental management of the medically compromised patient*. St. Louis (MO): Mosby; 2002. p. 332–64.

QUESTION 5

My patient who has a unilateral cleft lip would like cosmetic dentistry to improve her smile. However, the cleft lip is quite obvious. What treatment options does she have to improve the appearance of her lip?

Background

Poor esthetics of the repaired cleft lip, like your patient's, are usually due to a number of factors. Geometric, rather than anatomic, lip-incision designs to repair the primary lip result in a less than ideal lip. More importantly, inadequate and inaccurate primary repair of the muscles of the cleft lip results in dysfunctional lip movements in conversation that are noticeable and unesthetic. The lack of physiologic functional repair of the cleft lip leads to abnormalities in facial growth and results in dentofacial deformities that magnify the problem. Ideally, primary repair of the cleft lip should focus on muscle reconstruction that provides a sound foundation for the overlying skin, underlying skeleton and nose. Without good functional repair of the muscles in the cleft lip, the result is never optimal.

The skeletal foundation, which is often deficient, must also be considered when esthetics of the lip are assessed. This foundation supports the lip. Maxillary alveolar clefts require bone grafts to support the lip, ala of the nose, periodontium of the teeth and implants (if required). Bone grafts to the cleft maxilla are often inadequate and should be re-assessed. Patients with cleft lips often have a maxillary skeletal anteroposterior deficiency, with a Class III malocclusion and lack of support for the lip.

Patient Assessment and Surgery

The importance of the underlying bony skeleton to the lip and nose is often overlooked. The soft tissue lies on the bony skeleton and dentition, so a good skeletal base and dentition are essential to the solid foundation that supports nasolabial function and soft-tissue esthetics. Therefore, for a previously repaired lip, more than the soft tissues must be evaluated; the repaired cleft lip, nose, alveolus, maxilla, palate and dentition must be critically assessed. The bone must be evaluated to determine whether adequate bone stock is present in the cleft maxilla. Asking whether oronasal regurgitation occurs may help determine whether an oronasal fistula exists and whether there is a lack of bone. For example, an affirmative answer to the question of whether ice cream or yogurt comes out of the nose when eating it indicates a possible oral nasal fistula. Clinical examination helps determine the existence of a vestibular or palatal oral nasal fistula.

Functional assessment of the lip is important to achieving optimal esthetics. The lip is assessed at rest (**Fig. 1**) and in projection (**Fig. 2**) to determine whether the muscular repair done in the previous surgery was adequate and accurate. The lip in repose is assessed for symmetry, scar and vermilion deformities. The lip in projection is assessed for symmetry and muscle bulge. Radiographic examination is done initially with periapical, occlusal (**Fig. 3**) and panoramic radiographs, followed by

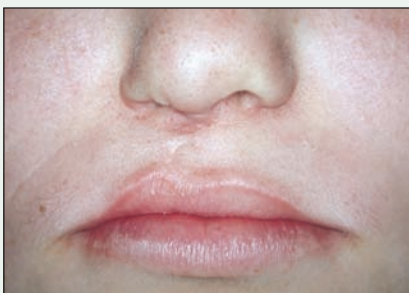

Figure 1: Lips at rest before surgery.

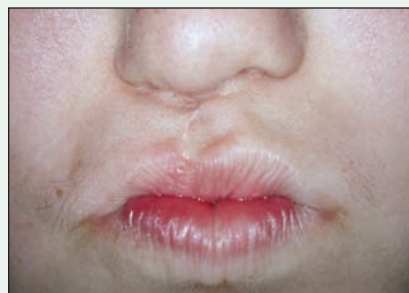

Figure 2: Lips in projection before surgery.

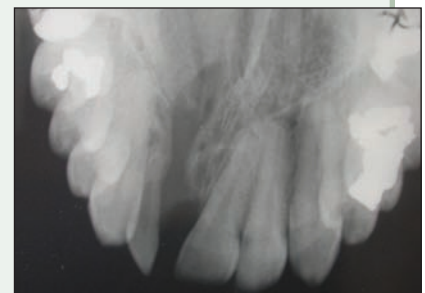


Figure 3: Cleft alveolus.

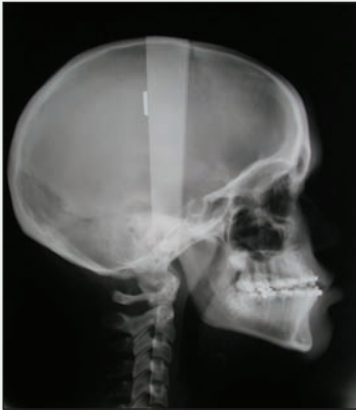

Figure 4: Maxillary deficiency.

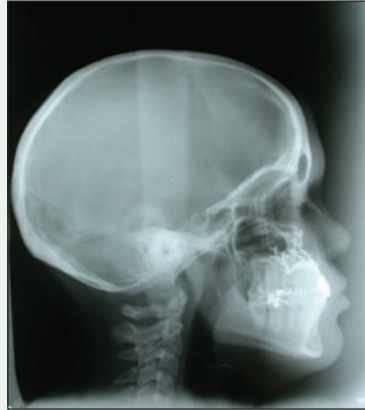

Figure 5: After Le Fort I osteotomy.

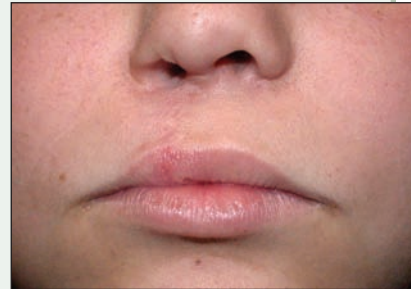

Figure 6: After functional lip revision, Le Fort I osteotomy and bone graft.

a computed tomography scan, if indicated, to get a better appreciation of the anatomy of the cleft maxilla. The nose is assessed for asymmetry and flattening of the ala on the cleft side. The facial skeleton is assessed for dentoskeletal abnormalities by clinical evaluation and lateral cephalometric radiograph (Fig. 4) and analysis. Maxillary anteroposterior deficiency and consequent lack of lip support are common in patients with a cleft lip.

The foundation supporting the lip is addressed first in the noninfant patient with a cleft lip. Correction aims to improve the deficiencies. If there is a cleft maxilla or insufficient bone stock at the cleft site, an iliac-crest bone graft would provide support for not only the teeth or implants, but also the nose and lip. Maxillary anteroposterior deficiency is easily corrected with a Le Fort I osteotomy (Fig. 5), which helps with lip esthetics. Correction of the underlying facial skeleton provides global facial balance and support for the overlying lip. The lip incision is designed to restore nasal tissue, lip skin and vermilion to their correct positions, with modifications based on the incision design from the previous lip repair. A simple geometric revision of the lip skin only is usually inadequate. A secondary functional cheilorhinoplasty, which involves anatomic and physiologic muscle reconstruction as well as nasal surgery to improve symmetry, can be done at any age and will result in a much more functional and esthetic lip (Fig. 6) and nose. If bone grafting and orthognathic surgery in addition to a functional cheilorhinoplasty

in a unilateral cleft are indicated, these can usually all be done during the same operation. However, they are done as separate procedures for patients with a bilateral cleft to avoid compromising the vascular supply to the premaxilla. Although the ideal age for the bone graft and secondary functional cheilorhinoplasty is about 6 years, coinciding with eruption of the lateral incisor, patients should not be denied the benefits of these operations because they are adults. ✦

THE AUTHOR



Dr. Michael S. Shimizu is assistant professor in oral and maxillofacial surgery and director of the general practice residency in hospital dentistry, The University of Western Ontario and London Health Sciences Centre, London, Ontario. Email: michael.shimizu@schulich.uwo.ca

Further Reading

Precious DS, editor. Cleft lip and palate: a physiological approach. *Oral and Maxillofacial Surgery Clinics of North America*; August 2000, Vol. 12, No. 3.

QUESTION 6

Are there special considerations when providing “minimal sedation” for pediatric patients?

Background

Minimal sedation” is a drug-induced state during which a patient may experience impairment of cognitive function and coordination, but is responsive to verbal command; ventilatory and cardiovascular functions remain unaffected.¹ Under certain circumstances, a dentist may elect to provide minimal sedation for a patient. The provincial licensing bodies delineate standards for each level of sedation (minimal, moderate and deep) with respect to training and monitoring requirements (Fig. 1) that must be met by dentists and their staff to permit safe administration of conscious sedation in their practices. Providers are expected to have taken additional training in conscious sedation case selection and management through a formally approved continuing education or specialty program and to have achieved competency to support the level of sedation they intend to provide.

Minimal sedation may enhance, but should not replace, accepted nonpharmacologic behaviour guidance techniques in pediatric dentistry. The sedative chosen must permit a wide margin of safety with minimal likelihood of progression to a state of unconsciousness. The general dentist’s decision to use minimal sedation must be based on careful case selection and a benefit-versus-risk evaluation. For example, oral midazolam has been shown to be of benefit in managing the behaviour of young children if limited to cases of simple re-

storative dentistry or extractions over a maximum of 2 visits.²

The unique physiology of the pediatric patient poses certain challenges in using minimal sedation that must be clearly understood. Children are not small adults, as confirmed by their increased tonsillar volume and less-developed drug metabolic pathways. Their response to sedation may vary considerably, ranging from drowsiness to profound irritability due to idiosyncratic drug reactions. Co-existing medical conditions and complex behavioural issues may complicate or even contraindicate minimal sedation. Younger pediatric patients, in particular, are more susceptible to respiratory depression during minimal sedation and may easily pass into moderate or deep sedation. Also, sedatives tend to potentiate central nervous system depression, which may be produced by the concomitant use of local anesthesia, further increasing the risk of adverse outcomes.

Training for dentists and their staff in the delivery of minimal sedation should encompass proper preoperative assessment, monitoring requirements, emergency preparedness — including airway management, the use of reversal agents and supportive equipment and techniques — should the child enter a deeper stage of sedation during treatment.

Considerations for Case Management

The scope and nature of treatment required, the experience and training of the provider and the preference of the parent will dictate overall behaviour guidance strategy, including sedation modality and agent. For the pediatric population, some commonly used sedating agents include dimenhydrinate, hydroxyzine, midazolam, chloral hydrate and nitrous oxide/oxygen. Thorough medical assessment should include a review of past and current medical status and medication use. For some children, consultation with their physician may be necessary. Visual appraisal of tonsillar volume to assess airway patency and a review of baseline vital signs should be carried out. Proper documentation of parental informed consent should include detailed preoperative preparations (including fasting requirements),



Figure 1: An example of suitable monitoring equipment to assess pulse, oxygen saturation and blood pressure during conscious sedation.

possible and expected reactions intraoperatively and postoperative instructions.

To induce minimal sedation, a single agent can be administered to a child deemed fit, based on recommended pediatric doses for each drug. Doses should be carefully calculated, measured and delivered. Monitoring requirements must, at a minimum, include constant visual assessment of responsiveness and respiratory effort. Should the child enter a deeper state of sedation and non-responsiveness, then airway patency must be maintained and equipment to assess and support oxygen saturation, pulse and blood pressure should be readily available. Treatment should be discontinued and, if necessary, the appropriate reversal agent should be administered as a “rescue” measure and monitoring should continue until complete recovery.

The prudent practitioner may consider using minimal sedation as an adjunct to pediatric behaviour guidance for carefully selected cases after a

full review of the risks and benefits. All cases using minimal sedation should be supported by well-trained staff and appropriately equipped treatment facilities, as dictated by the specific requirements of regional regulating bodies. ✦

THE AUTHOR



Dr. Karen M. Campbell is assistant professor in the division of orthodontics and pediatric dentistry, Schulich School of Medicine & Dentistry, The University of Western Ontario, London, Ontario. Email: kcampb62@schulich.uwo.ca

References

1. American Academy of Pediatrics and the American Academy of Pediatric Dentistry. Clinical guidelines. Guideline for monitoring and management of pediatric patients during and after sedation for diagnostic and therapeutic procedures. In: *Reference Manual* 30(7):143–159. Chicago: American Academy of Pediatric Dentistry; 2006. Available: www.aapd.org/media/Policies_Guidelines/G_Sedation.pdf (accessed 2009 April 27).
2. Day PF, Power AM, Hibbert SA, Paterson SA. Effectiveness of oral midazolam for paediatric dental care: a retrospective study in two specialist centres. *Eur Arch Paediatr Dent* 2006; 7(4):228–35.