

Idiopathic Gingival Fibromatosis Associated with Generalized Aggressive Periodontitis: A Case Report

Rashi Chaturvedi, MDS, DNB

Contact Author

Dr. Chaturvedi

Email: rashichaturvedi@yahoo.co.in



ABSTRACT

Idiopathic gingival fibromatosis, a benign, slow-growing proliferation of the gingival tissues, is genetically heterogeneous. This condition is usually part of a syndrome or, rarely, an isolated disorder. Aggressive periodontitis, another genetically transmitted disorder of the periodontium, typically results in severe, rapid destruction of the tooth-supporting apparatus. The increased susceptibility of the host population with aggressive periodontitis may be caused by the combined effects of multiple genes and their interaction with various environmental factors. Functional abnormalities of neutrophils have also been implicated in the etiopathogenesis of aggressive periodontitis. We present a rare case of a nonsyndromic idiopathic gingival fibromatosis associated with generalized aggressive periodontitis. We established the patient's diagnosis through clinical and radiologic assessment, histopathologic findings and immunologic analysis of neutrophil function with a nitro-blue-tetrazolium reduction test. We describe an interdisciplinary approach to the treatment of the patient.

For citation purposes, the electronic version is the definitive version of this article: www.cda-adc.ca/jcda/vol-75/issue-4/291.html

Idiopathic gingival fibromatosis is a rare hereditary condition that has no specific cause.¹ Investigations are ongoing to establish the genetic linkage and heterogeneity associated with it.²⁻⁵ This condition may manifest as an autosomal-dominant⁶⁻⁹ or, less commonly, an autosomal-recessive mode of inheritance,¹⁰⁻¹² either as an isolated disorder or as part of a syndrome.⁶ Syndromic gingival fibromatosis has been associated with ancillary features such as hypertrichosis, mental retardation, epilepsy, progressive sensorineural hearing loss and abnormalities of the extremities, particularly of the fingers and toes.^{6,13} Autosomal-dominant forms of gingival fibromatosis, which are usually non-

syndromic, have been genetically linked to the chromosome 2p21-p22² and 5q13-q22.⁴ Recently, a mutation in the son of sevenless-1 (*SOS-1*) gene has been suggested as a possible cause of isolated (nonsyndromic) gingival fibromatosis, but no definite linkage has been established.⁵

Idiopathic gingival fibromatosis is a slowly progressive benign enlargement that affects the marginal gingiva, attached gingiva and interdental papilla. The fibromatosis may potentially cover the exposed tooth surfaces, causing esthetic and functional problems, and in extreme cases may distort the jaws. The gingival tissues are usually pink and nonhemorrhagic, and have a firm, fibrotic

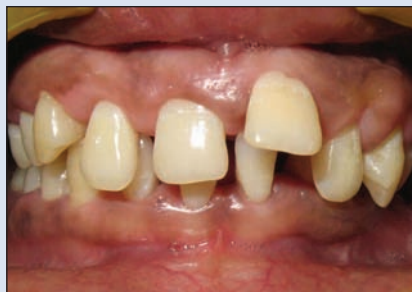

Figure 1: Preoperative intraoral frontal view of the maxillary and mandibular arches.

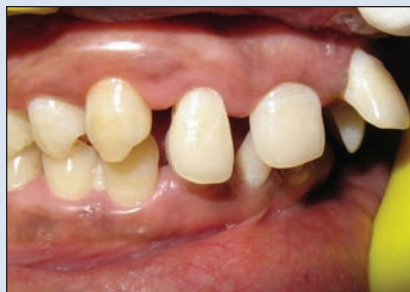

Figure 2: Preoperative intraoral right lateral view of the maxillary and mandibular arches.

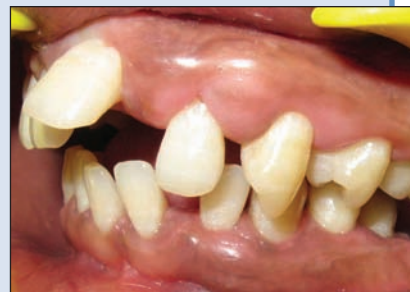

Figure 3: Preoperative intraoral left lateral view of the maxillary and mandibular arches.

consistency.^{1,13-17} Histopathologically, the bulbous increased connective tissue is relatively avascular and has densely arranged collagen-fibre bundles, numerous fibroblasts and mild chronic inflammatory cells. The overlying epithelium is thickened and acanthotic, and has elongated rete ridges.^{1,13-18} Unusual findings include the presence of small calcified particles, amyloid deposits, islands of odontogenic epithelium and osseous metaplasia in the connective tissue, and ulcerations of the overlying mucosa.¹⁹

Aggressive periodontitis comprises another group of genetically inherited diseases that represent a severe and rapidly progressive form of periodontitis. Characteristically, these diseases tend to exhibit familial aggregation and there are no factors in the medical history that seem associated with the condition.²⁰

Aggressive forms of periodontitis are currently considered to be multifactorial diseases that develop as a result of complex interactions between specific host genes and the environment. Various factors have been identified that increase the risk of developing aggressive periodontitis, including familial aggregation, single nucleotide polymorphisms, neutrophil functional defects, antibodies to specific bacteria, herpes virus infection, smoking and stress.²¹

Generalized aggressive periodontitis usually affects people under 30 years of age. They have a poor serum-antibody response to infecting agents and pronounced episodic destruction of the attachment and alveolar bone. The loss of attachment affects at least 3 permanent teeth other than first molars and incisors.²²

We report here an unusual case of a nonsyndromic, idiopathic gingival fibromatosis associated with generalized aggressive periodontitis. Only one other case with such an association has been reported to date.¹⁸ We discuss our patient's clinical findings, histopathologic evaluation, analysis of neutrophil function and treatment plan.

Case History

Diagnosis

A 23-year-old man reported to the outpatient department of our institute complaining of pain and swelling in the gums and an inability to chew food. The patient was also concerned about the progressively increased spacing between his upper front teeth and their movement away from their original positions.

The medical history revealed that the patient's gums had progressively enlarged over the last 6 to 7 years and that the patient had pain during mastication and increased tooth mobility, especially of all 4 first molars, 3 of which had to be extracted about 2 years before. Nothing in the patient's medical and family history seemed related to the condition, and no associated endocrinological abnormality could be detected. The patient was not receiving any anti-epileptic, antihypertensive or immunosuppressive medications that could contribute to the gingival enlargement. However, the patient had smoked up to 20 cigarettes a day for the past 4 to 5 years and drank alcohol about 2 or 3 times a week.

Intraoral examination revealed moderate-to-severe gingival overgrowth of a firm, dense and fibrotic consistency that involved both the maxillary and mandibular arches (**Figs. 1 to 3**). The patient had generalized tooth mobility with a severe pathologic migration, especially of the upper anterior teeth. Full-mouth periodontal charting, including assessment of probing depth and clinical attachment level, revealed deep pockets throughout the mouth, and scanty plaque and calculus deposits.

The radiographic findings, which corroborated those of the clinical examination, revealed severe generalized alveolar bone loss (**Fig. 4**). The peripheral blood results were normal and correlated with an absence of any history of systemic disease.

Based on all these findings, a provisional diagnosis of idiopathic gingival enlargement with generalized aggressive periodontitis was made.

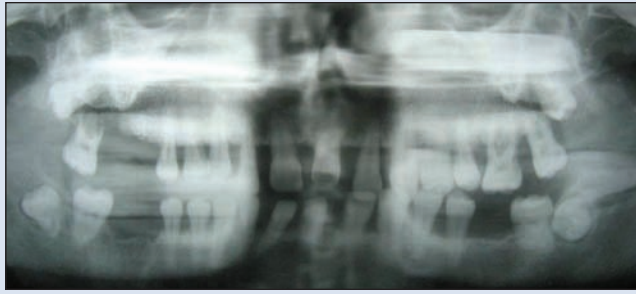


Figure 4: Preoperative panoramic radiograph of the maxillary and mandibular arches showing severe generalized alveolar bone loss.

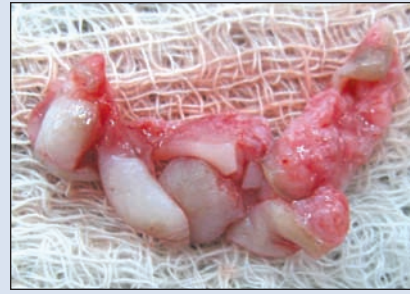


Figure 5: Gingival tissues excised during periodontal surgery were sent for histopathologic assessment.

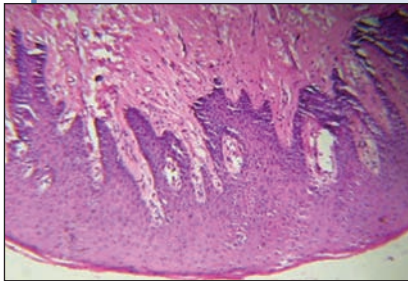


Figure 6: Photomicrograph of the specimen illustrating the presence of a thickened acanthotic epithelium with elongated rete ridges and a densely fibrous connective tissue with numerous fibroblasts (original magnification 100x).

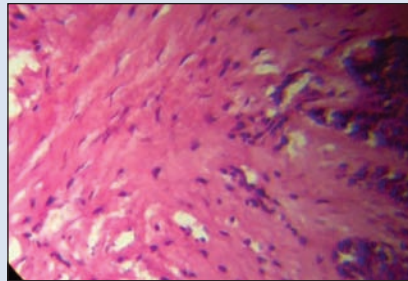


Figure 7: Photomicrograph of the connective tissue illustrating the presence of densely arranged collagen bundles with numerous fibroblasts and few mixed inflammatory cells, mainly around blood vessels (original magnification 400x).

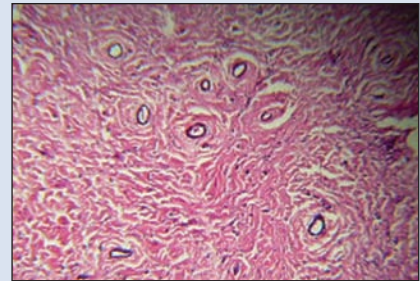


Figure 8: Photomicrograph illustrating the presence of dense collagen bundles in the connective tissue with multiple areas of neovascularization (original magnification 100x).

Histopathologic Findings

The attached gingiva excised from the buccal and interdental areas during surgery (Fig. 5) was immediately fixed in 10% buffered formaldehyde solution and sent for histopathologic examination. The specimen was processed and then embedded in paraffin wax. Multiple 5-mm serial sections were prepared, stained with hematoxylin and eosin, and viewed under a trinocular light microscope with flat-field objective lenses at 100x and 400x magnifications.

The microscopic evaluation of these sections revealed parakeratinized stratified squamous acanthotic epithelia with thin long rete ridges extending into the connective tissue. The underlying connective tissue showed dense wavy bundles of collagen fibres containing numerous fibrocytes and fibroblasts. Some sections in the connective tissue exhibited infiltration of chronic inflammatory cells, a few scattered multinucleated giant cells and areas of neovascularization that had red blood corpuscles within the lumen of the blood vessels (Figs. 6 to 8).

Analysis of Neutrophil Function

The phagocytic ability of the patient's polymorphonuclear leukocytic cells was assessed with a nitro-blue-

tetrazolium (NBT) reduction test. During this test, polymorphonuclear leucocytes (PMNLs) were stimulated with heat-killed spores of *Candida albicans* to evaluate the oxidative pathway. Normal granulocytes metabolically activated by phagocytosis reduce NBT to blue formazan. Eighty percent of the patient's cells contained reduced blue formazan, which was the percentage of PMNLs producing a respiratory burst, thereby indicating the normal functioning of the oxygen-dependent leukocytic bactericidal system.

Treatment

The patient initially underwent phase 1 periodontal therapy that comprised scaling and root planing, oral hygiene instructions and adjunctive administration of systemic doxycycline (100 mg twice a day, on the first day, followed by 100 mg once a day for 14 days).^{23,24} Phase 2 therapy involved periodontal surgery in all 4 quadrants that involved an internal bevel gingivectomy combined with open-flap debridement (Figs. 9 and 10).

The patient was then referred to a specialist for orthodontic correction of malaligned teeth, followed by prosthetic replacement of the missing teeth. The patient was followed up regularly; no recurrence of gingival

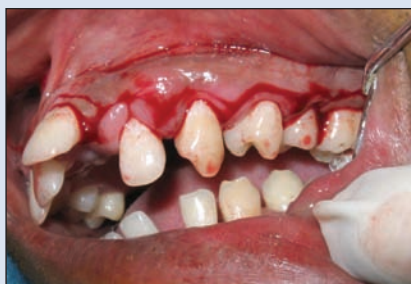

Figure 9: Internal bevel gingivectomy procedure on the left maxillary quadrant.

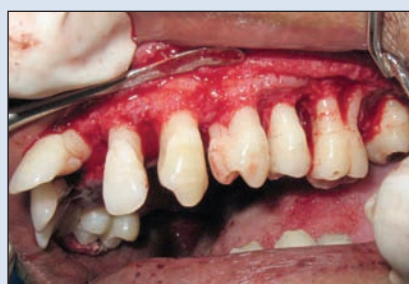

Figure 10: Open-flap debridement showing the alveolar bone defects.

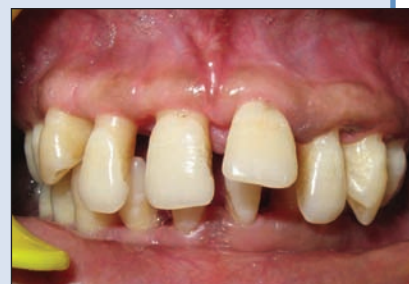

Figure 11: Frontal view of the maxillary and mandibular arches 6 months after surgery.

overgrowth was observed 6 months after the surgery (Fig. 11).

Discussion

Gingival fibromatosis is frequently part of various syndromes, including Rutherford syndrome, Cross syndrome, Zimmerman-Laband syndrome, Prune belly syndrome, Ramon syndrome, Murray-Puretic-Drescher syndrome and Jones syndrome.^{6,13} Recent findings⁵ have identified a mutation in the *SOS-1* gene that segregates the hereditary gingival fibromatosis phenotype. Identification of the specific genetic basis for hereditary gingival fibromatosis should help elucidate the pathogenic mechanisms that cause gingival enlargement.

Aggressive periodontitis is typically characterized by familial aggregation because of evidence of genetic predisposition that was derived from segregation analysis of affected families.²¹ Mendelian inheritance occurs, and autosomal (dominant and recessive) transmission and X-linked transmission have been proposed.²¹ Our patient had a diagnosis of generalized aggressive periodontitis with idiopathic gingival fibromatosis, based on his clinical findings and no history of familial aggregation. Presence of generalized aggressive periodontitis in a case of otherwise nonsyndromic gingival fibromatosis opens avenues for research into the existence of a predictable association between the 2 entities. A case of hereditary gingival fibromatosis associated with generalized aggressive periodontitis reported earlier indicated the possible emergence of a new syndrome, but no definite genetic linkage could be established.¹⁸

The results of the histopathologic evaluation of the biopsied tissues of our patient were consistent with those for fibrous gingival hyperplasia: the presence of a thickened acanthotic epithelium with elongated rete ridges and densely arranged collagen bundles with numerous fibroblasts, coupled with some sections that exhibited neovascularization and a few scattered giant cells in the underlying connective tissue. However, the histologic

features of gingival fibromatosis are usually nonspecific and a definitive diagnosis should be established based on family history, clinical findings, genetic analysis, and immunologic and microbiological assessments.^{13,14}

Neutrophils play a major cellular role in the innate immune response against invading periodontopathic microorganisms. Defective adherence, chemotaxis, phagocytosis and intracellular killing are all implicated in the increased susceptibility of the host population to periodontitis, and these PMNL functional defects are genetically transmitted.²⁵ Recent findings support the role of neutrophil abnormalities in aggressive periodontitis and this is attributed to the chronic hyperactivated, or primed, state of the neutrophils.²⁶ The PMNLs in patients with aggressive periodontitis are hyperfunctional; the excess activity and release of toxic products from these cells are responsible for the existing severe tissue destruction.²⁶

In this report, the NBT reduction test used to analyze neutrophil function^{27,28} measures neither phagocytic nor killing ability, but is an indicator of the degree of activity in the enzyme systems that are usually triggered by phagocytosis and ultimately cause bacterial killing. Results of this test were positive for 80% of our patient's cells, a finding that indicated that a large proportion of the neutrophils exhibited an oxidative burst.

Although a superoxide dismutase inhibitable cytochrome C-reduction test should be done to quantitatively assess the generation of superoxide to identify the hyperprimed state of the neutrophils,²⁸ this test could not be carried out because of institutional constraints. Nevertheless, the high percentage of neutrophils that were positive during the NBT test demonstrated their ability to respond with increased metabolic activity to a bacterial or endotoxin stimulus.

Recent evidence identifies the role of environmental factors in the clinical expression of aggressive periodontitis. Smoking is a major risk factor for patients

with generalized aggressive periodontitis; smokers have a greater incidence and severity of attachment loss than nonsmokers.²⁹ Our patient, who was a chronic smoker, had severe attachment and alveolar bone loss.

Treatment of gingival fibromatosis is essential because it causes difficulties with mastication, speech problems, malpositioning of teeth, esthetic effects and psychological difficulties for the patient.

In a case of gingival enlargement with deep pockets and severe loss of underlying alveolar bone, an internal bevel gingivectomy with open-flap debridement is indicated.³⁰ This surgical procedure was done for our patient to eliminate pockets, making plaque control easier; to reduce the bulbous gingival tissues; and to enable the regeneration or repair of the alveolar bone defect.

Our patient is being regularly monitored clinically and radiographically for improvement in his periodontal condition, as well as for any recurrence of gingival overgrowth. He will receive orthodontic treatment^{15,31} and prosthetic rehabilitation, which are appropriate follow-up strategies to surgery for gingival fibromatosis.

Conclusions

This case highlights the unusual coexistence of non-syndromic idiopathic gingival fibromatosis with generalized aggressive periodontitis. Diagnosis was based on clinical, radiographic, histopathologic and immunologic assessment. However, further research is needed to establish a syndromic association between the 2 conditions based on genetic evaluation and linkage studies. ♦

THE AUTHOR



Dr. Chaturvedi is senior lecturer in the department of periodontics, Dr. H.S.J. Institute of Dental Sciences and Hospital, Panjab University, Chandigarh, India.

Acknowledgements: The author wishes to thank the oral pathology department of Dr. H.S.J Institute of Dental Sciences, Chandigarh, India, and the immunopathology department of P.G.I.M.E.R, Chandigarh, India, for the investigations done, and Dr. Tarun Das and Dr. Sudhir Bhandari for their guidance during the preparation of the manuscript.

Correspondence to: Dr. Rashi Chaturvedi, G-6, Gaurav Apartments, Saket, New Delhi 110017, India.

The author has no declared financial interests.

This article has been peer reviewed.

References

- Carranza FA, Hogan EL. Gingival enlargement. In: Newman MG, Takei HH, Carranza FA. Clinical periodontology. 9th ed. Philadelphia: Saunders; 2002. p. 279–96.
- Hart TC, Pallos D, Bowden DW, Bolyard J, Pettenati MJ, Cortelli JR. Genetic linkage of hereditary gingival fibromatosis to chromosome 2p21. *Am J Hum Genet* 1998; 62(4):876–83.
- Hart TC, Pallos D, Bozzo L, Almeida OP, Marazita ML, O'Connell JR, and other. Evidence of genetic heterogeneity for hereditary gingival fibromatosis. *J Dent Res* 2000; 79(10):1758–64.

- Xiao S, Bu L, Zhu L, Zheng G, Yang M, Qian M, and others. A new locus for hereditary gingival fibromatosis (GINGF2) maps to 5q13-q22. *Genomics* 2001; 74(2):180–5.
- Hart TC, Zhang Y, Gorry MC, Hart PS, Cooper M, Marazita ML, and others. A mutation in the SOS1 gene causes hereditary gingival fibromatosis type 1. *Am J Hum Genet* 2002; 70(4):943–54.
- Gorlin RJ, Cohen MM, Levin LS. Syndromes of the head and neck. 3rd ed. New York: Oxford Press (Oxford Monographs on Medical Genetics); 1990. p. 847–52.
- Bozzo L, de Almeida OP, Scully C, Aldred MJ. Hereditary gingival fibromatosis. Report of an extensive four-generation pedigree. *Oral Surg Oral Med Oral Pathol* 1994; 78(4):452–4.
- Bozzo L, Machado MA, de Almeida OP, Lopes MA, Coletta RD. Hereditary gingival fibromatosis: report of three cases. *J Clin Pediatr Dent* 2000; 25(1):41–6.
- Martelli-Junior H, Lemos DP, Silva CO, Graner E, Coletta RD. Hereditary gingival fibromatosis: report of a five-generation family using cellular proliferation analysis. *J Periodontol* 2005; 76(12):2299–305.
- Singer SL, Goldblatt J, Hallam LA, Winters JC. Hereditary gingival fibromatosis with a recessive mode of inheritance. Case reports. *Aust Dent J* 1993; 38(6):427–32.
- Kharbanda P, Sidhu SS, Panda SK, Deshmukh R. Gingival fibromatosis: study of three generations with consanguinity. *Quintessence Int* 1993; 24(3):161–4.
- Goldblatt J, Singer SL. Autosomal recessive gingival fibromatosis with distinctive facies. *Clin Genet* 1992; 42(6):306–8.
- Coletta RD, Graner E. Hereditary gingival fibromatosis: a systematic review. *J Periodontol* 2006; 77(5):753–64.
- DeAngelo S, Murphy J, Claman L, Kalmar J, Leblebicioglu B. Hereditary gingival fibromatosis — a review. *Compend Contin Educ Dent* 2007; 28(3):138–43, quiz 144, 152.
- Kelekis-Cholakakis AK, Wiltshire WA, Birek C. Treatment and long-term follow-up of a patient with hereditary gingival fibromatosis: a case report. *J Can Dent Assoc* 2002; 68(5):290–4.
- Ramer M, Marrone J, Stahl B, Burakoff R. A case report. Hereditary gingival fibromatosis: identification, treatment, control. *J Am Dent Assoc* 1996; 127(4):493–5.
- Baptista IP. Hereditary gingival fibromatosis: a case report. *J Clin Periodontol* 2002; 29(9):871–4.
- Casavecchia P, Uzel MI, Kantarci A, Hasturk H, Dibart S, Hart TC, and others. Hereditary gingival fibromatosis associated with generalized aggressive periodontitis: a case report. *J Periodontol* 2004; 75(5):770–8.
- Gunhan O, Gardner DG, Bostanci H, Gunhan M. Familial gingival fibromatosis with unusual histological findings. *J Periodontol* 1995; 66(11):1008–11.
- Lang NP, Bartold PM, Cullinam M, Jeffcoat M, Mombelli A, Murakami S, and others. Consensus report: aggressive periodontitis. *Ann Periodontol* 1999; 4(1):53.
- Meng H, Xu L, Li Q, Han J, Zhao Y. Determinants of host susceptibility in aggressive periodontitis. *Periodontol 2000* 2007; 43:133–59.
- Tonetti M, Mombelli A. Early onset periodontitis. *Ann Periodontol* 1999; 4(1):39–52.
- Feres M, Haffajee AD, Goncalves C, Allard KA, Som S, Smith C, and others. Systemic doxycycline administration in the treatment of periodontal infections. I. Effect on the subgingival microbiota. *J Clin Periodontol* 1999; 26(12):775–83.
- Mandell RL, Socransky SS. Microbiological and clinical effects of surgery plus doxycycline on juvenile periodontitis. *J Periodontol* 1988; 59(6):373–9.
- Sahingur SE, Cohen RE. Analysis of host responses and risk for disease progression. *Periodontol 2000* 2004; 34:57–83.
- Kantarci A, Oyaizu K, Van Dyke TE. Neutrophil-mediated tissue injury in periodontal disease pathogenesis: findings from localized aggressive periodontitis. *J Periodontol* 2003; 74(1):66–75.
- Kowolik MJ, Raeburn JA. Functional integrity of gingival crevicular neutrophil polymorphonuclear leucocytes as demonstrated by nitroblue tetrazolium reduction. *J Periodont Res* 1980; 15(5):483–91.
- Rose NR, Macario EC, Fahey JL, Friedman H, Penn GM. Manual of clinical laboratory immunology. 4th ed. Washington: American Society for Microbiology; 1992.
- Schenkein HA, Gunsolley JC, Koertge TE, Schenkein JG, Tew JG. Smoking and its effects on early-onset periodontitis. *J Am Dent Assoc* 1995; 126(8):1107–13.
- Camargo PM, Carranza FA. Treatment of gingival enlargement. In: Newman MG, Takei HH, Carranza FA. Clinical periodontology. 9th ed. Philadelphia: Saunders; 2002. p. 754–61.
- Clocheret K, Dekeyser C, Carels C, Willems G. Idiopathic gingival hyperplasia and orthodontic treatment: a case report. *J Orthod* 2003; 30(1):13–9.