

Metastatic Adenocarcinoma Involving Several Bones of the Body and the Cranio-Maxillofacial Region: A Case Report

Ana Cláudia Amorim Gomes, DDS, MSc, PhD; Patrício José de Oliveira Neto, DDS; Emanuel Dias de Oliveira e Silva, DDS; Emanuel Sávio, DDS, MSc, PhD; Ivo Cavalcante Pita Neto, DDS

Contact Author

Dr. P. Neto
Email: patricneto@yahoo.com.br



ABSTRACT

Malignant tumours that have metastasized to the oral and maxillofacial region from distant sites account for only 1% of all malignancies of the jaw. These metastatic tumours are most often located in the mandible, and the majority of these in the molar region. The most common primary sources of metastatic tumours found in the oral region are the lung, kidney and prostate gland for the males, and the breast, genital organs and kidneys for females. The exact location of the primary tumour, however, is often difficult, sometimes impossible, to identify. We present the case of a 51-year-old woman with metastatic adenocarcinoma involving the condyle and mandible, and other bones of the body. The oral presentation of the metastasis was the source of the definitive diagnosis.

For citation purposes, the electronic version is the definitive version of this article: www.cda-adc.ca/jcda/vol-75/issue-3/211.html

Metastatic malignancies found in the oral and maxillofacial region are rare and account for only 1% of all malignancies of the jaw.¹⁻¹² In 22% to 30% of cases, the oral presentation of metastasis is the first sign of malignant disease^{3,5,6}; in about 67% of cases, metastatic lesions are detected at the same time as the primary lesion.³ Malignant epithelial tumours (carcinomas) metastasize to the oral region more commonly than mesenchymal tumours (sarcomas).³ The jaw bones are involved more frequently than the oral soft tissues.^{1,3-5} The mandible is the most often affected region and the molar area, the most frequently involved site. The purpose of this article is to describe a case of a metastatic adenocarcinoma that involved several bones of the body and the cranio-maxillofacial region, and to discuss the incidence, prognosis and treatment of such cases.

Case Report

A 51-year-old woman came to the department of clinical medicine of Barão de Lucena Hospital in January 2006, complaining of palpable masses in the skull and the mandible on the left side. The patient reported that she had noticed the lesions about 2 months earlier, first in the mandible and then in the skull, but no pain. When questioned about her symptoms, she reported weakness, anorexia, loss of about 10 kg in 2 months and an ache in her right hip, but no fever, cough or dyspnea. A review of the patient's medical history revealed that she had systemic arterial hypertension that was controlled with drugs and that she had been a smoker for at least 30 years. Examination showed that she had a normal respiratory rate and was pale. Clinical examination of her face and scalp revealed

facial asymmetry, the result of a painless nodule on the left side of the mandible. The nodule had firm smooth borders and measured about 4 cm. Two other nodules with the same characteristics were found in the parietal (about 3 cm) and occipital (about 2 cm) regions. The patient was admitted and diagnoses of lymphoma and metastatic bone tumour were investigated. A blood count, tests of biochemistry of the blood, and radiographs of the skull, mandibular, chest and hip were ordered.

Results of the blood tests showed that the patient was anemic (8.5 g/dL hemoglobin). Radiographic examination revealed osteolytic lesions in the skull (**Fig. 1**) and bilaterally in the iliac crest (**Fig. 2**), but the radiographs of the mandible provided no information about the lesions. The blood work was in the normal range and the chest radiographs showed no lesions. Because radiographs of the skull showed lesions that looked like multiple myeloma, a test for Bence Jones proteinuria was ordered to screen for multiple myeloma, but negative test results ruled out this diagnosis.

Because of the lesion in the mandible, the patient was referred to the department of oral and maxillofacial surgery service at the Oswaldo Cruz University Hospital 2 weeks after her admission. After doing a physical examination and examining the patient's radiographs, we requested computed tomography scans of the face to better identify the limits of the lesion in the lower jaw. Fifteen days later, results of the tomographic images revealed destructive lesions involving 3 sites in the left and right parietal regions of the skull cap and in the occipital region, instead of the 2 identified from the clinical examination, and similar lesions in the retromolar region. These lesions caused osteolysis of the marrow and cortical bone (**Figs. 3 and 4**).

Results of further laboratory tests revealed a hemoglobin level of 7.9 g/dL, a hematocrit level of 26% and a red cell count of $3.5 \times 10^6 \mu\text{L}$. We reserved and classified a supply of blood because of the patient's anemia.

The next week, the diagnostic incisal biopsy that we ordered of the retromolar region was done under general anesthesia through an incision in the mucosa of the oblique external line without complications, after the patient had received transfusion of 2 units of red cells (**Fig. 5**). Results of the histologic examination of the surgical specimen showed metastatic adenocarcinoma. Histological sections stained with hematoxylin and eosin revealed fragments of a malignant neoplasm characterized by the formation of epithelial nests among a stroma of fibrous connective tissue with areas of hyalinization. The cells forming the epithelialized nests exhibited hyperchromatic nuclei with an eosinophilic cytoplasm or a vesicular nucleus with a clear cytoplasm. Extensive areas of necrosis were also observed (**Fig. 6**)

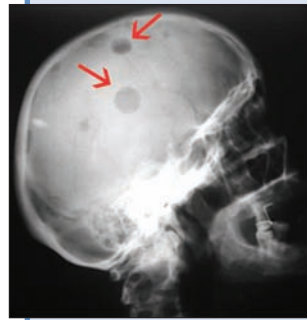

Figure 1: Radiograph of the lateral skull showing radiolucent bony lesions (arrows).

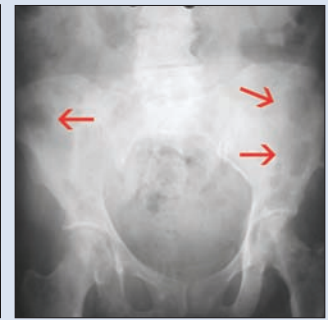

Figure 2: Radiograph of the hip showing bilateral lesions in the iliac crest (arrows).

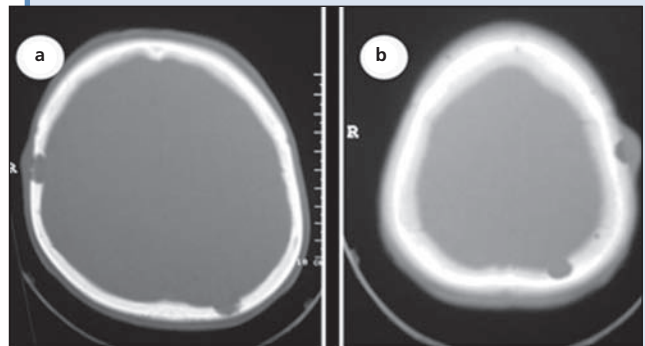


Figure 3: Computed tomography (CT) showing involvement at 3 sites of the skull cap: (a) hard tissue; (b) soft tissue.

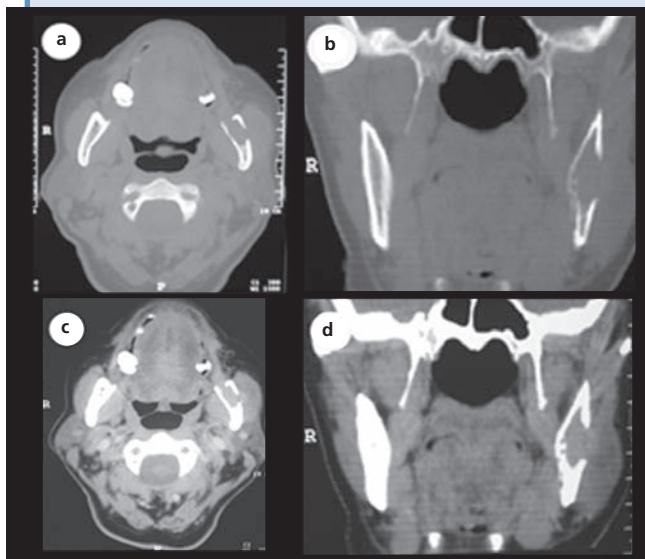


Figure 4: Axial and coronal CT scans showing involvement of the posterior aspect of the mandible in the retromolar region: (a) and (b) axial and coronal CT scans of bone involvement; (c) and (d) axial and coronal CT scans of a mass involving the mandible.

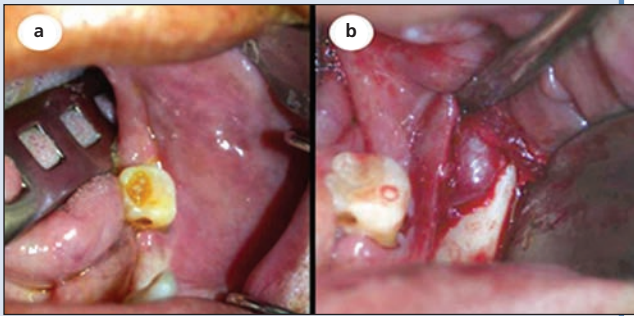


Figure 5: Intraoperative view of the retromolar region. (a) Initial appearance before incision. (b) After incision and divulsion, showing the destruction of the buccal cortical bone and the specimen to be biopsied.

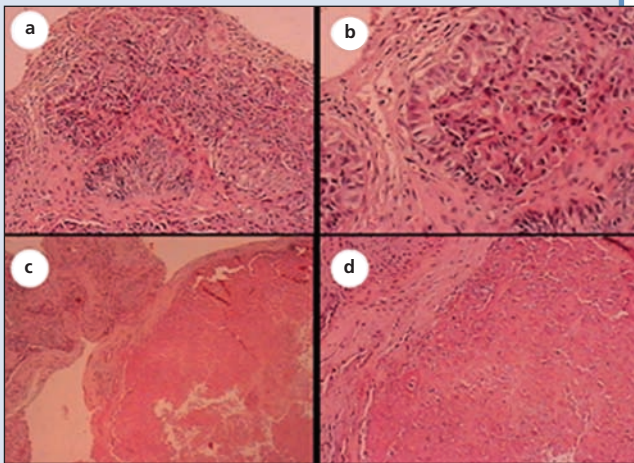


Figure 6: (a) Epithelial nests of neoplastic cells among a stroma of fibrous connective tissue with areas of hyalinization (original magnification $\times 100$). (b) Higher-power view showing the neoplastic cells (original magnification $\times 200$). (c) Extensive areas of necrosis were also observed on the right side (original magnification $\times 40$). (d) Higher-power view of Fig. 6c (original magnification $\times 40$).

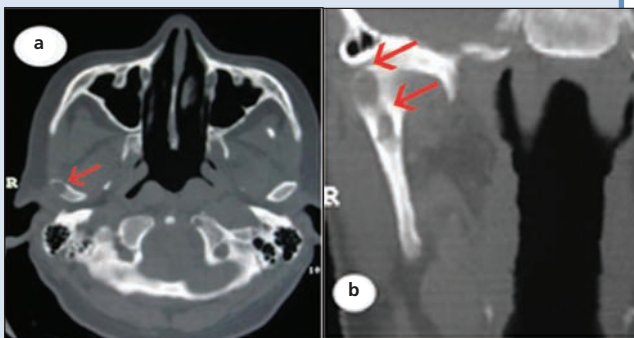


Figure 7: Axial (a) and coronal (b) CT scans showing the lesion in the right condyle.

We referred the patient to her primary care physician and consulted the oncology department about her case. We requested tests of function and an ultrasound of the thyroid, breast and abdomen, but the results showed no abnormality in these regions.

After further examination of the tomographic images, we realized that we had not detected the lesion in the right condyle. However, the patient complained of neither pain nor trismus, and had no complications from this lesion (Fig. 7).

Results of an immunohistochemical test done with the positive cytokeratin 7 marker to determine the histopathogenesis of the tumour in the retromolar region confirmed only the glandular epithelial origin of the tumour, but did not identify the primary site of the tumour. Tomographic images of the patient's chest and abdomen from a bone scan of the body done to find the organ of origin of the tumour identified metastatic foci in several ribs and vertebrae of the cervical spine.

Because of the evidence of widespread malignant disease, the patient's treatment was limited to palliation. At the end of February, the patient's condition became much worse. She had a pathologic fracture in the head of the right femur and was confined to bed for a few days. The patient's renal function worsened: she developed hypercalcemia, hyperkalemia and hyponatremia; her urea level was 99 mg/dL and her creatinine level was 5.1 mg/dL. As a result, she received palliative treatment appropriate for kidney failure. In the middle of March, 2 months after hospitalization and 4 months after the onset of the symptoms, the patient died.

Discussion

Metastasis, which is potentially inherent in any malignant tumour, most often involves regional lymph nodes rather than distant organs.³ Metastasis is the culmination of a multistage process in which malignant tumour cells colonize distant sites: after detaching themselves from the primary tumour, they move into the vascular or lymphatic vessels until they lodge in a capillary bed. Subsequently, the cells penetrate the blood vessel walls, invade surrounding tissues and proliferate within the recipient site.^{1,4} Metastasis may occur in the head and neck region by way of Batson's plexus, bypassing the filtering capabilities of the lungs. Most metastatic tumours of the maxillofacial region are from distant sites such as the lungs, liver and kidneys.^{1-6,8,10} These tumours occur more frequently in the jaw bones than in the oral soft tissues, and in persons in their fifth to seventh decade. The mean age (45 years) of patients with metastases to the jawbones is lower than that (54 years) of those with metastases to the oral soft tissues.¹ These metastases occur most often (82% to 85%) in the mandible,^{1,6,10} mostly in the molar region, followed

by the premolar region, but rarely in the condyle.^{1,5,8,10} Although metastasis of these tumours occurs with equal frequency in both sexes, it occurs in different regions of their bodies: the primary sites for metastasis to the oral and maxillofacial region for men are the lung, kidney and prostate gland, and for women, the breast, genital organs and kidneys.^{1,3,5,8} The exact location of the primary tumour is often difficult, sometimes impossible, to identify.^{1,5}

The number of metastases is an important factor in the treatment of malignant tumours that have metastasized to the oral and maxillofacial region.¹¹ If the primary lesion in the oral and maxillofacial region seems to be controlled and if other metastatic foci have been ruled out, surgical excision of the metastatic oral lesion is the preferred treatment if the patient's general health allows the procedure.¹¹ Investigations, such as bone scans, done after the detection of tumours of unknown origin that have foci in the maxillofacial region are very important because in 22% to 30% of cases metastasis of the head and neck may be the first sign of malignant disease.^{3,5,6} However, oral metastases are usually evidence of widespread disease and indicate a poor prognosis.^{1,10} The majority of patients die some months after the appearance of an oral lesion. Nonetheless, even in cases of advanced malignant disease, palliative treatment is necessary for the control of pain, bleeding and impairment of chewing to improve the patient's quality of life.¹

The clinical characteristics of the patient's case we report in this article concur with those presented in the literature about the metastasis of malignant tumours to the oral region from distant sites.^{1-5,13-15} The metastatic lesions found in our patient's maxillofacial region were located in the mandible, which is involved in 82% to 85% of such cases. More specifically, most of these lesions occur in the left molar region, and in the right condyle. The exact location of our patient's primary tumour could not be identified, as is typical of such cases. Also similar to the findings of the literature,¹ our patient's oral metastasis pointed to widespread disease and to a poor prognosis. In such cases, effective treatment is impossible because of the difficulty of delivering drugs only to the specific location of the tumour, the resistance of the tumour cells to antineoplastic drugs and the toxicity of these drugs, which is exacerbated by the patient's poor health. Only palliative therapy remains to minimize suffering. Our patient was treated palliatively and died 4 months after the appearance of the first symptoms of the disease. ✦

THE AUTHORS



Dr. Gomes is a senior lecturer in the department of oral and maxillofacial surgery, Pernambuco School of Dentistry, University of Pernambuco, Recife, Brazil.



Dr. P. Neto is an MSc student in the department of oral and maxillofacial surgery, University of São Paulo, Ribeirão Preto, Brazil.



Dr. Silva is a senior lecturer in the department of oral and maxillofacial surgery, Pernambuco School of Dentistry, University of Pernambuco, Recife, Brazil.



Dr. Sávio is a senior lecturer in the department of oral pathology, Pernambuco School of Dentistry, University of Pernambuco, Recife, Brazil.

Dr. I. Neto is an MSc student in the department of clinical dentistry, Federal University of Ceará, Fortaleza, Brazil.

Correspondence to: Dr. Patrício Neto, Service of oral and maxillofacial surgery, Oswaldo Cruz University Hospital, 310 Arnóbio Marques Street, 50100-130 Recife, Pernambuco, Brazil.

The authors have no declared financial interests.

This article has been peer reviewed.

References

- Hirshberg A, Buchner A. Metastatic tumours to the oral region — an overview. *Eur J Cancer B Oral Oncol* 1995; 31B(6):355–60.
- Vähätalo K, Ekfors T, Syrjänen S. Adenocarcinoma of the pancreas metastatic to the mandible. *J Oral Maxillofac Surg* 2000; 58(1):110–4.
- Scipio JE, Murti PR, Al-Bayaty HF, Matthews R, Scully C. Metastasis of breast carcinoma to mandibular gingiva. *Oral Oncol* 2001; 37(4):393–6.
- Vieira BJ, Aarestrup FA, da Fonseca EC, Dias EP. Bilateral gingival metastasis of lung adenocarcinoma: report of a case. *J Oral Maxillofac Surg* 2001; 59(10):1224–5.
- Fukuda M, Miyata M, Okabek K, Sakashita H. A case series of 9 tumors metastatic to the oral and maxillofacial region. *J Oral Maxillofac Surg* 2002; 60(8):942–4.
- Willard CC, Weber CR, Buche W. Metastatic esophageal adenocarcinoma involving the maxilla. *J Oral Maxillofac Surg* 2002; 60(12):1496–9.
- Smolka W, Brekenfeld C, Büchel P, Iizuka T. Metastatic adenocarcinoma of the temporomandibular joint from the cardia of the stomach: a case report. *Int J Oral Maxillofac Surg* 2004; 33(7):713–5.
- Lim SY, Kim SA, Ahn SG, Kim HK, Kim SG, Hwang HK, and others. Metastatic tumours to the jaws and oral soft tissues: a retrospective analysis of 41 Korean patients. *Int J Oral Maxillofac Surg* 2006; 35(5):412–5. Epub 2006 Feb 13.
- Jordan RC, Daniels TE, Greenspan JS, Regezi JA. Advanced diagnostic methods in oral and maxillofacial pathology. Part II: Immunohistochemical and immunofluorescent methods. *Oral Surg Oral Med Oral Pathol Oral Radiol Endod* 2002; 93(1):56–74.
- Miles BA, Schwartz-Dabney C, Sinn DP, Kessler HP. Bilateral metastatic breast adenocarcinoma within the temporomandibular joint: a case report. *J Oral Maxillofac Surg* 2006; 64(4):712–8.
- Hashizume A, Nakagawa Y, Nagashima H, Ishibashi K. Rectal adenocarcinoma metastatic to the masseter muscle. *J Oral Maxillofac Surg* 2000; 58(3):324–7.
- Pires FR, Sagarra R, Corrêa ME, Pereira CM, Vargas PA, Lopes MA. Oral metastasis of a hepatocellular carcinoma. *Oral Surg Oral Med Oral Pathol Oral Radiol Endod* 2004; 97(3):359–68.
- Rocha WC, Curado MP, Vêncio EF, Caixeta WB. Endometrial carcinoma metastatic to the mandible: a case report. *J Oral Maxillofac Surg* 2000; 58(8):914–6.
- Meneghini F, Castellani A, Camelin N, Zanetti U. Metastatic chordoma to the mandibular condyle: an anterior surgical approach. *J Oral Maxillofac Surg* 2002; 60(12):1489–93.
- Nakamura T, Ishimaru J, Mizui T, Kobayashi A, Toida M, Makita H, and others. Osteosarcoma metastatic to the mandible: a case report. *Oral Surg Oral Med Oral Pathol Oral Radiol Endod* 2001; 91(4):452–4.