

# Use of Porcelain Veneers, Crowns and an Implant to Resolve an Esthetic Problem

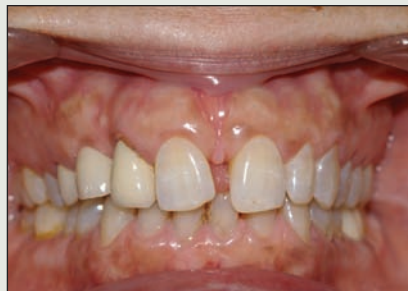Omar El-Mowafy, BDS, PhD, FADM

*“Clinical Showcase” is a series of pictorial essays that focus on the technical art of clinical dentistry. The section features step-by-step case demonstrations of clinical problems encountered in dental practice. If you would like to propose a case or recommend a clinician who could contribute to this section, contact editor-in-chief Dr. John O’Keefe at [jokeefe@cda-adc.ca](mailto:jokeefe@cda-adc.ca).*

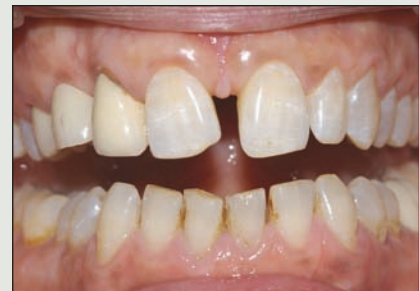A 51-year-old woman who worked as a company sales representative was concerned about the deteriorating condition of her anterior teeth. On presentation, the appearance of her anterior teeth was less than ideal, and she requested treatment to improve the situation. Her medical history was non-contributory, but intraoral examination revealed excessive diastema between the maxillary central incisors (Fig. 1). The maxillary right central incisor had an incisal edge fracture at the mesial side and appeared mesially tilted. The maxillary right lateral incisor was acting as an abutment for a fixed partial denture (FPD). The retainer on this tooth was out of ideal positioning, and its colour did not match that of the adjacent teeth, perhaps because of opacity of the underlying metallic core (Fig. 2). The maxillary

right canine was missing, and the pontic component of the 3-unit FPD that replaced it looked shorter than the lateral incisor and had a flattened incisal edge (Fig. 3). Further examination of the maxillary left anterior side revealed that the 3 anterior teeth were discoloured and the incisal edge of the central incisor was worn down at a slant (Fig. 4).

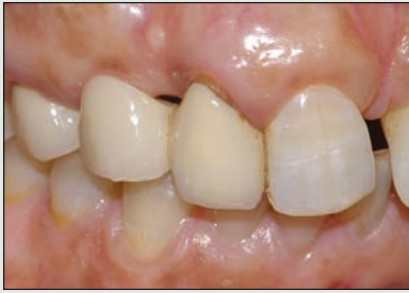Lingual examination revealed the unsightly appearance of the metallic framework of the 3-unit porcelain-fused-to-metal FPD (Fig. 5). Prior endodontic treatment of the maxillary lateral incisor had been performed through the FPD retainer and the access opening had been sealed with resin composite. Part of the veneering porcelain on the distal aspect of the premolar retainer had fractured, and the remaining anterior teeth had dark extrinsic staining.



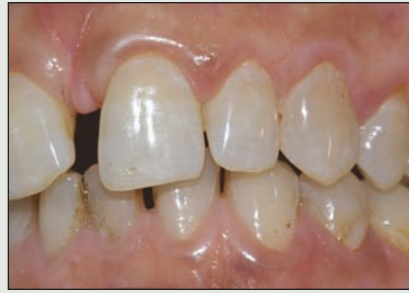**Figure 1:** Intraoral view of a 51-year-old woman shows excessive diastema between the maxillary central incisors. The maxillary right central incisor has an incisal fracture at the mesial side and appears mesially tilted. The maxillary right lateral incisor is acting as an abutment for a fixed partial denture (FPD).



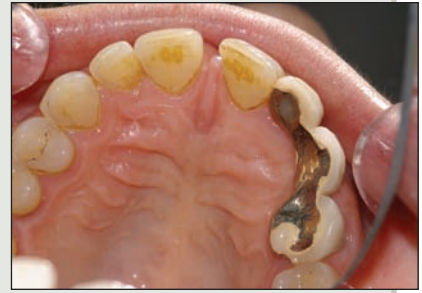**Figure 2:** The retainer on the maxillary right lateral incisor is out of ideal positioning, and the colour of the tooth does not match that of adjacent teeth. In the open position, the fracture on the incisal edge of the maxillary central incisor is more obvious. Staining of the lower incisors adds to the esthetic problem.



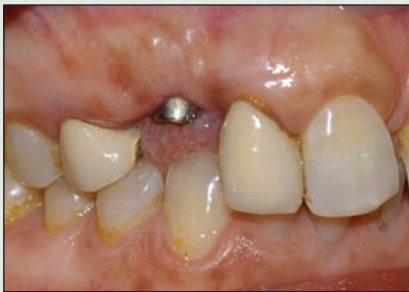**Figure 3:** Close-up view of the maxillary right side. The canine, which is the pontic part of a 3-unit FPD, appears significantly shorter than the lateral incisor and has a flattened incisal edge.



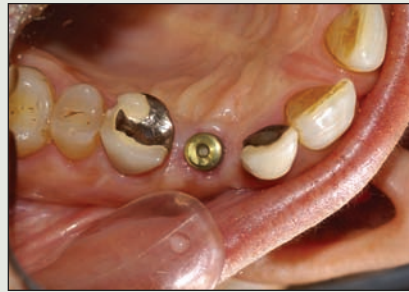**Figure 4:** Close-up view of the maxillary left anterior side. The teeth are discoloured, and the incisal edge of the central incisor is worn down at a slant.



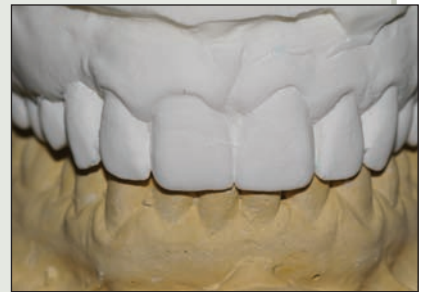**Figure 5:** Lingual view of the maxillary anterior area. The lingual aspect of the 3-unit FPD shows the unsightly appearance of the metallic framework. Prior endodontic treatment of the maxillary lateral incisor had been performed through the FPD retainer, and the access opening had been sealed with resin composite. In addition, part of the veneering porcelain on the distal aspect of the retainer on the first premolar had fractured.



**Figure 6:** The pontic of the FPD was severed, and an implant was inserted into the space. This view shows the healing cap.



**Figure 7:** The retainers of the FPD were left in place on the maxillary lateral incisor and the first premolar throughout the healing period for the inserted implant.



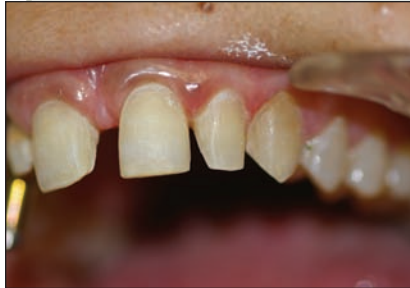**Figure 8:** A diagnostic wax-up was made and duplicated in stone. The duplicate stone model was used for fabrication of a clear matrix with a vacuum moulding machine.

The patient reported dissatisfaction with the FPD, both in terms of its appearance and because she was unable to properly floss between the teeth. Although the diastema between the 2 maxillary central incisors had been present for many years, she had noticed that her teeth were drifting, the diastema was increasing in size and the colour of the teeth was becoming darker.

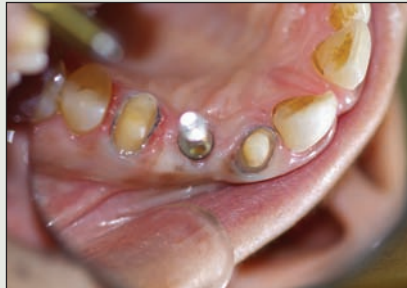Because the patient had full posterior support without edentulous spaces in the posterior region, the drifting of the anterior teeth was most likely due to the congenital absence of tooth 13, the large diastema between the 2 central incisors and the patient's age.

### Treatment Plan

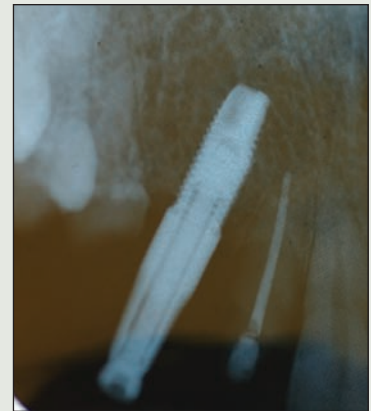
After study models had been prepared and radiographic images of the anterior teeth and digital intraoral photographs had been examined, a treatment plan was designed to address the patient's concerns. Various treatment approaches were considered, including one that would have involved orthodontic movement of the anterior teeth with a fixed appliance; however, the patient was more interested in alternative approaches that would be less time-consuming. The one she selected involved removal of the existing 3-unit FPD and replacement with an implant-supported porcelain crown in the maxillary right canine location. The current



**Figure 9:** Four maxillary anterior teeth were prepared to receive porcelain veneers.



**Figure 10:** At the impression-taking stage, the implant healing cap was removed and the transfer coping secured in place. A retraction cord was placed in the sulci of the other prepared teeth.



**Figure 11:** A periapical radiograph was obtained to ensure that the transfer coping had been properly seated onto the implant before the impression was taken.

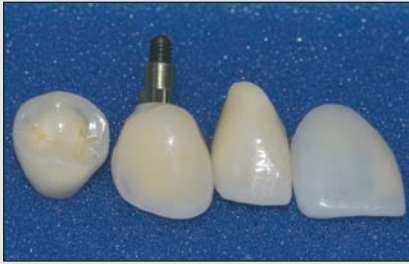high success rate of implants warrants their use for routine clinical conditions, such as this one.<sup>1</sup> Under the treatment plan, both the maxillary right lateral incisor and the maxillary first premolar, which had originally acted as abutments for the FPD with porcelain-fused-to-metal retainers, were to receive all-porcelain crowns. Reported success rates for this type of crown in the anterior region of the mouth have been high.<sup>2-4</sup> The remaining anterior teeth were to receive porcelain veneers to close the diastema between the 2 central incisors, to correct the alignment and shape of the 2 central incisors, and to ensure uniform colour for all of the anterior teeth. The technique for applying porcelain veneer was originally introduced by Dr. John Calamia in 1985 and has yielded reliable and long-lasting results.<sup>5</sup>

The periodontal health of the involved teeth was within normal limits, except for the maxillary right lateral incisor, which had suffered some bone loss and had increased periodontal pocket depth. However, the results of previous endodontic treatment of this tooth were satisfactory and stable. The patient was informed of the periodontal condition of this tooth and was told that if its condition deteriorated to the point that extraction was warranted, the implant-supported crown that was to be made for the tooth 13 location could later be replaced with a cantilevered FPD supported on the same implant and replacing both teeth 12 and 13.

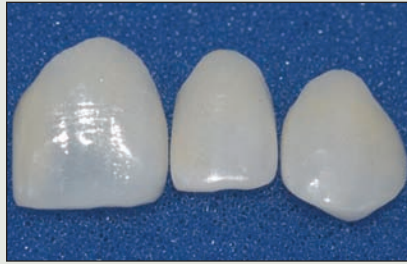### Treatment Phase

The FPD pontic was severed, and an implant (NobelReplace Straight Groovy, Nobel Biocare, Gothenburg, Sweden) was inserted into the maxillary right canine location (Figs. 6 and 7). After healing was complete, a new maxillary stone model was made and a diagnostic wax-up constructed. The diagnostic wax-up was then duplicated in stone (Fig. 8). This stone model was used to show the patient the expected final shape of the teeth. It was also used for fabrication of a matrix to be used for making provisional restorations.

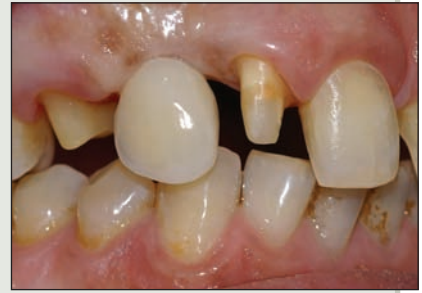Following successful osseointegration of the implant, the FPD retainers on the maxillary right lateral incisor and the first premolar were removed. These 2 teeth were re-prepared to receive porcelain crowns, and the maxillary left central and lateral incisors and the maxillary left canine were prepared to receive porcelain veneers (Fig. 9). The healing cap was removed from the implant and a matching transfer coping was placed. A retraction cord was placed into the gingival sulci of the other prepared teeth to expose the preparation margins for accurate impression-taking (Fig. 10). A radiograph was obtained to ensure proper seating of the transfer coping onto the implant (Fig. 11). An impression was taken in a silicon material using the closed-tray technique, after which ceramic crowns with zirconium oxide cores and matching veneering porcelain were made for the lateral incisor



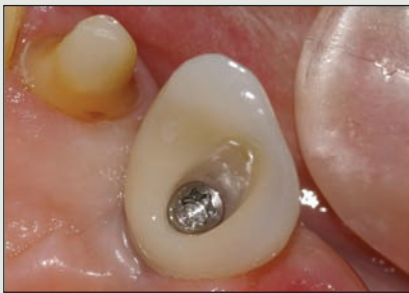**Figure 12:** Two ceramic crowns and an implant-supported crown and porcelain veneer for the right maxillary central and lateral incisors, canine and first premolar. The difference in colour between the veneer and the crowns relates to the minimal thickness of the veneer.



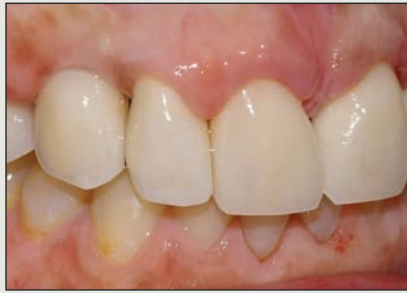**Figure 13:** Porcelain veneers for the maxillary left central and lateral incisors and the left maxillary canine.



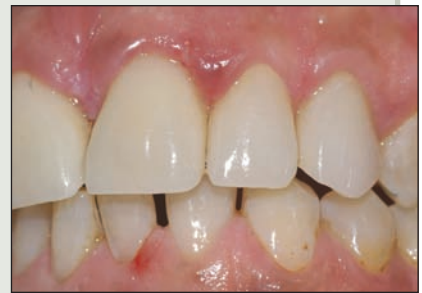**Figure 14:** The implant-supported crown was the first to be inserted.



**Figure 15:** The implant screw was torqued with a manual torque wrench before the opening was closed with a composite resin.



**Figure 16:** The ceramic crowns of the maxillary lateral incisor and first premolar were cemented with a resin cement. Restoration of the anatomic features of the teeth, as shown here, is key to achieving a natural, pleasing smile.

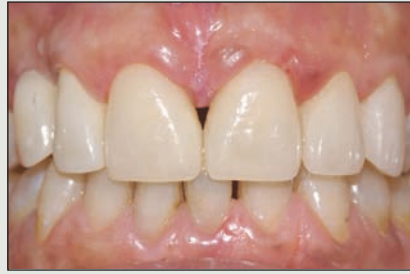

**Figure 17:** An appropriate shade of resin cement was selected and used to secure the 4 porcelain veneers.

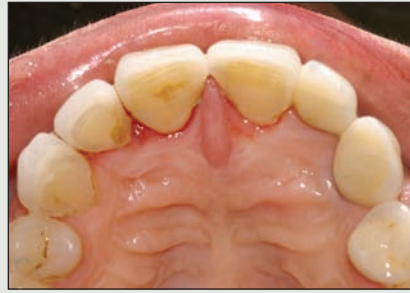and the first premolar (Procera Crown Zirconia, Nobel Biocare) (Fig. 12). An implant abutment made of zirconium oxide and matching the size of the inserted implant was veneered with matching porcelain (Procera Abutments, Nobel Biocare). For the remaining 4 prepared teeth, porcelain veneers were fabricated using matching feldspathic porcelain (Fig. 13).

The implant-supported crown was the first restoration to be inserted (Fig. 14). After the crown was secured with a manual wrench, a radiograph was taken to ensure proper seating. The screw was then torqued to 35 N with a manual torque wrench (Nobel Biocare) (Fig. 15). The access hole was then sealed with a composite resin. The remaining 2 ceramic crowns were cemented with a dual-cured self-adhesive resin cement (Breeze, Pentron, Wallingford, Conn.) (Fig. 16), the ce-

ment of choice for ceramic restorations.<sup>6,7</sup> It was important to insert the 3 crowns first so that the final colour of all restorations could be established. The colour of the porcelain veneers could then be matched to the colour of the crowns by choosing an appropriate shade of resin cement (Fig. 17). A postoperative facial view (Fig. 18) shows how the colour of the veneers blends nicely with the colour of the crowns. The dimensional relation between the right central and lateral incisors is now ideal, the lateral tooth being shorter by 2 mm than the central incisor, unlike the preoperative situation (see Fig. 1), in which the 2 teeth were at the same level. However, it was impossible to completely close the diastema because of the excessive space between the 2 central incisors. Attempting to completely close the space would have made these 2 teeth appear wide, short and artificial. A lingual



**Figure 18:** Immediate postoperative view. The colour of the veneers blends nicely with that of the crowns. This match was achieved by selecting the most appropriate shade of resin cement.



**Figure 19:** Lingual view of the maxillary anterior region. The appearance of the right side has been improved dramatically by using 3 crowns to replace the porcelain-fused-to-metal FPD.

postoperative view (**Fig. 19**) shows a dramatic improvement in the appearance of the teeth on the right side after replacement of the conventional porcelain-fused-to-metal FPD with 3 crowns.

### Conclusion

An esthetic problem created by several clinical conditions (namely, excessive diastema, tooth drifting, rotation, discoloration and failure of an FPD) was resolved by strategic use of esthetic non-metallic porcelain-and-ceramic restorations and one implant-supported crown. ✦

### THE AUTHOR



*Dr. El-Mowafy is a professor in restorative dentistry in the department of clinical dental sciences, faculty of dentistry, University of Toronto, Ontario.*

**Correspondence to:** Dr. Omar El-Mowafy, Department of clinical dental sciences, Faculty of dentistry, University of Toronto, 124 Edward St., Toronto, ON M5G 1G6. Email: [oel.mowafy@utoronto.ca](mailto:oel.mowafy@utoronto.ca)

*The author has no declared financial interests in any company manufacturing the types of products mentioned in this article.*

### References

1. Callan DP, Hahn J, Hebel K, Kwong-Hing A, Smiler D, Vassos DM, and others. Retrospective multicenter study of an anodized, tapered, diminishing thread implant: success rate at exposure. *Implant Dent* 2000; 9(4):329–36.
2. Odén A, Andersson M, Krystek-Ondracek I, Magnusson D. Five-year clinical evaluation of Procera AllCeram crowns. *J Prosthet Dent* 1998; 80(4):450–6.
3. Fradeani M, D'Amelio M, Redemagni M, Corrado M. Five-year follow-up with Procera all-ceramic crowns. *Quintessence Int* 2005; 36(2):105–13.
4. Zitzmann NU, Galindo ML, Hagmann E, Marinello CP. Clinical evaluation of Procera AllCeram crowns in the anterior and posterior regions. *Int J Prosthodont* 2007; 20(3):239–41.
5. Calamia JR. Etched porcelain veneers: the current state of the art. *Quintessence Int* 1985; 16(1):5–12.
6. El-Mowafy OM. The use of both porcelain veneers and all-porcelain crowns in restoring anterior teeth. [Clinical Showcase] *J Can Dent Assoc* 2006; 72(9):803–6.
7. El-Mowafy OM, Rubo MH, El-Badrawy WA. Hardening of new resin cements cured through ceramic inlay. *Oper Dent* 1999; 24(1):38–44.