

# Re-eruption of an Intruded Immature Permanent Incisor with Necrotic Pulp: A Case Report

**Ceyhan Altun, DDS, PhD; Günseli Güven, DDS, PhD; Zafer C. Cehreli, DDS, PhD; Taskin Gurbuz, DDS, PhD; Cumhuri Aydin, DDS, PhD**

## Contact Author

Dr. Altun  
Email: [ceyhantun@yahoo.com](mailto:ceyhantun@yahoo.com)



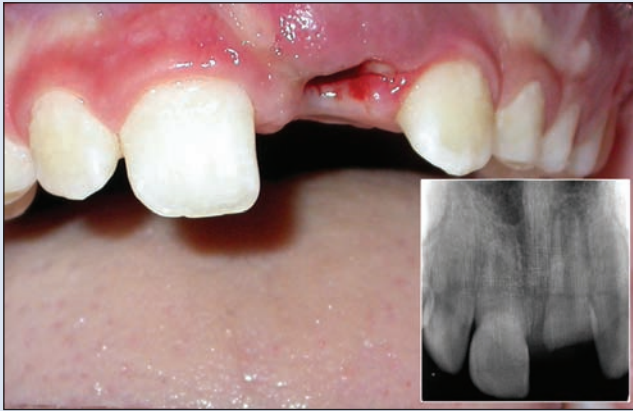
## ABSTRACT

Intrusive luxation is a serious dental injury that causes damage to the pulp and supporting structures of a tooth because of its dislocation into the alveolar process. This paper presents the case of the re-eruption of a severely intruded immature permanent incisor with a crown-root fracture. A 9-year-old boy was referred to the clinic 1 day after a fall. Clinical and radiographic examinations revealed intrusive luxation of the immature left permanent incisor and a crown-root fracture without pulp exposure. Palatal gingivectomy was done 2 weeks later to facilitate re-eruption. Root canal therapy with intracanal calcium hydroxide paste was initiated during the first month owing to severe spontaneous pain. Six months later, the tooth re-erupted to a normal position, after which root canal obturation and a final esthetic restoration were done. The present case demonstrates the possibility of obtaining re-eruption of intruded immature permanent teeth with interim medication (calcium hydroxide) in the root canal.

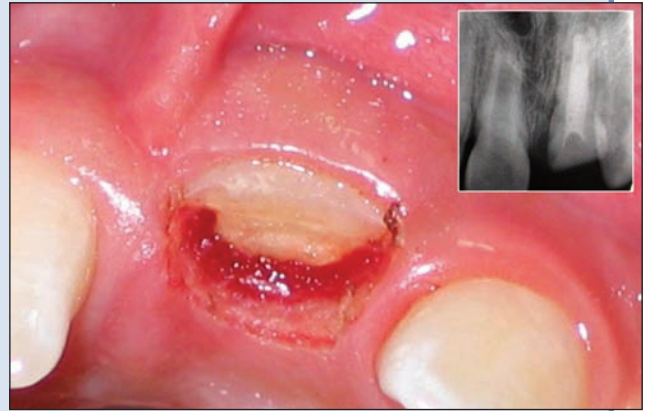
For citation purposes, the electronic version is the definitive version of this article: [www.cda-adc.ca/jcda/vol-74/issue-6/545.html](http://www.cda-adc.ca/jcda/vol-74/issue-6/545.html)

Intrusion is a type of trauma that involves axial displacement of a tooth toward the alveolar bone. More properly named intrusive luxation, it usually affects the anterior teeth and is often associated with an impacted fracture of the alveolar bone.<sup>1</sup> Intrusive luxation is one of the most severe forms of traumatic injuries. Its low incidence (only 3% of all luxation injuries to permanent incisors<sup>1</sup> and 5%–12% of dental luxations<sup>2,3</sup>) suggests that clinicians may have little experience with the diagnosis and treatment of this type of injury.<sup>4,5</sup> During intrusive luxation, serious damage to the pulp and supporting structures occurs because of the dislocation of the tooth into the alveolar process. As a consequence, pulp necrosis, radicular inflammatory resorption, replacement root resorption, loss of marginal bone support and gingival retraction may occur.<sup>1,6,7</sup>

Currently, consensus about the best approach to bring intruded teeth back to their normal position is lacking. Depending on the severity of the injury, treatment strategies include waiting for spontaneous re-eruption, surgical repositioning or repositioning with traction.<sup>6,8–10</sup> Waiting for spontaneous re-eruption is especially indicated for immature permanent teeth with mild intrusion (less than 3 mm), because of their high potential for eruption and pulpal or periodontal repair.<sup>1,8</sup> In cases of moderate intrusion (3–6 mm) with incomplete apex, teeth may re-erupt, or alternatively, these teeth may be orthodontically repositioned. Finally, in severely intruded teeth (greater than 6 mm), often the soft tissue is severely displaced and the crown may be completely buried, making orthodontic repositioning difficult or impossible. Consideration should be given to



**Figure 1:** Intraoral view of the patient 1 day after the trauma. The radiograph (inset) reveals the extent of intrusion and the immature root apex.



**Figure 2:** Clinical appearance of the gingiva after palatal gingivectomy. Note that the tooth has been dislodged labially. Endodontic therapy was initiated with intracanal calcium hydroxide 2 weeks after gingivectomy (inset).

surgically repositioning the tooth, regardless of the stage of root development.<sup>11</sup>

The reported incidence of pulp necrosis for intruded teeth with open apices is not low (63%–68%).<sup>6,12</sup> In such cases, removal of the necrotic pulp is mandatory because it can stimulate external inflammatory root resorption,<sup>13</sup> which in turn may jeopardize the spontaneous re-eruption of the tooth.

This care report describes the management of a severely intruded immature permanent incisor with a crown-root fracture whose re-eruption was observed after gingivectomy and pulpectomy, both of which were done before the incisor had returned to its position before the injury.

### Case Report

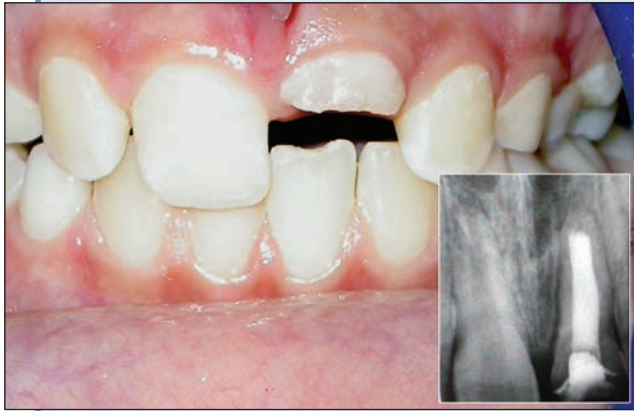A healthy 9-year-old boy was referred to the pediatric dentistry clinic with a fractured maxillary left central incisor. Reportedly, he had fallen in the schoolyard a day before and traumatized his front tooth. Immediately after the accident, the child was taken to a hospital emergency unit where the possibility of trauma to the cranial structures and neck was eliminated. The patient was conscious and did not report any pain.

An intraoral examination revealed a fractured maxillary left permanent incisor with the distal aspect of the crown slightly visible from the frontal aspect (**Fig. 1**). The neighbouring teeth were free from any clinical symptoms. A periapical radiograph of the tooth showed that the apex of the root of the fractured incisor was immature and that the tooth had intruded at least 3 mm into the alveolar bone (**Fig. 1**). Although the radiographic level of the coronal fracture line suggested no

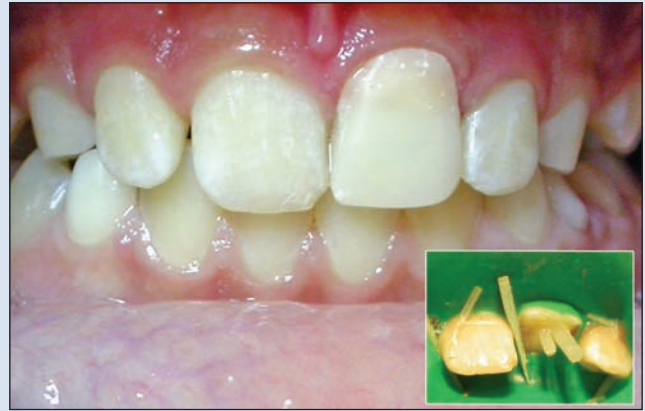traumatic exposure of the pulp, this finding could not be confirmed clinically because the slightly inflamed edematous gingiva covered the palatal aspect of the tooth's crown. The treatment plan comprised prescribing antibiotics and analgesics, and a mouth rinse containing 0.12% chlorhexidine gluconate for 1 week, and following the patient until the possible re-eruption of the tooth.

Evidence of gingival healing was observed 15 days later. However, the palatal aspect of the fractured crown of the tooth was still covered with a thick layer of gingival tissue. Because this tissue might interfere with the re-eruption of the tooth, gingivectomy was done on the palatal side under local anesthesia (**Fig. 2**). Surgical exposure of the palatal aspect of the crown of the tooth showed that the fracture line extended about 1.5 mm below the cemento-enamel junction; the pulp was not visibly exposed. However, the exposed dentin could not be sealed temporarily because it could not be properly isolated. Two weeks later, the patient complained of frequent episodes of spontaneous pain that he had not been able to relieve with analgesics over the previous 7 days. Clinically, the tooth was extremely sensitive to percussion tests, but no radiographic signs of infection (e.g., periapical radiolucency, root resorption) were found. Although a pulp test was not considered reliable in this situation, the tooth did not respond to a thermal pulp test. Endodontic therapy was initiated with intracanal calcium hydroxide paste (**Fig. 2**), and the patient was scheduled for monthly recalls.

During the 6-month recall appointment, the clinician decided to induce a complete re-eruption of the tooth after comparing the radiographic levels of the root apices (**Fig. 3**). The relatively higher gingival level of the



**Figure 3:** Intraoral view of the incisor 6 months after the trauma. Note the extent of re-eruption. Inset: Radiographic view of the obturated root revealing apical closure and no resorption of the root.



**Figure 4:** Final esthetic result of the coronal restoration after the application of a glass-fibre-reinforced composite root canal post (inset).

traumatized incisor was thought to be the result of re-eruption of the tooth in the labial direction, which first occurred after gingival healing, and thereafter after palatal gingivectomy (**Fig. 2**). Presumably, the trauma slightly dislodged the root in the labial direction, and over time, the attached gingival line followed the labial re-eruption pattern of the crown, ending up higher than the right central incisor. Since the extent of orthodontic force required to correct the root inclination could initiate root resorption, the treatment plan comprised root canal treatment and a coronal restoration, followed by orthodontic treatment at a later stage.

After removal of the calcium hydroxide, the root canal was obturated with vertically compacted gutta-percha (Dentsply Maillefer, Ballaigues, Switzerland) and a calcium hydroxide-based sealer (Sealapex, Sybron/Kerr, Guarulhos, SP, Brazil) (**Fig. 3**), and coronal access was temporarily restored with resin-modified glass ionomer cement (Vitremer, 3M/ESPE, Seefeld, Germany). One week later, the middle and coronal thirds of the root canal filling were removed with Gates Glidden drills (Produits Dentaires S.A., Vevey, Switzerland) to prepare a space for an intracanal post. After the coronal aspect of the tooth was conditioned with 37% phosphoric acid for 20 seconds and rinsed with an air-water spray for 20 seconds, the etched surfaces were gently air-dried, and a water-based adhesive resin (Excite DSC, Ivoclar Vivadent AG, Schaan, Liechtenstein) was placed in the root canal, according to the manufacturer's instructions. A glass-fibre-reinforced composite root canal post (FRC Postec, Ivoclar Vivadent AG) was then placed in the canal, in conjunction with a dual-cure luting composite system (Variolink II, Ivoclar Vivadent AG) (**Fig. 4**). Final coronal restoration of the

fractured crown was made with a resin composite material (Tetric Ceram, Ivoclar Vivadent AG) (**Fig. 4**).

## Discussion

Although the incidence of pulp necrosis after intrusion of immature permanent incisors is less than that of mature permanent teeth, it is not uncommon.<sup>6,12</sup> Pulpal necrosis may occur as early as weeks to months after intrusion, or as late as 2 years after the trauma.<sup>6</sup> In cases of severe intrusion with early signs of pulpal involvement, endodontic access should not be impeded at the expense of waiting for passive repositioning because predictable time-dependent sequelae, including formation of abscesses or inflammatory root resorption, may develop.<sup>10,13</sup> To overcome the difficulty of gaining access to the root canal because of severe intrusion, Shapira and others<sup>8</sup> and Tronstad and others<sup>14</sup> recommend gingivectomy to uncover the crown while the tooth is still intruded in the alveolar bone. They suggest initiating endodontic treatment while waiting for re-eruption. They observed that after gingivectomy and root canal treatment with a calcium hydroxide-based material, both mature and immature teeth showed a considerable increase in the speed of re-eruption and returned to their normal positions in 3 to 7 months. In the current case, gingivectomy was not done primarily to gain endodontic access because the tooth seemed to be vital 15 days after the trauma. Rather, gingivectomy was done to remove the palatal gingival tissue that seemingly interfered with the re-eruption of the tooth and to seal the dentin surface. However, even after gingivectomy, the exposed dentin surface could not be covered temporarily because of difficulty isolating it properly. In intruded teeth, pulp

necrosis is significantly related to crown fractures with exposed dentin. The exposed dentin may allow bacterial invasion and subsequent development of pulp necrosis,<sup>1</sup> which could be responsible for the later signs of irreversible pulpal involvement (at 1 month) observed in this case.

The endodontic treatment of immature anterior teeth after trauma remains complicated because of large open apices, divergent root walls, thin dentinal walls and frequent periapical lesions.<sup>15</sup> Apexification with calcium hydroxide is well documented<sup>16,17</sup> and is the most widespread technique<sup>18,19</sup> used to stimulate a hard-tissue deposition (a calcified barrier) at the apex against which a 3-dimensional root canal filling can be supported. The basic pH of calcium hydroxide seems to be antibacterial and to accelerate healing of the periapical tissues.<sup>20</sup> Results of recent investigations,<sup>21–23</sup> however, indicate that apexification with mineral trioxide aggregate (MTA) and apical sealing may be a better alternative. In the current case, MTA could not be used because it was not available at our clinic.

In the current case, glass-fibre-reinforced composite root canal posts were put into the canal after partial removal of the gutta-percha filling. Restoration of endodontically treated teeth is challenging, especially when the teeth are weakened, root canals are compromised, and open apices, fractures or internal resorption occur.<sup>24</sup> These flared root canals with relatively thin dentin walls may require reinforcement and restoration with dentin bonding agents and composite, posts and cores.<sup>25,26</sup> Direct post and core restorations with prefabricated fibre-reinforced resin posts have become popular because they have a lower modulus of elasticity than metal posts.<sup>27</sup> This advantage may not provide better fracture resistance of the root than that achieved with cast posts,<sup>24</sup> but roots restored with fibre-reinforced resin posts are capable of withstanding masticatory forces generated by young patients,<sup>28</sup> and unlike cast posts, which transfer the applied stress directly to the root,<sup>29</sup> root fractures after treatment can be repaired.<sup>24</sup>

Replacement root resorption may occur when severely intruded incisors are positioned with traction forces.<sup>30–32</sup> In the current case, traction was deemed unnecessary because of the potential for the re-eruption of the immature tooth. However, because of the traumatic displacement of the tooth in the labial direction, re-eruption caused the gingival level of the traumatized tooth to appear slightly higher than that of the contralateral incisor because the orthodontic repositioning began at a later stage. The assessment that full re-eruption of the left central incisor had taken place was based on a comparison of the position of the root tips of the 2 central incisors. Alternatively, tooth 21 may not have fully re-erupted because the tooth was immature at the time of the trauma and may not have attained its full root length after pulp necrosis.

## Conclusion

The current case demonstrates and confirms the possibility that intruded incisors without a vital pulp may re-erupt, provided that endodontic therapy is initiated in a timely manner. Endodontic therapy, however, does not guarantee re-eruption. Re-positioning the intruded tooth may require the use of orthodontic traction forces. ✦

## THE AUTHORS



*Dr. Altun is an assistant professor in the department of pediatric dentistry, Center for Dental Sciences, Gülhane Medical Academy, Ankara, Turkey.*



*Dr. Güven is an associate professor in the department of pediatric dentistry, Center for Dental Sciences, Gülhane Medical Academy, Ankara, Turkey.*



*Dr. Gurbuz is an assistant professor in the department of pediatric dentistry, Center for Dental Sciences, Gülhane Medical Academy, Ankara, Turkey.*



*Dr. Aydin is an assistant professor in the department of endodontics and conservative treatment, Center for Dental Sciences, Gülhane Medical Academy, Ankara, Turkey.*



*Dr. Cehreli is an associate professor in the department of pediatric dentistry, faculty of dentistry, Hacettepe University, Ankara, Turkey.*

**Correspondence to:** Dr. Ceyhan Altun, Department of pediatric dentistry, Center for Dental Science, Gulhane Medical Academy, Etlik/Ankara, Turkey.

*The authors have no declared financial interests in any company manufacturing the types of products mentioned in this article.*

*This article has been peer reviewed.*

## References

- Andreasen JO, Andreasen FM, Andersson L. Textbook and color atlas of traumatic injuries to the teeth. 4th ed. Copenhagen: Munksgaard; 2007.
- Andreasen JO. Etiology and pathogenesis of traumatic dental injuries. A clinical study of 1,298 cases. *Scand J Dent Res* 1970; 78(4):329–42.
- Zerman N, Cavalleri G. Traumatic injuries to permanent incisors. *Endod Dent Traumatol* 1993; 9(2):61–4.
- Andreasen JO, Ravn JJ. Epidemiology of traumatic dental injuries to primary and permanent teeth in a Danish population sample. *Int J Oral Surg* 1972; 1(5):235–9.
- Meadow D, Lindner G, Needleman H. Oral trauma in children. *Pediatr Dent* 1984; 6(4):248–51.
- Andreasen FM, Pedersen BV. Prognosis of luxated permanent teeth — the development of pulp necrosis. *Endod Dent Traumatol* 1985; 1(6):207–20.
- Chan AW, Cheung GS, Ho MW. Different treatment outcomes of two intruded permanent incisors — a case report. *Dent Traumatol* 2001; 17(6):275–80.
- Shapira J, Regev L, Liebfeld H. Re-eruption of completely intruded immature permanent incisors. *Endod Dent Traumatol* 1986; 2(3):113–6.

9. Turley PK, Crawford LB, Carrington KW. Traumatically intruded teeth. *Angle Orthod* 1987; 57(3):234–44.
10. GÜngör HC, Cengiz SB, Altay N. Immediate surgical repositioning following intrusive luxation: a case report and review of the literature. *Dent Traumatol* 2006; 22(6):340–4.
11. Kinirons MJ. Treatment of traumatically intruded permanent incisor teeth in children. UK National Clinical Guidelines in Paediatric Dentistry. *Int J Paediatr Dent* 1998; 8:165–8.
12. Andreasen JO. Luxation of permanent teeth due to trauma. A clinical and radiographic follow-up study of 189 injured teeth. *Scand J Dent Res* 1970; 78(3):273–86.
13. Kenny DJ, Barrett EJ, Casas MJ. Avulsions and intrusions: the controversial displacement injuries. *J Can Dent Assoc* 2003; 69(5):308–13.
14. Tronstad L, Trope M, Bank M, Barnett F. Surgical access for endodontic treatment of intruded teeth. *Endod Dent Traumatol* 1986; 2(2):75–8.
15. Duprez JP, Bouvier D, Bittar E. Infected immature teeth treated with surgical endodontic treatment and root-reinforcing technique with glass ionomer cement. *Dent Traumatol* 2004; 20(4):233–40.
16. Frank AL. Therapy for the divergent pulpless tooth by continued apical formation. *J Am Dent Assoc* 1966; 72(1):87–93.
17. Heithersay GS. Stimulation of root formation in incompletely developed pulpless teeth. *Oral Surg Oral Med Oral Pathol* 1970; 29(4):620–30.
18. Mandel E, Bourguignon-Adelle C. Endodontic retreatment: a rational approach to non-surgical root canal therapy of immature teeth. *Endod Dent Traumatol* 1996; 12(5):246–53.
19. Walia T, Chawla HS, Gauba K. Management of wide open apices in non-vital permanent teeth with Ca(OH)<sub>2</sub> paste. *J Clin Pediatr Dent* 2000; 25(1):51–6.
20. Klein SH, Levy BA. Histologic evaluation of induced apical closure of a human pulpless tooth. Report of a case. *Oral Surg Oral Med Oral Pathol* 1974; 38(6):954–9.
21. El-Meligy OA, Avery DR. Comparison of apexification with mineral trioxide aggregate and calcium hydroxide. *Pediatr Dent* 2006; 28(3):248–53.
22. Simon S, Rilliard F, Berdal A, Machtou P. The use of mineral trioxide aggregate in one-visit apexification treatment: a prospective study. *Int Endod J* 2007; 40(3):186–97.
23. Martin RL, Monticelli F, Brackett WW, Loushine RJ, Rockman RA, Ferrari M, and others. Sealing properties of mineral trioxide aggregate orthograde apical plugs and root fillings in an in vitro apexification model. *J Endod* 2007; 33(3):272–5. Epub 2007 Jan 4.
24. Maccari PC, Cosme DC, Oshima HM, Burnett LH Jr, Shinkai RS. Fracture strength of endodontically treated teeth with flared root canals and restored with different post systems. *J Esthet Restor Dent* 2007; 19(1):30–6.
25. Tait CM, Ricketts DN, Higgins AJ. Weakened anterior roots — intraradicular rehabilitation. *Br Dent J* 2005; 198(10):609–17.
26. Yoldas O, Akova T, Uysal H. An experimental analysis of stresses in simulated flared root canals subjected to various post-core applications. *J Oral Rehabil* 2005; 32(6):427–32.
27. Boudrias P, Sakkal S, Petrova Y. Anatomical post design meets quartz fiber technology: rationale and case report. *Compend Contin Educ Dent* 2001; 22(4):337–40, 342, 344 passim.
28. Ferrario VF, Sforza C, Serrao G, Dellavia C, Tartaglia GM. Single tooth bite forces in healthy young adults. *J Oral Rehabil* 2004; 31(1):18–22.
29. Fokkinga WA, Kreulen CM, Vallittu PK, Creugers NH. A structured analysis of in vitro failure loads and failure modes of fiber, metal, and ceramic post-and-core systems. *Int J Prosthodont* 2004; 17(4):476–82.
30. Humphrey JM, Kenny DJ, Barrett EJ. Clinical outcomes for permanent incisor luxations in a pediatric population. I. Intrusions. *Dent Traumatol* 2003; 19(5):266–73.
31. Alves LD, Donnelly JC, Lugo A, Carter DR. Reeruption and extrusion of a traumatically intruded immature permanent incisor: case report. *J Endod* 1997; 23(4):246–8.
32. Frank CA, Long M. Periodontal concerns associated with the orthodontic treatment of impacted teeth. *Am J Orthod Dentofacial Orthop* 2002; 121(6):639–49.