

# Functional Esthetic Restoration with Direct Composite Resin

Bruce Kleeberger, BSc, DDS

*“Clinical Showcase” is a series of pictorial essays that focus on the technical art of clinical dentistry. The section features step-by-step case demonstrations of clinical problems encountered in dental practice. If you would like to propose a case or recommend a clinician who could contribute to this section, contact editor-in-chief Dr. John O’Keefe at [jokeefe@cda-adc.ca](mailto:jokeefe@cda-adc.ca).*

The introduction of hybrid-resin restorative materials with lifelike shades and a range of opacities provides the clinician with an excellent tool for the conservative restoration of teeth. The techniques for using these hybrid composites were initially taught in hands-on programs<sup>1</sup> and have been refined over time.<sup>2,3</sup> These composite resins contain quartz particles of various sizes in a resin matrix. They have adequate compressive, tensile and flexural strength, as well as resistance to wear, and can be polished to a degree that mimics natural teeth.

This article describes a technique for restoring 8 anterior teeth to a lifelike contour, texture and shade. This technique, which uses a single hybrid composite, is simpler than techniques using multiple materials with different shades.

## Case Report

### History

The patient, who was 33 years old, attended the dental office with a specific

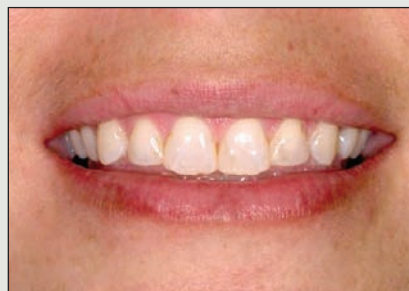request to replace existing composite restorations bonded to her maxillary incisors. These restorations had been placed 15 years previously, to close diastemas. At the time of the current presentation, she wanted her teeth to be made longer and whiter. Overall, her dental restorative experience was minimal, and she was not aware of any parafunctional dental habits.

### Diagnosis

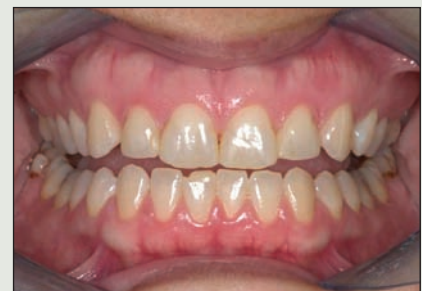Complete records and materials were procured, including the medical and dental history, radiographs, mounted study models and photographs (Figs. 1–3), and a thorough dental examination was performed. Flowable composite was added to the incisal edges of the teeth to allow the patient to evaluate the outcome of the proposed lengthening procedures. The lengthened teeth were assessed phonetically.<sup>6</sup> The patient was satisfied with function and esthetics, and the result was recorded in an impression.



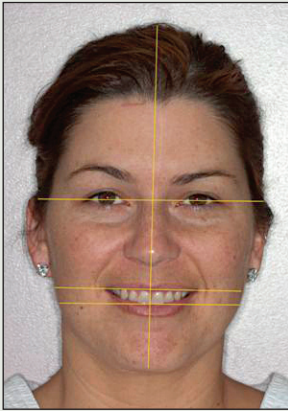
**Figure 1:** Full-face photograph of the 33-year-old patient before treatment.



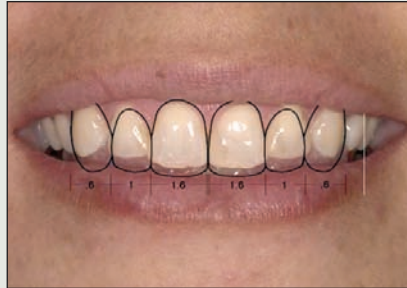**Figure 2:** Patient's smile before treatment, showing worn incisal edges and discoloration of the 15-year-old composite restorations.



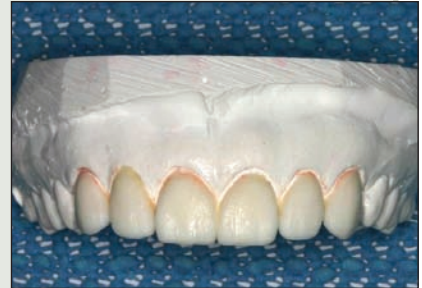**Figure 3:** Retracted view of the teeth before treatment, showing soft-tissue health and contours.



**Figure 4:** Grid analysis system applied to the preoperative full-face photograph.



**Figure 5:** The “golden proportion” superimposed on the preoperative smile photograph.



**Figure 6:** Wax-up prepared for diagnosis, based on an intraoral preoperative photograph of the mock-up and mounted models supplied to the laboratory.

The clinical examination revealed noncontributory features from the dental and medical histories, healthy soft and hard tissues, and mild, age-appropriate wear of the dentition. The temporomandibular joints were healthy, and the muscles were asymptomatic upon palpation. Periodontal health was excellent throughout the mouth.

A “smile analysis” was undertaken using the available records and materials. The grid analysis system, as proposed by Naylor,<sup>5</sup> was used. With this system, the proportion and orientation of the esthetic zone of the teeth is related to the face and the gingival display. It is also used to assess tooth length and width (Fig. 4). The teeth were also assessed for adherence to the “golden proportion,” as summarized by Mancuso<sup>6</sup> and demonstrated in Fig. 5. As well, study models were mounted on a SAM 3 articulator (Great Lakes Orthodontics, Tonawanda, N.Y.) using an earbow and centric-relation interocclusal mounting records. The transverse, sagittal and horizontal planes of occlusion relative to the condyles were assessed. The models were evaluated for interferences in maximum intercuspation relative to centric relation mounting. The function in excursive movements was assessed for harmonious anterior disclusion.<sup>4</sup>

In this case, it was determined that overall lengthening of the incisal edge by 2 mm would be appropriate.

## Treatment Plan

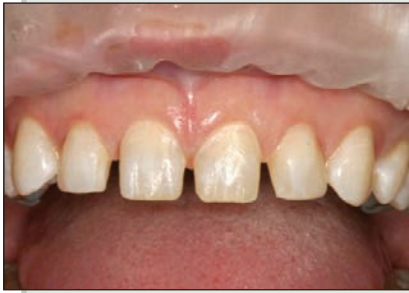The patient selected the direct, conservative approach to treatment, rather than indirect, laboratory-processed restorations.

### Technique

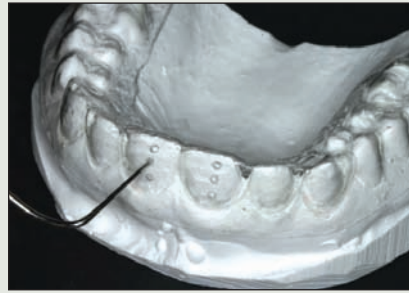
The following sequence was used for the restoration and is recommended for others using hybrid composites.

#### Laboratory Pretreatment Phase

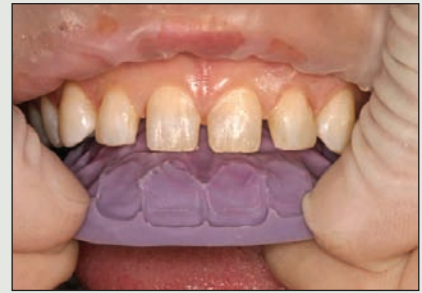- Mounted models of the intraoral mock-up of the lengthened teeth were sent to the laboratory, along with a prescription detailing the goals in the case and intraoral photographs of the mock-up.
- The laboratory staff duplicated the models and set them aside to preserve the original information and then proceeded to wax up an ideal restoration, taking care to duplicate the required incisal plane and incisal edge position (Fig. 6). The laboratory then provided the following materials for the preparation: a clear vacuum-formed stent, fabricated from the wax-up that had been used as a preparation guide; and a lingual matrix made of polyvinyl putty (Sil-Tech, Ivoclar Vivadent, Amherst, N.Y.), as described by Fahl,<sup>2,3</sup> to be used in defining the precise location of the labioincisal line angle, to assist in contouring the interproximal surfaces and to develop the lingual surface.



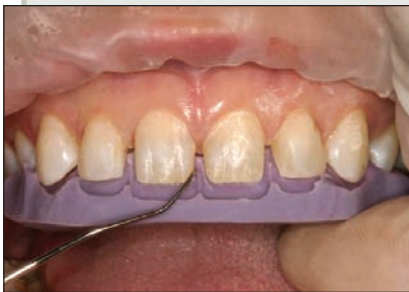**Figure 7:** The pre-existing composite is removed, and the anterior teeth that are to be restored undergo minimal preparation.



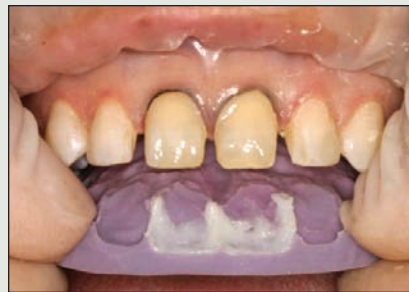**Figure 8:** A stent is used to assess the adequacy of preparation. The stent can be perforated at several locations, and the amount of preparation assessed with a periodontal probe.



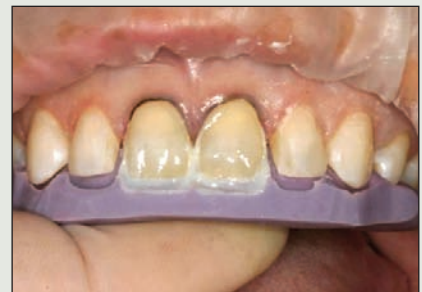**Figure 9:** The polyvinyl matrix was trimmed on the model created from the wax-up. In this image, the matrix is being tried on the preparations to ensure adequacy of fit.



**Figure 10:** The lingual and interproximal extent of the preparation is scribed onto the matrix with an explorer.



**Figure 11:** A very thin layer of the opaque composite is pressed into the matrix in the incisal region, just past the line scribed in Fig. 10.



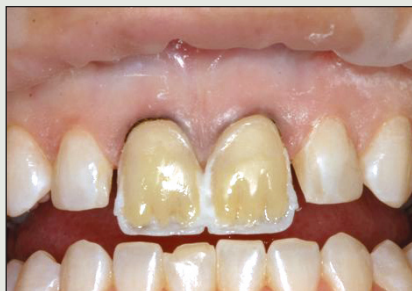**Figure 12:** The matrix is fully seated on the preparations, and the composite is cured with the matrix in place.

*Treatment Phase: Preparation and Layering of Composite*

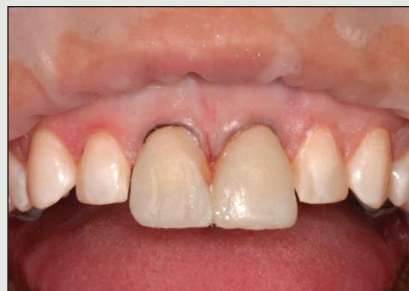- The patient was anesthetized, and the arch isolated.
- The vacuum-formed stent was tried on the patient's upper arch; where the teeth interfered with complete seating of the stent, they were adjusted with a bur.
- The old composite restorations were removed, and minimal preparation of the enamel was performed (Fig. 7). In this case, because the shade to be achieved was somewhat lighter than the pre-existing composite and tooth structure, a minimum thickness of 0.5 mm was required for the restorative material.
- The amount of preparation was assessed with the clear vacuum-formed stent. Because it can be difficult to assess the amount of preparation through the stent, the stent can be perforated and the amount of preparation measured with a probe (Fig. 8). In some areas of the preparation, little or no enamel was removed, whereas

in other areas the preparation extended into the enamel. Extension of the preparation into the dentin is to be avoided. A feather-edge margin is preferred for all areas, and this can be assessed during finishing.

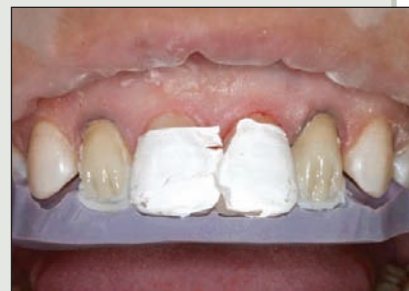- The lingual matrix prepared in the laboratory was seated onto the teeth (Fig. 9), and full seating was confirmed.
- A line was traced onto the matrix to indicate the extent of the preparation (Fig. 10) interproximally and incisally.
- The arch was isolated for bonding, the enamel etched, any exposed dentin primed and bonding agent applied and cured.
- Esthet-X composite (Dentsply Caulk, Milford, Del.) was used to restore this patient's teeth. A very thin layer of high-opacity, high-value composite (shade "white opaque") was placed into the matrix, extending from just past the traced line and into the incisal edge, thereby defining the labioincisal line angle (Fig. 11). The thin layer at the incisal edge would be



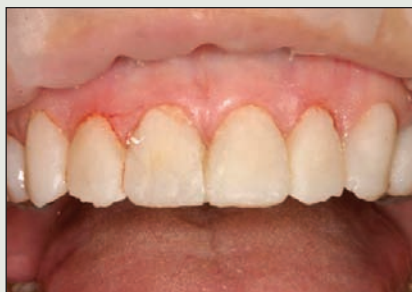**Figure 13:** The intermediate dentinal anatomy, with dental lobes and interproximal line angles, is created using a mid-opacity composite.



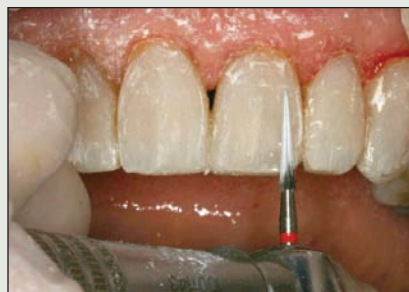**Figure 14:** A final layer of high-translucency composite is condensed to create the full contour of the restorations on the central incisors.



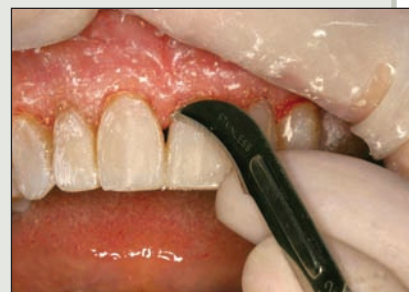**Figure 15:** The other teeth, extending distally around the arch, are restored in the following order: lateral incisors, cuspids, bicuspid. Teflon tape was used to isolate the teeth from each other during the bonding process.



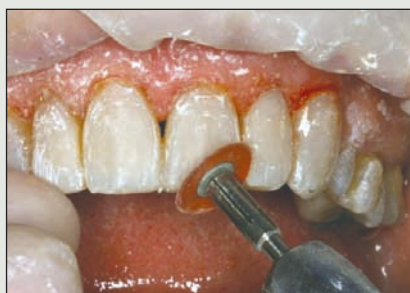**Figure 16:** After application of the final layer of translucent composite, the 8 anterior teeth have been restored to their full contour. No finishing has begun at this stage.



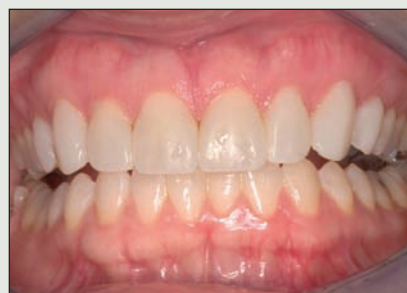**Figure 17:** Twelve-blade carbide burs are used for initial shaping.



**Figure 18:** A #12 scalpel blade is used to contour the interproximal regions; care is taken not to traumatize the gingiva.



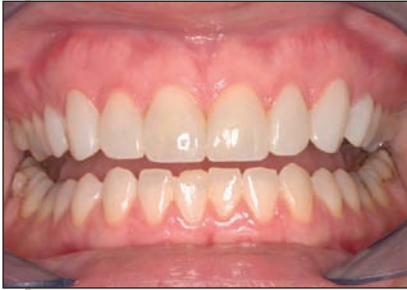**Figure 19:** Disks are used to continue development of surface anatomy. Coarse and then medium disks are sufficient.



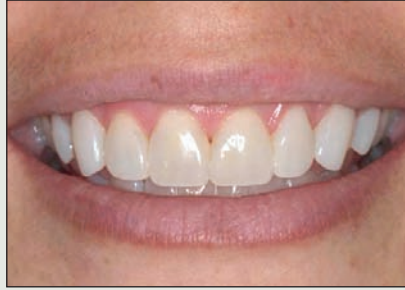**Figure 20:** The contouring has been completed, and the incisal and labial anatomy is fully developed.

come the “incisal halo” at the time of finishing. Initially, this was done for the central incisors only.

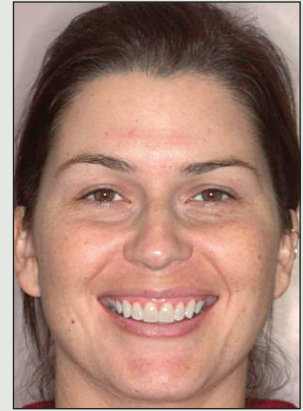
- The lingual matrix was then seated, and the opaque composite cured (Fig. 12) with the matrix in place.
- This lingual shell of composite formed a matrix against which the various opacities of composite were condensed. Body composite of medium opacity was placed to mimic the full contour of the dentinal anatomy. Lobes were formed in the incisal third, which left room for the incisal characterizations (Fig. 13). Incisal tints were placed to mimic rogue discolorations such as dysplasias, to highlight the dentinal lobes and to emphasize incisal translucencies.
- Low-opacity (high-translucency) composite was layered into the incisal zone and over the



**Figure 21:** Retracted view of the final restorations on the 8 maxillary anterior teeth.



**Figure 22:** Full smile, demonstrating the harmony of the restoration with the soft-tissue frame of the lips.



**Figure 23:** Full-face photograph of the patient after completion of the restorations.

- labial surface of the medium-opacity composite to create the preliminary full contours of the restoration (**Fig. 14**). Alignment in all planes of space was confirmed before proceeding with the adjacent teeth. The central incisors were joined by a thin layer of composite at this stage; they were subsequently separated by an interproximal saw (a bur may also be used for this purpose).
- Next, the lateral incisor teeth on both sides were restored and contoured (**Fig. 15**). Teflon tape was used as an interproximal matrix to avoid inadvertent bonding to adjacent teeth.
  - The next teeth to be restored were the cuspids. On the basis of clinical observations, it was determined that the first bicuspid would also be augmented, and this was accomplished freehand (without the benefit of the matrix). The layered restoration was somewhat over-contoured labially, and some flash extended slightly over the labioincisal edge defined by the matrix (**Fig. 16**).
  - The contour of the labial anatomy was achieved with 12-blade carbide burs (**Fig. 17**). It is important to align the burs so that contouring can proceed separately for the interproximal and labial planes of space and thus to define the location of the mesial and distal line angles. For the lingual surface, a football-shaped carbide bur was most effective.
  - A scalpel blade was used to sculpt the cured composite and thereby contour the interproximal surfaces (**Fig. 18**). The surface should be planed as perpendicular to the contour as possible to prevent nicks and roughness.
  - Next, coarse and then medium disks (Soflex, 3M ESPE, St. Paul, Minn.) were used (**Fig. 19**); care was taken to preserve the line angles. The interproximal surfaces were finished and polished with composite finishing strips (Epitex Strips, GC America, Alsip, Ill.). As initial contouring began, the incisal length and contours created with the use of the polyvinyl matrix were revealed (**Fig. 20**).
- The author allows approximately 45 minutes per tooth for this technique. When more than 4 teeth are involved, the finishing is completed during a second appointment.
- Final Contouring and Polishing*
- The final contours were confirmed by labial and incisal inspection. The margins were checked with an explorer and floss.
  - Initial polishing was achieved with Enhance (Dentsply Caulk) disks, points and cups; again, care was taken to finish the labial and interproximal surfaces without finishing over the line angles. The instruments were used with water to create a smooth surface and to remove the scratches created by the disks. These instruments can remove significant amounts of composite, so should be used with very little pressure. They are continually moved across the surface of the composite; care is needed to avoid polishing away the incisal contours, line angles and anatomy created by the burs and disks.
  - PoGo disks, points and cups (Dentsply Caulk) were used to complete the polishing; they were

initially applied wet with moderate pressure and then dry with light pressure until a polish simulating moist natural teeth was achieved.

In this technique, no additional pastes or polishing compounds were used. The final result is depicted in **Figs. 21–23**.

### Conclusion

Direct composite restorative material produces a result which is predictably durable for many years, is repairable and extremely conservative. For these reasons hybrid composite is often considered the material of choice, yielding restorations with esthetic results as good as, or better than, those of indirect restorations. ✦

### THE AUTHOR

**Acknowledgments:** *The author thanks James Neuber, RDT, of Ocean Ceramics Laboratories in Coquitlam, B.C., for his attention to detail and his dedication to technical excellence in this case. Very special thanks also go to Drs. Edward Lowe and Steven Hill for their support and guidance.*



**Dr. Kleeberger** is a general practitioner in full-time practice in Langley, British Columbia.

**Correspondence to:** Dr. Bruce Kleeberger, #202-20644 Eastleigh Cres., Langley, BC V3A 4C4. Email [drkleeberger@telus.net](mailto:drkleeberger@telus.net)

*Dr. Kleeberger mentors the Pacific Esthetic Restorative Continuum, which is in part supported by Dentsply Canada. He has no declared financial interests in any company manufacturing the types of products mentioned in this article.*

### References

1. Blank JT. Esthetic success with Esthet-X. Corporate-sponsored workshop, Dentsply/Caulk. Annual Scientific Session of the American Academy of Cosmetic Dentistry, 2003 May 1, Orlando, Florida.
2. Fahl N Jr. A polychromatic composite layering approach for solving a complex Class IV/direct veneer/diastema combination: part I. *Pract Proced Aesthet Dent* 2006; 18(10):641–5.
3. Fahl N Jr. A polychromatic composite layering approach for solving a complex Class IV/direct veneer/diastema combination: part II. *Pract Proced Aesthet Dent* 2007; 19(1):17–22.
4. Dawson PE. Functional occlusion: from TMJ to smile design. St. Louis (MO): Mosby Elsevier; 2007.
5. Naylor CK. Esthetic treatment planning: the grid analysis system. *J Esthet Restor Dent* 2002; 14(2):76–84.
6. Mancuso A. Esthetic dentistry and the golden proportion. *Oral Health* April 2004; 94(4):51–60.