

Marble Bone Disease: A Review of Osteopetrosis and Its Oral Health Implications for Dentists

David K. Lam, DDS; George K.B. Sándor, MD, DDS, PhD, FRCD(C), FRCSC, FACS; Howard I. Holmes, DDS; Robert P. Carmichael, DMD, MSc, FRCD(C); Cameron M.L. Clokie, DDS, PhD, FRCD(C)

Contact Author

Dr. Sándor
Email: george.sandor@utoronto.ca



ABSTRACT

Osteopetrosis is one cause of osteosclerosis and may result in such serious oral complications as osteomyelitis and exposed necrotic bone. Dentists should be aware of patients with the disease because of its effect on osteoclast function, which results in impaired wound healing. The purpose of this paper is to review the causes, pathogenesis and differential diagnosis of osteopetrosis and to provide guidance to dentists on the management of patients with osteopetrosis.

For citation purposes, the electronic version is the definitive version of this article: www.cda-adc.ca/jcda/vol-73/issue-9/839.html

Osteopetrosis is a disorder that includes impaired osteoclast function and may have serious adverse oral sequelae. Also known as marble bone disease, osteopetrosis was described in 1904 by Albers-Schönberg.¹ It comprises a group of rare hereditary skeletal disorders characterized by a marked increase in bone density due to a defect in remodeling caused by the failure of normal osteoclast function.² The estimated prevalence is 1 in 100,000–500,000.² It takes 2 major clinical forms: the autosomal dominant adult (benign) form is associated with few or no symptoms,^{1–3} whereas the autosomal recessive infantile (malignant) form, if untreated, is typically fatal during infancy or early childhood.^{1,2,4} A rarer autosomal recessive (intermediate) form presents during childhood with some signs and symptoms of malignant osteopetrosis.⁵ In especially rare cases, osteopetrosis may exist as lethal, transient infantile and postinfectious forms.⁶

Osteomyelitis and exposed necrotic bone may occur in osteopetrotic jaws following

dental extractions. Osteomyelitis of the jaws can eventually be fatal in these fragile patients. Thus, an understanding of the role of the oral microbiota in the pathogenesis of disorders, such as osteopetrosis, that may impair normal osteoclast function is important to the dental practitioner to optimize oral health and prevent adverse sequelae.

Pathogenesis

Unlike the iatrogenically induced bisphosphonate-associated osteonecrosis of the jaws (BONJ), most forms of osteopetrosis are transmitted as autosomal traits. However, the molecular basis for these diseases remains unclear.⁶ The gene for adult osteopetrosis has been mapped to chromosome 1p21.⁷ Similar to bisphosphonate-associated osteonecrosis, the pathogenesis of all true forms of osteopetrosis involves diminished osteoclast-mediated skeletal resorption.¹ The number of osteoclasts is often increased, but as they fail to function normally, bone is not resorbed.² This defective osteoclastic bone resorption, along with

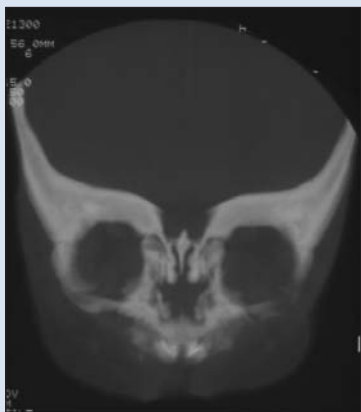


Figure 1: Computed tomography scan indicating the extent of infantile osteopetrosis; marble-like bone occurs throughout the cranium. Compression of the optic canal results in blindness for many of these patients.

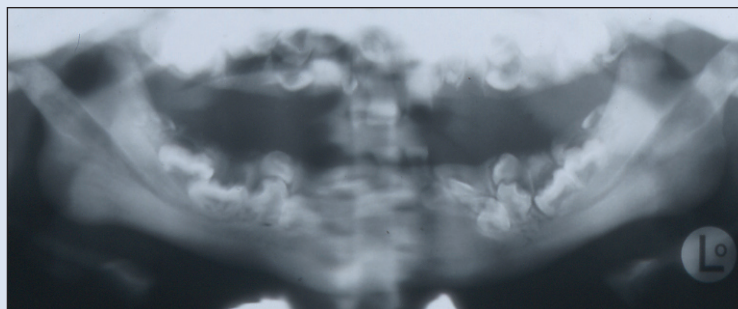


Figure 2: Panoramic radiograph in a patient with the infantile form of osteopetrosis.

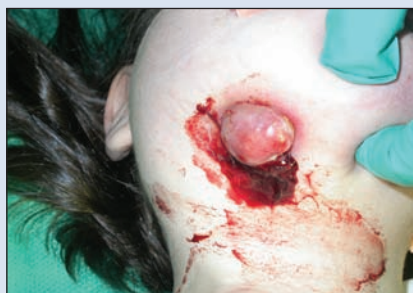

Figure 3: Symptomatic fistula with frequent drainage and hemorrhage seen at the time of palliative debridement.

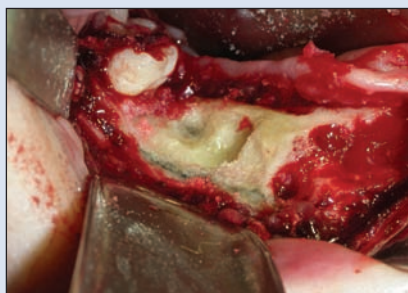

Figure 4: A green hue of the necrotic bone at time of debridement is due to colonization with a *Pseudomonas* species of bacteria.

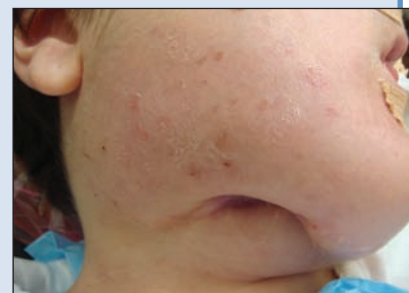

Figure 5: Healed fistula and defect at the inferior border of the mandible.

continued bone formation and endochondral ossification, leads to cortical bone thickening and cancellous bone sclerosis.

The causes of osteoclast failure are unclear, but may involve abnormalities in the osteoclast stem cell or its microenvironment, osteoblast precursor cells or the mature heterokaryon or in the bone matrix.¹ Alterations in the factors required for bone resorption, such as the synthesis of abnormal parathyroid hormone (PTH) or defective production of interleukin-2 (IL-2) or superoxide, are also possible causes.¹ Ultimately, impaired bone resorption results in skeletal fragility because fewer collagen fibrils connect osteons properly, and remodeling of woven bone to compact bone is defective.⁸

Clinical Presentation

Infantile Osteopetrosis

Patients with osteopetrosis at birth or early infancy usually have a severe form of the disease (**Box 1**) and

present with a diffusely sclerotic skeleton^{1,9} (**Figs. 1 and 2**). Initial signs often include normocytic anemia with hepatosplenomegaly due to compensatory extramedullary hematopoiesis and increased susceptibility to infections due to granulocytopenia. Some patients may develop hydrocephalus or sleep apnea. If untreated, most die during their first decade of life from hemorrhage, pneumonia, severe anemia or sepsis. This overwhelming sepsis may result from osteomyelitis of their sclerotic jaws, which can be recalcitrant to treatment (**Figs. 3 to 5**).

Intermediate Osteopetrosis

Affected patients have a short stature and are often asymptomatic at birth, but frequently exhibit fractures by the end of their first decade of life.¹ Marrow failure and hepatosplenomegaly are rare.³ Some present with cranial nerve deficits (**Fig. 1**), macrocephaly, mild or moderately severe anemia and ankylosed teeth that may predispose them to osteomyelitis of the jaws¹ (**Figs. 2 to 5**).

Box 1 Common orofacial findings in infantile osteopetrosis^{2,9}

- Facial deformity (broad face, hypertelorism, snub nose and frontal bossing)
- Optic atrophy, nystagmus and blindness, deafness and facial paralysis (due to failure of resorption and remodeling of skull bones with resultant narrowing of skull foramina and pressure on various cranial nerves)
- Nasal stuffiness (due to malformation of mastoid and paranasal sinuses)
- Delayed tooth eruption
- Tooth roots often difficult to visualize due to density of surrounding bone
- Osteomyelitis as a complication of tooth extraction

Box 2 Common orofacial findings in adult osteopetrosis

- Congenitally absent, delayed or unerupted malformed teeth
- Increased susceptibility to caries due to reduced calcium-phosphorus ratio in both enamel and dentin that may decrease hydroxyapatite crystal formation^{2,9}
- Most serious complication is increased susceptibility to develop osteomyelitis. As the vascular supply to the jaws is compromised, avascular necrosis and infection after dental extractions may lead to osteomyelitis^{2,9}

Transient Osteopetrosis

Radiography may reveal evidence of diffuse sclerosis and marrow failure, which may resolve without specific therapy and with no known sequelae.²

Adult Osteopetrosis

The adult form of osteopetrosis is usually discovered later in life and has less severe manifestations. The axial skeleton usually shows significant sclerosis, whereas the long bones have minimal or no defects. Approximately 40% of those affected are asymptomatic and marrow failure is rare.² Bone pain is frequent in symptomatic patients. Occasionally, diagnosis may be based on dental radiographs that show a diffuse increased radiopacity of medullary bone.

Two major adult variants exist.² In one, cranial nerve compression is common but fractures are rare; whereas, in the other, nerve compression is uncommon and fractures frequent. If the mandible is involved, fractures and osteomyelitis may be significant complications following tooth extraction (**Box 2**).

Table 1 Laboratory findings for osteopetrosis

Infantile osteopetrosis
Serum calcium levels generally reflect dietary intake, ¹⁰ but hypocalcemia may occur.
Secondary hyperparathyroidism with elevated serum calcitriol is common. ^{10,11}
Serum acylphosphatase (ACP) is increased. Presence of the brain isoenzyme of creatine kinase (BB-CK) in the serum is a biochemical marker for osteopetrosis. ACP and BB-CK originate from osteoclasts. ¹²
Adult osteopetrosis
Standard biochemical indices of mineral homeostasis usually unremarkable, but serum parathyroid hormone levels may be elevated. ¹

Histopathologic Features

A failure of osteoclasts to resorb skeletal tissue, with remnants of mineralized primary spongiosa that persist as islands of calcified cartilage within mature bone, is characteristic of osteopetrosis.¹ Several patterns of abnormal endosteal bone formation may be seen²:

- tortuous lamellar trabeculae replacing the cancellous portion of bone
- globular amorphous bone deposition in marrow spaces
- osteophytic bone formation.

The number of osteoclasts may be increased, normal or decreased, but there is no evidence of functional osteoclasts, as Howship’s lacunae are not visible.

Table 1 lists the laboratory findings in infantile and adult forms of osteopetrosis.

In the infantile form of osteopetrosis, osteoclasts are usually abundant and found at the bone surfaces. Osteoclast nuclei are especially numerous, but the ruffled borders or clear zones that characterize normal osteoclasts are absent and fibrous tissue usually crowds the marrow spaces.¹

In the adult form, there is an increased amount of osteoid and osteoclasts may be few in number, lack ruffled borders or be especially numerous and large.¹ Woven bone is also common.

Differential Diagnosis

Other causes of widespread osteosclerosis may include Van Buchem disease, autosomal dominant osteosclerosis, such as endosteal hyperostosis of the Worth type, and sclerosteosis. In addition, pyknodysostosis is associated with impacted teeth and nonfunctioning osteoclasts in the setting of a cathepsin-K gene defect.

It has been suggested that bisphosphonate therapy can induce a condition similar to that found with

osteopetrosis. Whyte and colleagues¹³ described a case of abnormal bone remodeling and increased bone density with histologic features of osteopetrosis associated with extended pamidronate therapy in a 12-year-old boy. Such cases of BONJ could be differentiated from osteopetrosis using the brain isoenzyme of creatine kinase (BB-CK), which is a biochemical marker of osteopetrosis.

Treatment and Prognosis

Adult osteopetrosis is usually associated with long-term survival as this form of the disease is mild. However, the prognosis for infantile osteopetrosis without therapy is usually poor, with most of those affected dying in their first decade of life.² Because of the differing severity of the various forms of osteopetrosis, a correct diagnosis is essential before proper therapy can be initiated.

Bone Marrow Transplantation

Bone marrow transplantation is the only permanent cure for osteopetrosis, but an appropriately matched donor is usually available for only about 50% of those affected, and engraftment is successful in about 45% of transplants.² Bone marrow transplantation may result in remarkable improvement among many infantile osteopetrosis patients, but may not benefit all because of the variety of underlying causes of the disease.

Hormonal and Dietary Therapy

Some success has been achieved with a calcium-deficient diet alone. However, in severe cases of osteopetrosis, calcium supplementation may be necessary for symptomatic hypocalcemia.² Calcitriol may help by stimulating dormant osteoclasts, but some patients are resistant to this treatment.² Interferon gamma-1b, often in combination with calcitriol, has been shown to reduce bone mass and decrease the prevalence of infections and nerve compression.^{1,2} Other therapies include corticosteroids to increase circulating red blood cells and platelets, PTH, macrophage colony stimulating factor and erythropoietin.^{1,2}

Supportive Measures


Osteomyelitis requires rapid intervention with early diagnosis, drainage, debridement, bacterial culture and sensitivity testing followed by appropriate antibiotic therapy. Surgical intervention is limited to necessary extractions, incision and drainage and possible palliative debridement. Infection often requires prolonged intravenous antibiotic therapy, and hyperbaric oxygen may be useful to promote healing in recalcitrant cases.¹ Surgical decompression of affected cranial nerves may be of benefit.¹ Other supportive measures include antibiotics and transfusions to treat complications.

Conclusion

Special attention should be paid to patients with osteopetrosis due to their fragile bone status resulting from

defects in osteoclast function and consequent impaired wound healing. These patients should receive increased attention and prophylactic dental treatment to maintain their fragile oral health status. Preventive measures must be continuously and vigorously maintained. Dentists should refer patients with osteopetrosis to a specialist for even the simplest extraction or other surgical dental procedures to ensure management of the serious adverse effects that may arise from oral surgery. Every effort should be made to avoid extractions in this high risk group of patients. ♦

THE AUTHORS



Dr. Lam is senior resident, division of oral and maxillofacial surgery and anesthesia, Mount Sinai Hospital, PhD Harron Scholar, Collaborative Program in Neuroscience, and clinician-scientist fellow, Centre for the Study of Pain, University of Toronto, Toronto, Ontario.



Dr. Sándor is clinical director, graduate program in oral and maxillofacial surgery and anesthesia, Mount Sinai Hospital; coordinator, pediatric oral and maxillofacial surgery, The Hospital for Sick Children and Bloorview Kids Rehab; professor of oral and maxillofacial surgery, University of Toronto, Toronto, Ontario; professor, Regea Institute for Regenerative Medicine, University of Tampere, Tampere, Finland; and docent in oral and maxillofacial surgery, University of Oulu, Oulu, Finland.



Dr. Holmes is director, surgical orthodontic program and undergraduate program in oral and maxillofacial surgery, University of Toronto, Toronto, Ontario.



Dr. Carmichael is coordinator of pediatric prosthodontics, The Hospital for Sick Children and Bloorview Kids Rehab, and assistant professor, faculty of dentistry, University of Toronto, Toronto, Ontario.



Dr. Clokie is professor and head, oral and maxillofacial surgery and anesthesia, University of Toronto, Toronto, Ontario.

Correspondence to: Dr. George K.B. Sándor, The Hospital for Sick Children, S-525, 555 University Ave., Toronto ON M5G 1X8.

The authors have no declared financial interests.

This article has been peer reviewed.

References

- Whyte MP. Sclerosing bone disorders. In: Favus MJ, editor. Primer on the metabolic bone diseases and disorders of mineral metabolism. 4th ed. New York: Lippincott Williams & Wilkins; 1999. p. 367–83.
- Neville BW, Damm DD, Allen CM, and Bouquot JE. Bone pathology. In: Oral and maxillofacial pathology. 2nd ed. China: Saunders; 2002. p. 533–87.
- Johnston CC, Lavy N, Lord T, Vellios F, Merritt AD, Deiss WP. Osteopetrosis. A clinical, genetic, metabolic, and morphologic study of the dominantly inherited, benign form. *Medicine (Baltimore)* 1968; 47(2):149–67.
- Loria-Cortes R, Quesada-Calvo E, Cordero-Chaverri C. Osteopetrosis in children: a report of 26 cases. *J Pediatr* 1977; 91(1):43–7.

5. Kahler SG, Burns JA, Aylsworth AS. A mild autosomal recessive form of osteopetrosis. *Am J Med Genet* 1984; 17(2):451–64.
6. Whyte MP. Recent advances in osteopetrosis. In: Cohn DV, Gennari C, Tashian AH, editors. Calcium-regulating hormones and bone metabolism. Amsterdam: Elsevier; 1992. p. 420–30.
7. Van Hul W, Bollerslev J, Gram J, Van Hul E, Wuyts W, Benichou O, and others. Localization of a gene for autosomal dominant osteopetrosis (Albers-Schonberg disease) to chromosome 1p21. *Am J Hum Genet* 1997; 61(2):363–69.
8. Marks SC Jr. Osteopetrosis — multiple pathways for the interception of osteoclast function. *Appl Pathol* 1987; 5(3):172–83.
9. Krebsbach PH, Polverini PJ. Dental manifestations of disorders of bone and mineral metabolism. In: Favus MJ, editor. Primer on the metabolic bone diseases and disorders of mineral metabolism. 4th ed. New York: Lippincott Williams & Wilkins; 1999. p. 459–61.
10. Key L, Carnes D, Cole S, Holtrop M, Bar-Shavit Z, Shapiro F, and others. Treatment of congenital osteopetrosis with high dose calcitriol. *N Engl J Med* 1984; 310(7):409–15.
11. Cournot G, Trubert-Thil CL, Petrovic M, Boyle A, Cormier C, Girault D, and others. Mineral metabolism in infants with malignant osteopetrosis: heterogeneity in plasma 1,25-dihydroxyvitamin D levels and bone histology. *J Bone Miner Res* 1992; 7(1):1–10.
12. Whyte MP, Chines A, Silva DP Jr, Landt Y, Ladenson JH. Creatine kinase brain isoenzyme (BB-CK) presence in serum distinguishes osteopetrosis among the sclerosing bone disorders. *J Bone Miner Res* 1996; 11(10):1438–43.
13. Whyte MP, Wenkert D, Clements KL, McAlister WH, Mumm S. Bisphosphonate-induced osteopetrosis. *N Engl J Med* 2003; 349(5):457–63.