

The “Point of Care” section answers everyday clinical questions by providing practical information that aims to be useful at the point of patient care. The responses reflect the opinions of the contributors and do not purport to set forth standards of care or clinical practice guidelines. Readers are encouraged to do more reading on the topics covered. If you would like to contribute to this section, contact editor-in-chief Dr. John O’Keefe at [jokeefe@cda-adc.ca](mailto:jokeefe@cda-adc.ca).

## QUESTION 1

How can I limit the number of different dental cements available in my dental practice and still be able to address all prosthetic clinical situations?

### Background

As a clinician’s repertoire expands to include various indirect restorations, there is a tendency to accumulate a large number of different dental cements in the office. As prosthetic materials each demand specific luting agents, logistic headaches arise for both the dentist and staff. Regrettably, the “universal” dental cement is still elusive.

Several types of dental cement are available, each possessing unique properties and handling characteristics; no one product is ideal for every type of restoration. A dental cement should act as a barrier against microbiological leakage, holding the tooth and restoration together through some form of attachment (mechanical, chemical or a combination) and sealing the interface between them.<sup>1</sup> Manipulation of any cement is important, as variations in the powder-to-liquid ratio can significantly influence working and setting time, consistency and flow and the degree of solubility, strength and film thickness of the cement.<sup>2</sup> In this article, I discuss and justify the choice of dental

cements currently being used in our prosthodontic group practice (Table 1).

### Choice of Dental Cements

#### Conventional Fixed Prosthodontics


Provisional restorations can be cemented with calcium hydroxide (Dycal, Dentsply International, York, Penn.), as this material is easy to manipulate, readily available and does not interfere with or compromise the integrity of the permanent cement. One generally places it on the margins of an interim restoration, then seats the restoration. The crown should not be filled with cement as this can lead to difficulties when trying to remove it. This cement sets rapidly and excess cement is easily cleaned up.

Three other cements are required to address all aspects of fixed prosthodontics. C&B Metabond (Parkell, Edgewood, N.Y.) is the cement of choice for nonprecious metals, such as resin-bonded bridges and bonded posts in endodontically treated teeth. This cement is formulated with methyl methacrylate monomer and acrylic resin filler and is catalyzed by tributyl-borane. It bonds to enamel, dentin and metal. The use of a C-R syringe (Centrix, Shelton, Conn.) reduces voids in the cement and allows the clinician to control the placement of the cement with great ease (Figs. 1–3). This adhesive cement is invaluable for patients who present with fractured porcelain and exposed metal on a porcelain-fused-to-metal restoration. Masking the exposed metal with opaque C&B Metabond provides an excellent esthetic result when a porcelain repair is indicated.

A dental cement that is proving to be a workhorse for most indirect restorations is Maxcem (Kerr Corp., Orange, Calif.). This self-etching, self-adhering cement is a dual-cure resin cement that is dispensed directly with an auto-mixing syringe. Once the restoration is seated, excess material can be light cured for several seconds allowing for easy clean-up. It is indicated for all metal and

**Table 1** Cements used for different types of restorations

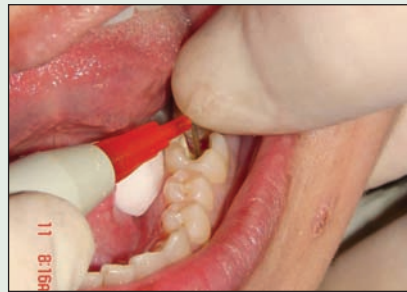Type of restoration	Dental cement
<b>Conventional fixed prosthodontics</b>	
Provisional restoration	Dycal
Cast post and core	C&B Metabond
Resin-bonded bridge	C&B Metabond
Metal inlay/onlay/full gold crown Porcelain inlay/onlay/crown	Maxcem
Porcelain-fused-to-metal restoration	Maxcem
Porcelain veneers	Nexus 3
<b>Implant-supported prostheses</b>	
Alumina abutments	Maxcem
Zirconia abutments	Nexus 3
Titanium/gold alloy abutments	Improv



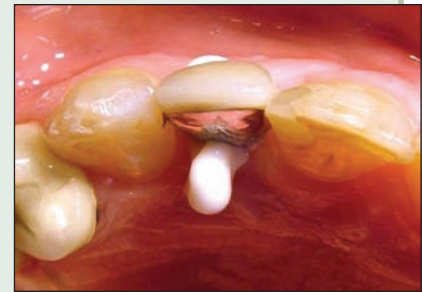**Figure 1:** Mixing and loading C&B Metabond into a Centrix syringe tube.



**Figure 2:** The C-R syringe.



**Figure 3:** Expressing the cement for a cast post and core restoration.



**Figure 4:** Excess Improv cement for an implant-supported porcelain-fused-to-metal restoration cemented on a gold alloy abutment.

ceramic inlays, onlays and full coverage restorations. Anecdotally, patients have not reported any postoperative sensitivity when Maxcem has been used.

The resin-luting cement Nexus 3 (Kerr) is ideal for cementing porcelain veneers as it is available in a number of shades and viscosities. This cement can be light- or dual-cured.

### Implant-Supported Prostheses

All ceramic implant-supported prostheses cemented to zirconia abutments require a final cement that is both strong and esthetic. In this situation, either Maxcem or Nexus 3 can be used. Improv (Nobel Biocare, Gothenburg, Sweden) is a universal cement in implant prosthodontics that can be used for implant-supported prostheses in which porcelain-fused-to-metal restorations are cemented to customized or prefabricated metal (titanium, gold alloy) abutments (Fig. 4).

As the technology of dental biomaterials continues to evolve, a universal dental cement may become a reality. Until that time, this list of 5 dental

cements promises to streamline the inventory of a dental practice, while allowing the clinician to continue to use both traditional and novel prosthetic materials. ♦

### THE AUTHOR



*Dr. John P. Zarb is a prosthodontist with Prosthodontic Associates and a staff prosthodontist at the University of Toronto and Mount Sinai Hospital, Toronto, Ont. Email: [jzarb@buildyoursmile.com](mailto:jzarb@buildyoursmile.com).*

*The author has no declared financial interests in any company manufacturing the types of products mentioned in this article.*

### References

1. Diaz-Arnold AM, Vargas MA, Haselton DR. Current status of luting agents for fixed prosthodontics. *J Prosthet Dent* 1999; 81(2):135-41.
2. Jones DW. Dental cements: an update. *J Can Dent Assoc* 1998; 64(8):569-70.

### Further Reading

Powers JM. Cements. In: Craig RG, Powers JM, editors. *Restorative dental materials*. St. Louis: Mosby; 2002. p. 593-634.

## QUESTION 2

How do I select an attachment for use in a removable partial denture or overdenture?

### Background

Typical considerations when selecting an attachment for a removable partial denture or overdenture include the amount of interocclusal space available, the size and periodontal status of the abutment and the stress-breaking ability of the attachment. Other factors, such as retention, ease of use and anticipated lifespan of the attachment, should also be considered, and these factors are the focus of the discussion in this article. The 2 most commonly used dental attachments in our group prosthodontic practice are the Bredent and Locator attachments.

### Attachment with a Removable Partial Denture

Bredent (Senden, Germany) manufactures a variety of styles of attachments suitable for use in many applications. One of the main benefits of the Bredent line of attachments is their reliability of retention and their ease of use. The retentive mechanism for these attachments is based on plastic female components (friction matrixes) that sit in metal housings in the removable denture. These friction matrixes are colour-coded: green for reduced-friction retention, yellow for regular-friction retention and red for high-friction retention. These plastic retentive components can easily be removed and replaced at chairside by the dental practitioner. A handful of the matrixes can be stocked at little cost and replaced as needed. The selection of a particular friction matrix depends on the design of the prosthesis, the number of abutments available and the patient's manual dexterity.

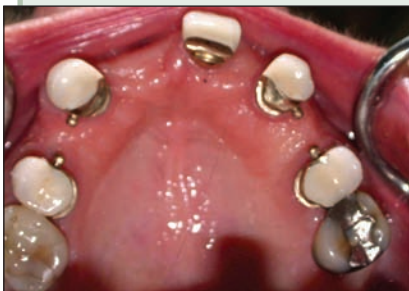### Case 1

The patient in case 1 wanted better retention and a more esthetic removable partial denture, and the Bredent Vario-Kugel-Snap Sagittal (VKS-SG) ball-and-socket stud-type attachment was selected. **Figure 1** illustrates the use of 4 "mini" Bredent VKS-SG attachments. **Figures 2** and **3** illustrate the removable partial denture in place. Because of the number of abutments and the patient's demonstrated ability to insert and remove the partial denture easily, the yellow (regular-friction) matrix was used.

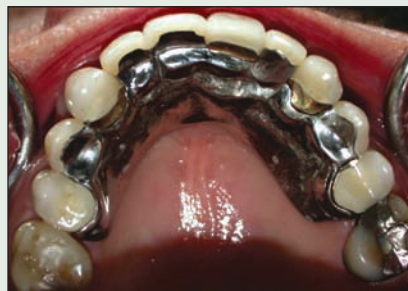### Attachment with an Overdenture

The Locator attachment (manufactured by Zest Anchors, Inc., Escondido, Calif.) is a commonly used attachment in our group prosthodontic practice. It consists of a metal female component that is fixed intraorally and a nylon male component anchored in a metal housing in the denture base. It can be used either for tooth or implant applications. Like the Bredent attachments, the nylon male retention elements of the Locator system are colour-coded according to degree of retention (blue = 1.5 lb/3.3kg, pink = 3 lb/6.6 kg, clear = 5 lb/11 kg). A green retention element is used for abutments of varying degrees of angulation (10° to 20° angle). Furthermore, the Locator has a self-aligning design, whereby the male portion snaps into the female portion. Patients with this attachment find it very easy to insert and remove their dentures.

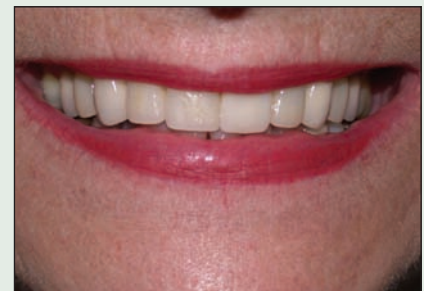Finally, the Locator has a very low profile, so is an ideal choice if interarch space is limited. Like



**Figure 1:** Palatal view of the 4 mini Bredent Vario-Kugel-Snap attachments.



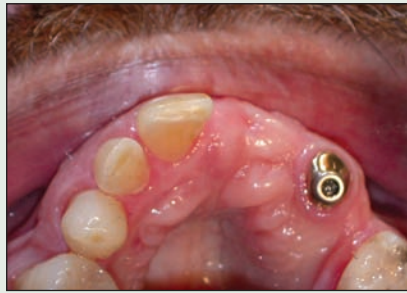
**Figure 2:** Palatal view of the removable partial denture retained with Bredent Vario-Kugel-Snap attachments.



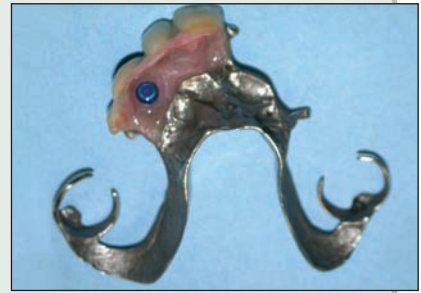**Figure 3:** Frontal view of the removable partial denture.



**Figure 4:** The Locator core tool.



**Figure 5:** The Locator attachment in the tooth 23 root.



**Figure 6:** The blue (1.5-lb) male retentive element in the removable partial denture.

the friction matrixes in the Bredent attachment, the male retentive elements of the Locator attachment can be replaced easily, with minimal time and effort, with the Locator core tool (Fig. 4). The core tool in fact incorporates 3 tools in a single mechanism. The curved section of the tool, for removal of the male portion of the attachment, has a hook to catch and pull the nylon male liner out of the permanent metal housing. The middle section is the male seating tool, used to seat a replacement male portion into the metal housing. The third part of the tool is the abutment driver, for use in an implant application. Because of its retentive capacity, ease of use, ease of maintenance and ease of replacement of components, the Locator has been our attachment of choice in patients with overdentures.

### Case 2

For case 2, the Locator attachment was used in a natural-tooth overdenture application. Tooth 23 was treated endodontically and prepared to

accommodate the Locator attachment, which was cemented with C&B Metabond adhesive resin cement (Parkell, Inc., Edgewood, N.Y.) (Fig. 5). The male nylon component was then anchored in a metal housing in the denture base (Fig. 6). In this situation, the blue (1.5-lb) male retentive element was used.

### Conclusion

Because of their retentive capacity, ease of use, versatility and lifespan, the Bredent line of attachments and the Locator attachment are the attachments of choice in our group prosthodontic practice. ✦

### THE AUTHOR



*Dr. Effrat Habsha is a prosthodontist with Prosthodontic Associates, staff prosthodontist at Mount Sinai Hospital, and an associate in dentistry at the University of Toronto, Toronto, Ontario. Email: [ehabsha@buildyoursmile.com](mailto:ehabsha@buildyoursmile.com).*

*The author has no declared financial interests in any company manufacturing the types of products mentioned in this article.*



## QUESTION 3

My patients complain about food impaction around single implant restorations. Can this be managed and how can I prevent it?

### Background

There are many reasons for food impaction, but it may occur more often around implants because they are different from natural teeth in many respects. When a natural tooth is extracted, there is often a loss of interproximal papilla, which may not be recreated with an implant restoration. A larger issue is the fact that healthy implants exhibit no mobility, whereas natural teeth move varying degrees based on their periodontal condition and the forces placed on them. This movement is not very noticeable until an implant becomes a point of reference and movement of natural teeth becomes obvious (in relation to the stationary implant). The difference in movement makes both placement of a restoration with an adequate interproximal contact and maintenance of the contact difficult. During the recall period, when we examine occlusion as well as interproximal contacts, neighbouring teeth have often moved causing an opening of the contact (**Figs. 1, 2a and 2b**).

An open contact is associated with impaction of food debris in soft tissue and caries in the neighbouring teeth caused by inadequate cleaning of the interproximal debris. As the contact opens further, restoration of neighbouring teeth may be required due to caries (**Fig. 3**). If left unchecked, caries can lead to a need for endodontic treatment and even extraction.

### Prevention and Treatment

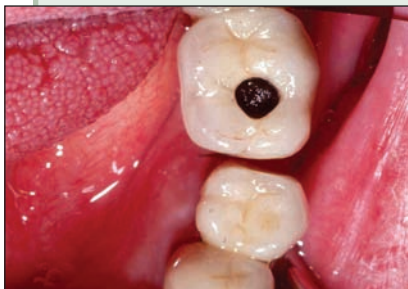The possibility of implant contacts opening must be considered during treatment planning.

The patient must be told that although the success rate of implants is excellent, the crowns that are placed on the implants will need maintenance. Additional efforts are also needed because of the differential movement of implants versus natural teeth. Initial contacts are made broad and flat with solid resistance to removal of floss. Prevention of damage to neighbouring teeth is essential and, at recall visits, not only must the implant be examined, but the adjacent teeth must also be evaluated for possible carious involvement.

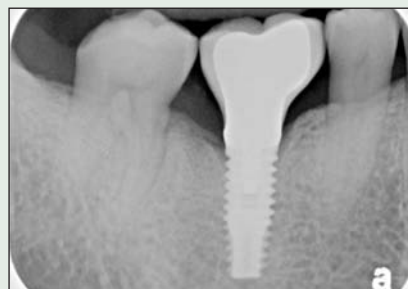Once a contact opens, treatment is designed to close it. If the restoration is cemented in place over an implant abutment and cannot easily be removed, bonding resin on the approximating surface of the neighbouring tooth should be considered if that surface is suitable for bonding (enamel or dentin). If caries has developed, it must be treated. If the neighbouring tooth has been previously restored with a full coverage cast restoration, the restoration may have to be replaced (**Fig. 4**). The contact is then made tight, but the patient must be made aware that there is still potential for movement and treatment may be needed again.

If the patient does not want the neighbouring tooth adjusted, the contact can be closed by slot preparation of the implant crown surface, etching with hydrofluoric acid, silanating the ceramic surface, then bonding composite resin to the area (**Fig. 5**).

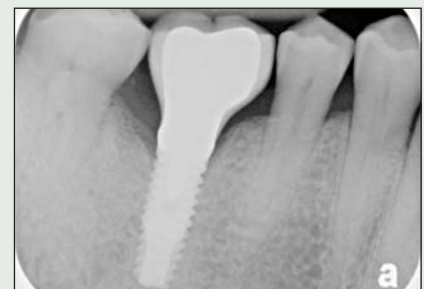This treatment is easier if the crown placed on the implant is designed to be removed when necessary. This can be accomplished by creating a



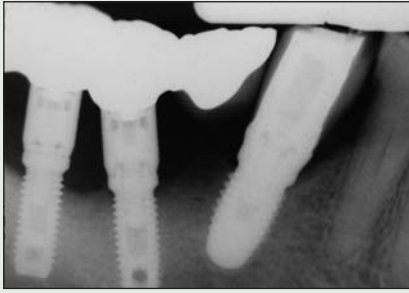
**Figure 1:** An interproximal contact has opened between the second premolar and first molar due to mesial movement of the second premolar.



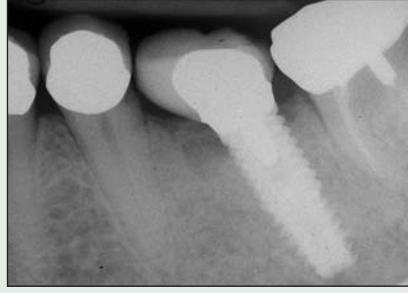**Figure 2a:** Radiograph of implant crown at the time of crown placement showing acceptable mesial contact.



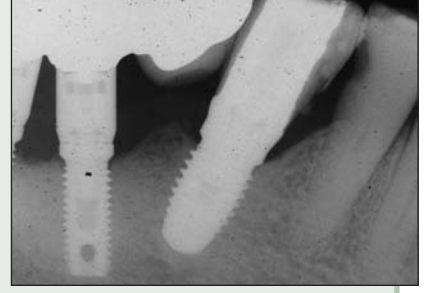
**Figure 2b:** Radiograph of implant crown at 6-month recall appointment showing an opening mesial contact.



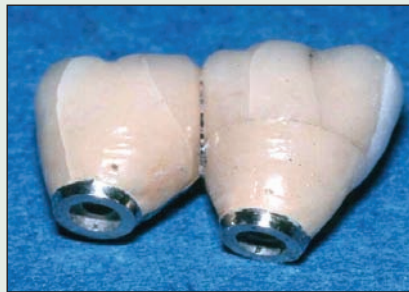**Figure 3:** An open mesial contact between an implant (45) and tooth 44 has allowed caries to develop on the distal surface of tooth 44



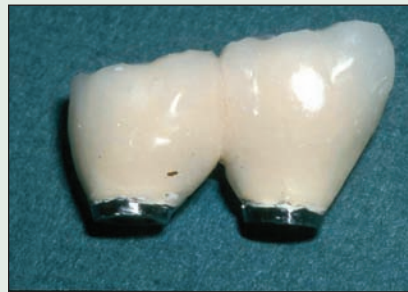**Figure 4:** An open mesial contact on the implant in the 36 position has allowed collection of debris and development of caries at the gingival crown margin of tooth 35. The crown on tooth 35 was replaced.



**Figure 5:** An open contact has been restored by cutting into the restorative material along the mesial edge and bonding additional material to it. The carious lesion in the distal surface of tooth 44 must now be restored.



**Figure 6:** Attempts to add new porcelain to a prosthesis that has been in the mouth for an extended period often causes catastrophic failure of existing porcelain. Fractured porcelain must be stripped from the metal substructure and replaced.



**Figure 7:** Rather than porcelain, laboratory-cured composite resin can be applied to metal and serve as a final restoration. In future, new material can be easily added intraorally.

screw-retained crown or a cemented crown using temporary cement or built-in design mechanisms allowing easy removal. The crown can then be removed from the mouth and the porcelain removed from its substructure and reapplied to a greater interproximal dimension. Note: new porcelain cannot be added to old porcelain that has been in the mouth for an extended period; therefore, porcelain must be replaced. Forward planning is useful, as one can design the final restoration from material that is easily bonded to so that future additions and repairs are better supported (Figs. 6 and 7).

Implant dentistry is an excellent way to replace missing teeth. However, because natural teeth and implants move differently, one must be vigilant during the maintenance phase of implant dentistry. ♦

#### THE AUTHOR



*Dr. Izchak Barzilay is head of the division of prosthodontics and restorative dentistry, Mount Sinai Hospital, and assistant professor, faculty of dentistry, University of Toronto, Toronto, Ont. He also maintains a private practice (Prosthodontic Associates) limited to prosthodontics and implant dentistry in Toronto. Email: [ibarzilay@buildyoursmile.com](mailto:ibarzilay@buildyoursmile.com).*

## QUESTION 4

If I extract a tooth, can I use its crown as a pontic for a fixed prosthesis?

### Background

**B**onding an extracted crown in place was recommended to create an early form of resin-bonded prosthesis. Initially, composite resin was applied interproximally to temporarily secure the natural tooth pontic in place until healing could occur. The tooth would then be replaced by a more conventional restoration. In cases where an interim prosthesis is not available, use of the extracted crown is effective and expedient. Various factors, including the condition of the coronal portion of the extracted tooth, the condition of the neighbouring teeth (coronal and periodontal) and the ability to adequately isolate the region, are important considerations when deciding if this interim treatment modality is to be used.

For a longer-term restoration, the conventional bonded prosthesis (resin-bonded bridge or Maryland bridge) is an attractive option, in that it requires minimal tooth preparation and can be completed relatively quickly. The success of this type of restoration depends on adequate tooth preparation, adequate mechanical strength of the restoration, control of the forces placed on the final restoration and proper cementation procedures during placement of the restoration. With the development of bonding methods and materials to connect metals, ceramics, composite resins and tooth structure to each other, the resin-bonded application is not only effective but can also be esthetically pleasing, long lasting and functional. Simply bonding the crown of a tooth in place interproximally may serve as a short-term solution, but over time, this form of prosthesis will probably fail because of debonding and fracture.

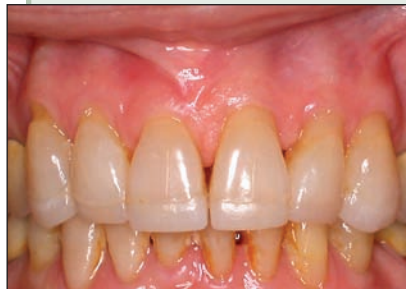This article presents a case in which a natural tooth crown was bonded to neighbouring teeth with the intention of its being used as a longer-term restoration.

### Clinical Case

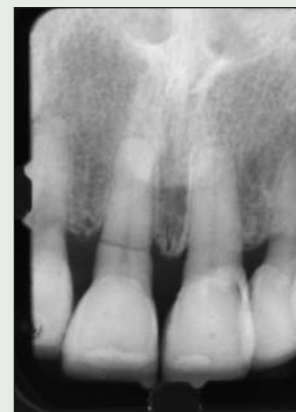A 70-year-old woman presented for dental treatment. After an extended assessment of vertical dimension, her posterior occlusion was restored with conventional porcelain-fused-to-metal restorations. The patient was concerned about re-creating the natural esthetics of her anterior teeth and asked whether a lingually based restoration could be fabricated to preserve the esthetics on the buccal surface of the anterior teeth. Minimal preparation of the lingual surfaces of the anterior teeth was performed, and lingual veneers with incisal coverage were fabricated (Empress, Ivoclar, Schaan, Lichtenstein) and bonded with a dual-cure composite resin cement (Nexus II, Kerr Corporation, Orange, Calif.) (Fig. 1).

Three years after placement of the original restorations, the root of the upper right central incisor was fractured while the patient was chewing on a popcorn kernel (Fig. 2). The root had to be removed, and replacement of the tooth was indicated. The patient was concerned about matching the shade and texture of a new restoration to the original (unrestored) buccal surface. The decision was made to use the natural crown and the lingual-veneered tooth as a pontic for the long-term restoration.

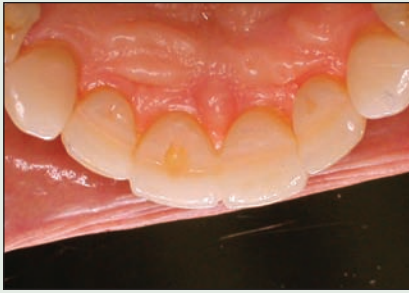A lingual groove-and-slot preparation was created through the cingula of the lingual veneers of the maxillary anterior teeth. A deeper preparation



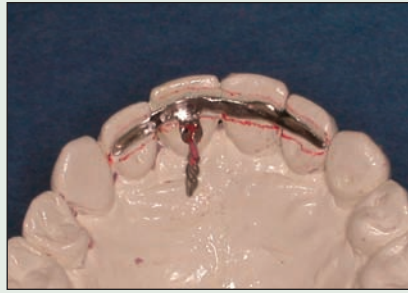
**Figure 1:** Buccal view of incisal extensions of the lingual veneers, which were placed to maintain new vertical opening.



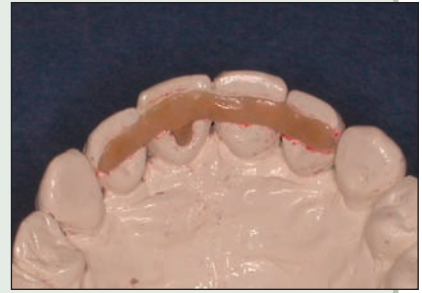**Figure 2:** Radiograph of tooth 11 showing a horizontal root fracture.



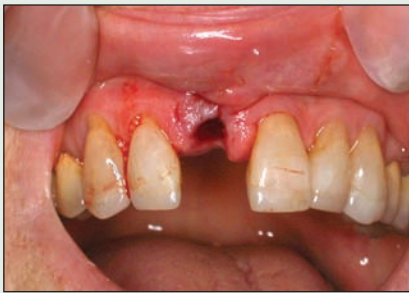**Figure 3:** Occlusal view of the lingual veneers, with a slot preparation and deeper preparation of tooth 11.



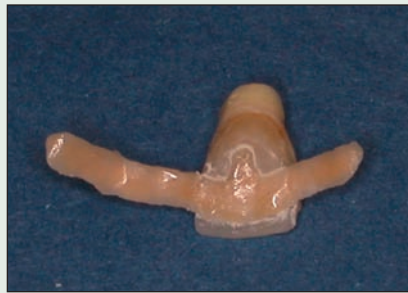**Figure 4:** Metal frame cast so as to be short of all margins.



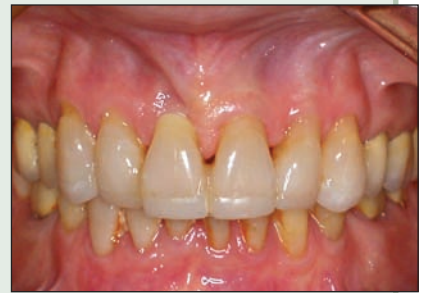**Figure 5:** Metal frame laminated with porcelain to fit all margins; it is ready for cementation.



**Figure 6:** Tooth 11 after extraction, ready for bonding of the restoration.



**Figure 7:** The extracted crown connected to the metal frame, ready for bonding to the abutment teeth.



**Figure 8:** The prosthesis bonded in place; esthetics have been maintained.

into the fractured tooth allowed for more accurate indexing of the future prosthesis (Fig. 3). A polyether impression was made, and a nonprecious metal frame was fabricated (Press Alloy, Swiss NF, Toronto, Ont.). This frame was designed to be short of the prepared margins (Fig. 4). The frame was opaqued and waxed to create the ideal shape for the retainer (i.e., to fit the prepared channel) and porcelain was applied using the pressing method (SNF Press Ceram, Swiss NF) and finished (Fig. 5). This porcelain-fused-to-metal frame was tried in, the fit was assessed, and the ceramic portion was etched with hydrofluoric acid (Pulpdent Corp, Watertown, Mass.).

The region of tooth 11 was anesthetized, and the crown and root were extracted atraumatically; good hemostasis was achieved (Fig. 6). The crown portion was swabbed with 100% ethanol, and a composite resin plug was bonded to the underside of the crown to seal the internal chamber of the crown. The lingual surface of the crown (lingual ceramic veneer) was then etched with hydrofluoric acid for 5 minutes. The etched porcelain-fused-to-metal frame was then silanated, as was the crown,

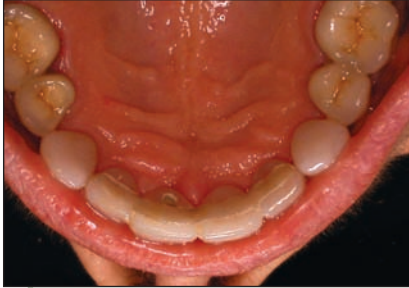
and the 2 units were bonded together with a dual-cure composite resin cement (Nexus II) (Fig. 7).

The anterior teeth were then isolated using a rubber dam. The prepared lingual surfaces were cleaned with pumice, rinsed and dried. The lingual veneered surfaces were etched with hydrofluoric acid, and both the new restoration and the intra-oral veneers were treated with silane and cemented with C&B Metabond (Parkell, Farmingdale, N.Y.). Occlusion was verified, and oral hygiene instructions were given (Figs. 8–10).

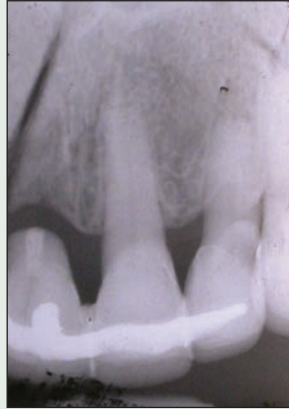## Discussion

This report has described use of a natural tooth pontic in an esthetically demanding area. Using the natural tooth maintains the overall esthetics and makes it simpler to ensure the ideal contour and shade. However, there is some concern about the longevity of the shade. Hydration of this type of pontic is no different than for an endodontically treated tooth, and as such the colour should not change dramatically (Fig. 11). In the case described here, the design of the previous restoration

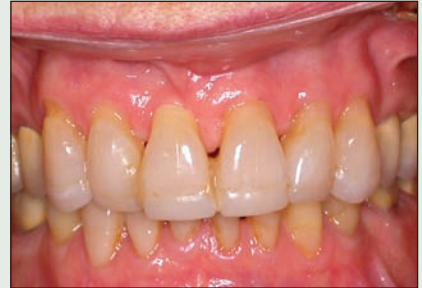



**Figure 9:** Occlusal view of the prosthesis in place.



**Figure 10:** Anterior periapical radiograph showing the restoration in place.



**Figure 11:** Follow-up photograph of the region 12 months after treatment, showing excellent healing and colour stability.

made it difficult to achieve an esthetically pleasing result, and use of the extracted crown solved many potential esthetic problems. When the tooth was extracted, the crown was shaped to create an ovate pontic and thus maintain gingival esthetics. Since both abutment teeth were periodontally sound, a fixed restoration was considered ideal.

In this case, a metal-based supporting structure strengthened the prosthesis and allowed for a longer-term restoration. The patient was also interested in minimizing the amount of metal that was visible once the restoration was positioned. This was accomplished by laminating the metal with porcelain using a pressing system to develop an accurate contour. A nonprecious metal was used because of its strength in thin section and the

capacity for chemical and mechanical bonding to the alloy.

In conclusion, it is possible to use extracted teeth as pontics for either short-term or long-term restorations. Key elements are the addition of a metal supporting component, adequate tooth preparation and bonding of all materials to each other under isolated conditions (rubber dam). ✦

#### THE AUTHOR



*Dr. Izchak Barzilay is head of the division of prosthodontics and restorative dentistry, Mount Sinai Hospital, and assistant professor, faculty of dentistry, University of Toronto, Toronto, Ont. He also maintains a private practice (Prosthodontic Associates) limited to prosthodontics and implant dentistry in Toronto. Email: [ibarzilay@buildyoursmile.com](mailto:ibarzilay@buildyoursmile.com).*