

Locator Attachments as an Alternative to Ball Attachments in 2-Implant Retained Mandibular Overdentures

Onur Geckili, Med Dent; Hakan Bilhan, Dr Med Dent; Tayfun Bilgin, Dr Med Dent

“Clinical Showcase” is a series of pictorial essays that focus on the technical art of clinical dentistry. The section features step-by-step case demonstrations of clinical problems encountered in dental practice. If you would like to contribute to this section, contact editor-in-chief Dr. John O’Keefe at jokeefe@cda-adc.ca.

The classical treatment plan for the edentulous patient involves creation of maxillary and mandibular complete dentures. However, people who wear conventional dentures often report discomfort or frank pain, lack of retention and stability, and difficulty eating. These complaints relate mostly to mandibular complete dentures.¹ Osseointegrated implants provide a reasonable solution for problems with these dentures.² Implant-retained mandibular overdentures are associated with significantly greater general satisfaction, comfort, stability and ability to chew than conventional mandibular dentures.³ Two-implant retained mandibular overdentures are a routine therapy modality supported by the McGill consensus.⁴

Previous authors have reported less bone atrophy in edentulous mandibles into which implants have been placed; as such, implants are also important for bone preservation.⁵⁻⁷

Several attachment systems are available for 2-implant retained mandibular overdentures, specifically ball, bar and magnet attachments and rigid or nonrigid telescopic copings.⁸ Because of their simplicity of application and low price, ball attachments are preferred.^{9,10} Although there are conflicting reports,¹¹⁻¹⁴ ball attachments often have better scores for retention, soft-tissue or mechanical complications, and patient satisfaction than bar and magnet attachments.^{6,15-20}

When the interarch distance or the height of the denture is inadequate for placing ball attachments, several problems may

occur, such as overcontoured prosthesis, excessive occlusal vertical dimension, fractured teeth adjacent to the attachments, separation of attachments from the denture, fracture of the prosthesis, and overall patient dissatisfaction.²¹ In these situations, locator attachments (Astra Tech, Mölndal, Sweden) or micro-head extracoronar resilient attachments (ERA; Sterngold ImplaMed, Attleboro, Mass.) can be a suitable alternative to ball attachments because of their low profile.^{21,22}

This article presents the chairside processing technique (direct method) for a low-profile attachment system (Astra Tech locator housing and male attachments) as an alternative to ball attachments. This locator system contains locator abutments suitable for all Astra Tech fixture diameters, a locator process kit, a spacer, a processing cap and 4 retention inserts in different colours (representing different

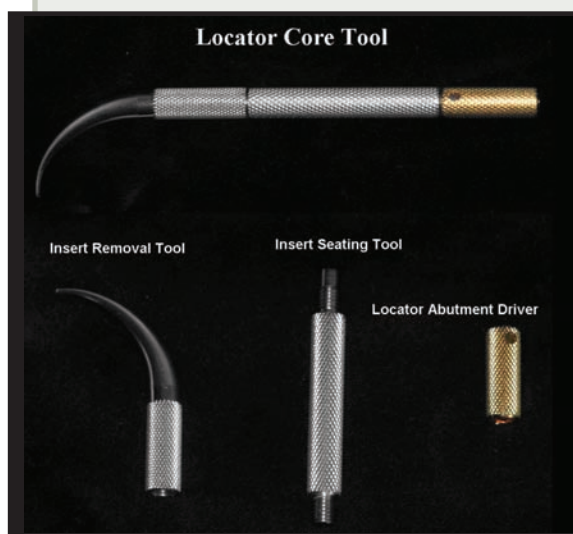

Figure 1: Locator core tool, which has 3 parts.

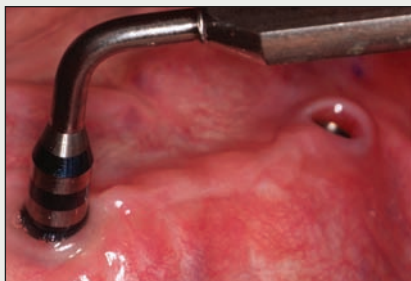

Figure 2: Depth gauge for measuring the gingival height.

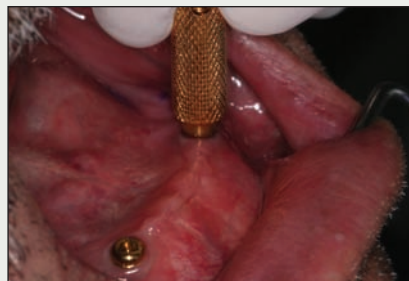

Figure 3a: Locator abutment driver for positioning and hand-tightening the locator abutment.

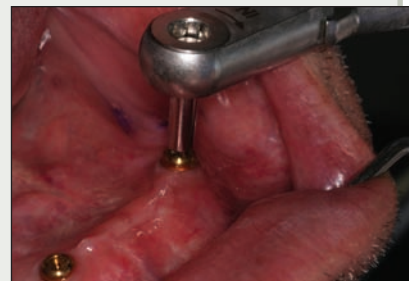

Figure 3b: Torque wrench for final tightening.

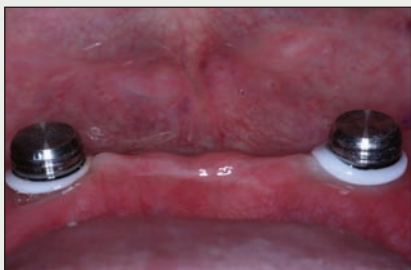

Figure 4: White spacer rings and housings positioned over the locator abutments.

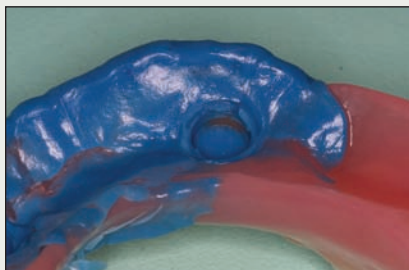


Figure 5a: Scraped parts can be seen after the elastomeric impression has set.

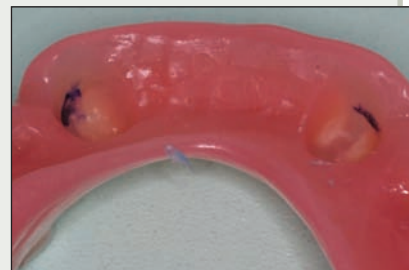

Figure 5b: Scraped parts are painted with an indelible pencil.

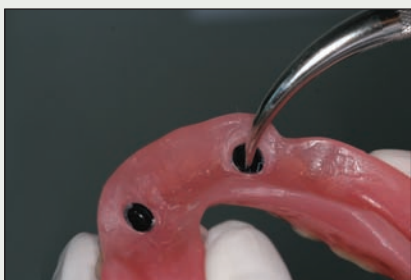


Figure 6: Black processing male attachments are removed with the curved insert removal tool.

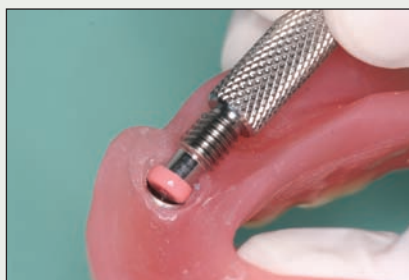

Figure 7a: A pink replacement insert is seated into the metal housing.

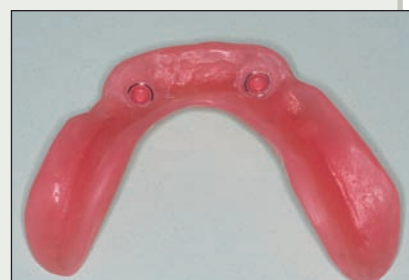

Figure 7b: Final view of the overdenture.

retention forces) and a locator core tool, which consists of 3 parts (**Fig. 1**): a curved insert removal component for catching and pulling the nylon insert out of the permanent metal housing (upper part of tool); an insert seating component for seating a replacement insert into the metal housing (middle part of tool); and the locator abutment driver, for positioning and tightening the abutment (lower part of tool).

Step-by-Step Procedure

1. Remove the healing abutments with the hexagonal screwdriver.
2. Measure the gingival height with the depth gauge, and choose the appropriate locator abutment (**Fig. 2**).
3. Position the locator abutment, hand-tighten the abutment with the locator abutment driver, and then tighten with the torque wrench (**Figs. 3a and 3b**).
4. Place a white spacer ring over the head of each abutment to block the area under the housing from acrylic flow.
5. Place the housing over the abutments (**Fig. 4**).
6. Remove approximately 4 mm of acrylic from the corresponding parts of the denture with a

- round bur (#140. 277. 040; Acurata Imperial, Thurmansbang, Germany).
7. Place a small amount of freshly mixed light-body elastomeric impression material (Alphasil Perfect Dünn and activator, Omicron, Lindlar, Germany) into the relieved parts of the denture. Insert the denture into the mouth. After the impression sets, remove the denture and inspect for show-through (Fig. 5a). Mark the scraped parts with an indelible pencil (Adel Kalemcilik, Istanbul, Turkey) and remove the elastomeric impression material from the denture (Fig. 5b). Relieve the parts that have been marked with indelible pencil using the same round bur. Repeat this procedure until no scraped parts can be seen.
 8. Mix and apply autopolymerizing acrylic resin (Vertex, Vertex-Dental BV, Zeist, the Netherlands) into the relief areas of the denture. Insert the denture into the mouth, and instruct the patient to close the mouth in centric occlusal position. After the acrylic resin has polymerized, remove the denture from the mouth and clean the excessive acrylic from around the attachments with a small round bur (#175. 001. 050; Acurata Imperial).
 9. Remove the black processing male attachments with the curved insert removal tool (Fig. 6).
 10. Seat the appropriate replacement insert into the metal housing with the insert seating tool (Figs. 7a and 7b).
 11. Perform a try-in, instructing the patient about seating and removal of the overdenture.

Conclusion

Chairside processing and other advantages of the Astra Tech locator housing and male attachments over other attachment systems have been described in this report. The system includes 4 insert retention parts (in different colours), providing different retention forces. Because of the low-profile design, there is less acrylic to be removed from the denture base than is the case with application of ball attachments. The direct placement technique is similar to that for ball and magnet attachments. Although in vitro studies have revealed retention characteristics,^{16,23} long-term data assessing the success rate of this locator system are lacking. Further studies with more patients are needed to evaluate the long-term mechanical stability of this type of attachment system and patient satisfaction. ✦

THE AUTHORS



Dr. Geckili is a research assistant in the department of removable prosthodontics, Istanbul University, Istanbul, Turkey. Email: geckili@istanbul.edu.tr.



Dr. Bilhan is a research assistant in the department of removable prosthodontics, Istanbul University, Istanbul, Turkey.



Dr. Bilgin is a professor in the department of removable prosthodontics, Istanbul University, Istanbul, Turkey.

The authors have no declared financial interests.

References

1. Doundoulakis JH, Eckert SE, Lindquist CC, Jeffcoat MK. The implant-supported overdenture as an alternative to the complete mandibular denture. *J Am Dent Assoc* 2003; 134(11):1455-8.
2. Davis DM, Packer ME. Mandibular overdentures stabilized by Astra Tech implants with either ball attachments or magnets: 5-year results. *Int J Prosthodont* 1999; 12(3):222-9.
3. Thomason JM, Lund JP, Chehade A, Feine JS. Patient satisfaction with mandibular implant overdentures and conventional dentures 6 months after delivery. *Int J Prosthodont* 2003; 16(5):467-73.
4. Feine JS, Carlsson GE, Awad MA, Chehade A, Duncan WJ, Gizani S, and others. The McGill consensus statement on overdentures. Mandibular two-implant overdentures as first choice standard of care for edentulous patients. Montreal, Quebec, May 24-25, 2002. *Int J Oral Maxillofac Implants* 2002; 17(4):601-2.
5. Sennerby L, Carlsson GE, Bergman B, Warfvinge J. Mandibular bone resorption in patients treated with tissue-integrated prostheses and in complete-denture wearers. *Acta Odontol Scand* 1988; 46(3):135-40.
6. Jemt T, Chai J, Harnett J, Heath MR, Hutton JE, Johns RB, and others. A 5-year prospective multicenter follow-up report on overdentures supported by osseointegrated implants. *Int J Oral Maxillofac Implants* 1996; 11(3):291-8.
7. Naert I, Gizani S, Vuylsteke M, van Steenberghe D. A 5-year randomized clinical trial on the influence of splinted and unsplinted oral implants in the mandibular overdenture therapy. Part I: Peri-implant outcome. *Clin Oral Implants Res* 1998; 9(3):170-7.
8. Naert I, Alsaadi G, Quirynen M. Prosthetic aspects and patient satisfaction with two-implant-retained mandibular overdentures: a 10-year randomized clinical study. *Int J Prosthodont* 2004; 17(4):401-10.
9. Takanashi Y, Penrod JR, Lund JP, Feine JS. A cost comparison of mandibular two-implant overdenture and conventional denture treatment. *Int J Prosthodont* 2004; 17(2):181-6.
10. Naert I, Quirynen M, Theuniers G, van Steenberghe D. Prosthetic aspects of osseointegrated fixtures supporting overdentures. A 4-year report. *J Prosthet Dent* 1991; 65(5):671-80.
11. Walton JN. A randomized clinical trial comparing two mandibular implant overdenture designs: 3-year prosthetic outcomes using a six-field protocol. *Int J Prosthodont* 2003; 16(3):255-60.
12. Walton JN, MacEntee MI, Glick N. One-year prosthetic outcomes with implant overdentures: a randomized clinical trial. *Int J Oral Maxillofac Implants* 2002; 17(3):391-8.
13. Timmerman R, Stoker GT, Wismeijer D, Oosterveld P, Vermeeren JI, van Waas MA. An eight-year follow-up to a randomized clinical trial of participant satisfaction with three types of mandibular implant-retained overdentures. *J Dent Res* 2004; 83(8):630-3.
14. Naert I, Gizani S, Vuylsteke M, Van Steenberghe D. A 5-year prospective randomized clinical trial on the influence of splinted

- and unsplinted oral implants retaining a mandibular overdenture: prosthetic aspects and patient satisfaction. *J Oral Rehabil* 1999; 26(3):195–202.
15. Tokuhsa M, Matsushita Y, Koyano K. In vitro study of a mandibular implant overdenture retained with ball, magnet, or bar attachments: comparison of load transfer and denture stability. *Int J Prosthodont* 2003; 16(2):128–34.
16. Chung KH, Chung CY, Cagna DR, Cronin RJ. Retention characteristics of attachment systems for implant overdentures. *J Prosthodont* 2004; 13(4):221–6.
17. Burns DR, Unger JW, Elswick RK, Giglio JA. Prospective clinical evaluation of mandibular implant overdentures: Part II — Patient satisfaction and preference. *J Prosthet Dent* 1995; 73(4):364–9.
18. Petropoulos VC, Smith W, Kousvelari E. Comparison of retention and release periods for implant overdenture attachments. *Int J Oral Maxillofac Implants* 1997; 12(2):176–85.
19. Cune MS, de Putter C, Hoogstraten J. Treatment outcome with implant-retained overdentures: Part II — Patient satisfaction and predictability of subjective treatment outcome. *J Prosthet Dent* 1994; 72(2):152–8.
20. Gotfredsen K, Holm B. Implant-supported mandibular overdentures retained with ball or bar attachments: a randomized prospective 5-year study. *Int J Prosthodont* 2000; 13(2):125–30.
21. Lee CK, Agar JR. Surgical and prosthetic planning for a two-implant-retained mandibular overdenture: a clinical report. *J Prosthet Dent* 2006; 95(2):102–5.
22. Alsiyabi AS, Felton DA, Cooper LF. The role of abutment-attachment selection in resolving inadequate interarch distance: a clinical report. *J Prosthodont* 2005; 14(3):184–90.
23. Rutkunas V, Mizutani H, Takahashi H. Evaluation of stable retentive properties of overdenture attachments. *Stomatologija* 2005; 7(4):115–20.