

# Lawsuit Against a Dentist Related to Serious Ocular Infection Possibly Linked to Water from a Dental Handpiece

Jean Barbeau, PhD

## Contact Author

Dr. Barbeau  
Email: [jean.barbeau@umontreal.ca](mailto:jean.barbeau@umontreal.ca)



## ABSTRACT

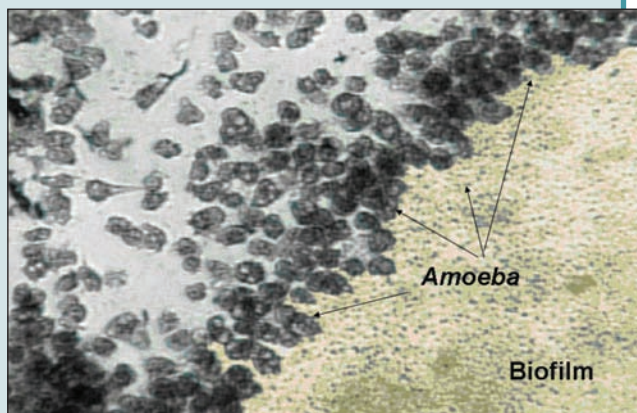
This case report highlights the risks that may be associated with amoebae in the water of a dental unit. A woman with contact lenses visited her dentist for replacement of a bridge. During the treatment, a stream of water was directed from the handpiece into her right eye. Because of subsequent pain in the eye, the patient consulted several ophthalmologists, who discovered abrasive lesions of the cornea and inflammation. Despite antibacterial and anti-inflammatory treatments, the patient's visual acuity declined gradually over a period of several days. A microbiological examination nearly 2 months later revealed amoebae in corneal samples. A lawsuit against the dentist was initiated. Although a causal relation with the dental treatment was rejected by the judge in this case, high numbers of amoebae in the water of dental units can present a risk if a patient with pre-existing corneal lesions is splashed. According to the precautionary principle, complete evidence of risk does not have to exist to institute measures to protect individuals and society from that risk. This case reinforces the importance of having patients wear safety glasses during dental treatments and of dental personnel draining the waterlines of dental units, as recommended by the Canadian Dental Association.

For citation purposes, the electronic version is the definitive version of this article: [www.cda-adc.ca/jcda/vol-73/issue-7/618.html](http://www.cda-adc.ca/jcda/vol-73/issue-7/618.html)

The presence of high concentrations of microorganisms in the water of dental units is a phenomenon that is now recognized by the scientific community; however, knowledge about the risks of infection associated with this phenomenon and the ways to decontaminate the tubing of dental units has not advanced a great deal over the past 5 years. During that time, there has been no proliferation of infections, and documented cases of infections linked to the water of dental units have been rare.<sup>1,2</sup> There are 4 possible reasons for the low number of documented cases: such cases truly are rare; in instances where litigation

is undertaken, the matter is settled out of court, without being made public; cases that have occurred have not been published; or it has been difficult to correlate probable cases with dental treatments.

Bacterial pathogens (*Pseudomonas*, *Legionella*, *Mycobacterium* and others) are thought to be the primary source of risk, but the presence of amoebae in freshwater also represents a potential risk. Infections caused by freshwater amoebae are rare but serious and may be fatal if they reach the brain.<sup>3</sup> These infections include keratitis (which may be caused by *Acanthamoeba*) and meningoenophthalmitis



**Figure 1:** In this micrograph obtained in the author's laboratory, a group of amoebae are feeding on the isolated biofilm of a dental unit (magnification 200x).

(caused by *Acanthamoeba* sp. or *Naegleria fowleri*, among others). These common protozoa can be found in bodies of natural water, swimming pools, municipal water systems, contact lens cases, and dental units and their suction systems. Bacterial biofilms may be the source of increased populations of amoebic protozoa in the tubing of dental units<sup>4</sup> (Fig. 1). The concentration of organisms in these biofilms is almost 300 times higher than what is found in tap water.<sup>4</sup>

This article reports a case of infection possibly related to water in a dental unit with the following aims:

1. to alert readers to the risk associated with a high concentration of microorganisms, particularly amoebae, in the water of dental units
2. to emphasize the difficulty of establishing a causal relation for an infection that may be due to a dental treatment
3. to better understand the importance of managing the risk of infection, even if that risk is only theoretical
4. to explain the “precautionary principle,” which underpins the rules of risk management.

### Case Report

A patient visited the dentist for replacement of the bridge on her mandible. On the day of treatment (designated as **day 1**), the patient was wearing prescription glasses, which she removed for the treatment. She did not wear safety glasses for the period of the treatment. About 45 minutes after the treatment began, the assistant inadvertently activated the air rotor handpiece while the handpiece was about 8 cm from the patient's face. The patient was hit with a stream of water and described the sensation as an impact to her right eye. She wiped her face, and the dentist continued working.

After returning home, the patient felt slight discomfort in the right eye. A few hours later, the pain had increased and the eye was red. The pain increased further overnight, to the extent that in the morning (**day 2**), she visited a medical clinic. With the help of an ophthalmoscope, the physician diagnosed acute conjunctivitis. He prescribed corticosteroids and gentamicin drops and suggested that she wear tinted glasses. This treatment provided temporary relief.

Two days later (**day 4**), the pain returned and was very intense. The next day (**day 5**) the patient went back for another consultation with a physician, who, using an ophthalmoscope and fluorescent dye, found 3 small abrasions on the cornea of the right eye and diagnosed a traumatic ulcer. A subsequent examination in a hospital ophthalmological clinic revealed visual acuity of 20/25 in both eyes and irregular healing of the abrasions. Occlusion treatment was prescribed.

Two days later (**day 7**), the occlusion eye patch was removed in response to signs of healing. On **day 8**, another examination revealed that visual acuity had decreased to 20/70 in the infected eye; signs of postabrasion keratitis were visible. Five days later (**day 13**), the condition of the cornea had worsened. On **day 14**, an inflammation of the right iris was observed. Given the increasing pain, the ocular secretions were sampled for culture on **day 32**. On **day 57**, the protozoan *Acanthamoeba* sp. was identified on the basis of the culture results.

Treatment for this serious infection is long and difficult. Four years later, the patient was still experiencing symptoms (such as pain, photophobia and blurred vision). With corrected vision, visual acuity in the right eye was 20/200. The treating ophthalmologist indicated that full rehabilitation could be achieved through removal of the cataract, insertion of a hard corneal lens and possibly a corneal transplant, but the patient has not undertaken this course of action.

### Discussion

In the case presented here, the patient's eye was splashed with water from the dental unit during routine treatment. She later experienced discomfort, which culminated in a serious ocular infection. This case raises 3 key questions:

1. Did the dentist err through his assistant's inadvertent action?
2. Can a causal relation be established between the infection and the incident in the dental office?
3. Can this link be considered probable relative to the other risk factors?

In response to the first question, 3 possible errors can be identified: the dentist did not ask the patient to wear safety glasses during the dental treatment, the handpiece was activated before being placed in the mouth or

the dentist did not drain the dental unit's waterlines as recommended by dental associations. With regard to the first possible error, it is strongly recommended that patients wear safety glasses during dental treatments,<sup>5</sup> and there was clearly a deficiency in this regard. With regard to the second possible error, the fact that the handpiece was inadvertently activated before being placed in the patient's mouth cannot be considered an error because it was not a breach of protocol. With regard to the third possible error, staff in dental clinics should drain the waterlines of each dental unit every morning for several minutes and for 30 to 45 seconds between patients. Doing so reduces the concentrations of bacteria and amoebae in the water by 96% and 66%, respectively.<sup>4,6</sup> In this case, it is not known whether the tubing was drained before treatment for this patient began; however, the dental unit and its handpiece had been in use that day for about 2 hours before the incident occurred. It is therefore likely that the concentration of microorganisms in the water had been substantially reduced from overnight levels.

The suggestion of a causal relation between the infection and the incident in the dental office appeared "attractive," according to the judge who heard the legal case against the dentist: the patient had no discomfort in her eye before visiting the dentist; water was sprayed on her during the appointment, apparently with enough force to cause an unpleasant reaction; the symptoms appeared shortly after the incident; and the ocular infection was caused by a species of *Acanthamoeba*, a protozoan reported to inhabit the tubing of dental units.<sup>4,7,8,12</sup>

The key issue, however, should be establishing whether the causal relation is *probable*. The patient's other risk factors must therefore be examined, including the fact that she usually wore contact lenses, which, according to her testimony in the case, she cleaned with tap water and neglected to disinfect regularly, contrary to well-recognized directions for contact lens care. The literature indicates that the most widely recognized risk factor for keratitis caused by *Acanthamoeba* is the wearing of contact lenses and that using tap water to clean them and neglecting to regularly disinfect the lens case are risky practices.<sup>9,10</sup>

From an epidemiologic standpoint, medicine does not recognize the water in dental units as a delivery mechanism for *Acanthamoeba*. Therefore, without rejecting the "possibility" that the patient might have been infected when accidentally splashed at the dentist's office, the ophthalmologist expert for the defence was able to rely only on his experience, the abundant scientific and medical literature, and his conviction that a spray from the handpiece would not be powerful enough to cause the microlesions that were observed and that paved the way for the *Acanthamoeba* infection.

As one expert witness for the claimant pointed out, there is an important issue of bias at the heart of this case.

In fact, the arguments in favour of the risk represented by wearing contact lenses are naturally overrepresented in the literature, since the number of contact lens wearers in the world far surpasses the number of people who have been splashed in the eyes with water from a dental unit. However, a close review of the literature may shed some interesting light on the subject. When looking at a large population subjected to a hitherto unrecognized risk factor, the interpretation of the epidemiologic data can change dramatically. In a controlled epidemiologic study by Meier and others,<sup>11</sup> flooding in certain counties of the state of Iowa was associated with a 10-fold increase in the number of cases of keratitis caused by *Acanthamoeba* relative to counties that had not experienced flooding and in which the wearing of contact lenses was the only identifiable risk factor. In other words, in a purely hypothetical situation where a large number of patients is subjected to ocular inoculation from the water of a dental unit contaminated with *Acanthamoeba*, the data may be expected to indicate that this means of infection is at least as probable as that represented by the wearing of contact lenses.

However, such speculation could not be substantiated by publications or by case law. Unable to rule on the basis of speculation, the judge rejected the litigation presented, stating that a causal relation between the ocular infection and the incident during dental treatment had not been demonstrated. The patient's testimony lent weight to the argument that her contact-lens care practices might have been the source of the problem. Ultimately, it could not be established that the error or errors committed during the dental treatment were the cause of the patient's ocular infection.<sup>12</sup>

### The Precautionary Principle Applied to Infection Control

The case presented here is interesting from several perspectives and can be used to illustrate one of the most controversial concepts in the application of infection control rules in dentistry: the notion of risk. Over the past 30 years, dentistry has witnessed an explosion of guidelines and recommendations aimed at protecting patients and oral care providers against the transmission of infections. Major changes have been implemented in response to a variety of incidents, notably the following:

- the documented transmission of hepatitis B virus through dental treatments,<sup>13</sup> which finally legitimized the wearing of gloves and use of vaccinations (1970s and early 1980s)
- the discovery of HIV (in 1981), which led to the establishment of universal precautions in 1987<sup>14</sup>
- the case of a Florida dentist who may have transmitted HIV to 5 of his patients (late 1980s and early 1990s),<sup>15,16</sup> which received a great deal of media coverage and led to the strengthening of the guidelines on sterilizing handpieces.

**Box 1** Recommendations for the waterlines of dental units<sup>2</sup>

- Avoid heating the water in the dental unit.
- Every morning, remove the handpieces, the air and water syringes, and the end fitting on the ultrasound scaler and then flush each waterline with fresh water.
- After each patient, turn on the handpieces at high speed for 20 to 30 seconds to evacuate all air and water.
- Use sterile water or a sterile saline solution to rinse surgical wounds or to cut bones during surgery.
- When using bottled water or another water supply system, follow the manufacturer's instructions for daily and weekly maintenance.

Each of these events and the changes it engendered had undesirable effects: increased costs and more time spent managing infection risks, increased prevalence of allergies to latex, damage to instruments and equipment, and increased complexity of some tasks.

When concerns about the water in dental units were first raised in the 1990s, the dental profession was still battling with the constraints imposed by universal precautions and the sterilization of handpieces. For many in the dental community, the lack of a scientifically demonstrated risk raised questions about the legitimacy of the various recommendations disseminated by dental associations and regulatory bodies (e.g., Centers for Disease Control and Prevention).<sup>17-20</sup> The theoretical risk was deemed negligible. But can a negligible risk be ignored if reasonable means are available to reduce it?

The precautionary principle recognizes the limitations of scientific models in accurately describing complex problems that concern damage to the environment or risks to health. According to the precautionary principle, complete evidence of risk does not have to exist to institute measures to protect individuals and society from that risk.<sup>21,22</sup> This principle should be balanced by the concept of proportionality in the proposed solution to the risk in question.

The following example illustrates the precautionary principle. Although in the year 2000 it was recognized that bovine spongiform encephalopathy (a variant of Creutzfeldt-Jakob disease [vCJD]; also known as mad cow disease) could be transmitted to humans, the risks associated with blood transfusions were still only theoretical. Various government authorities in Canada had to assess these theoretical risks and decide how to protect Canadian blood banks and the population. The experts focused on the hypothetical risks of transmitting a fatal disease to develop a policy for managing blood donations that would inevitably lead to refusal of certain donors who were not infected with vCJD. The experts had to take into consideration the fact that the policy would be unacceptable if it reduced the supplies to blood banks below a crit-

ical level. Previous experience had shown that Canada could handle a 3% decrease in blood donations without endangering the population. On an actuarial basis, it was therefore decided to refuse donations from anyone who had spent at least 6 months in the United Kingdom between 1980 and 1996. This policy led to an estimated 3% reduction in donations.<sup>23</sup> Thus, to protect the population from a risk that had never been scientifically demonstrated (but that would be fatal in 100% of cases if it did occur), the experts accepted drawbacks that were deemed reasonable in comparison. We know today that vCJD can be transmitted through transfusions.

The precautionary principle can also be applied to the case reported here. Allocating a certain amount of time to drain the waterlines of all dental units (**Box 1**) and having patients wear safety glasses are reasonable measures to reduce a risk of infection that is “possible” but not yet scientifically proven. The inconveniences associated with applying the recommendations, as well as the perception that the risk is negligible, cannot be invoked as valid reasons for failing to comply with these recommendations.

This case has underlined the importance of complying with recommendations for maintaining dental unit waterlines and having patients wear safety glasses to prevent infections and avoid litigation. ♦

**THE AUTHOR**



*Dr. Barbeau is a microbiologist and professor, faculty of dentistry and faculty of medicine, University of Montreal, Montreal, Quebec.*

*The views expressed are those of the author and do not necessarily reflect the opinions or official policies of the Canadian Dental Association.*

*This article has been peer reviewed.*

**References**

1. Martin MV. The significance of the bacterial contamination of dental unit water systems. *Br Dent J* 1987; 163(5):152-4.
2. Atlas RM, Williams JF, Huntington MK. Legionella contamination of dental-unit waters. *Appl Environ Microbiol* 1995; 61(4):1208-13.
3. Schuster FL, Visvesvara GS. Free-living amoebae as opportunistic and non-opportunistic pathogens of humans and animals. *Int J Parasitol* 2004; 34(9):1001-27.
4. Barbeau J, Buhler T. Biofilms augment the number of free-living amoebae in dental unit waterlines. *Res Microbiol* 2001; 152(8):753-60.
5. Petty TL. Infection prevention and control in the dental office: an opportunity to improve safety and compliance. Canadian Dental Association. Committee on Clinical and Scientific Affairs; 2006.
6. Barbeau J, Tanguay R, Faucher E, Avezard C, Trudel L, Cote L, and other. Multiparametric analysis of waterline contamination in dental units. *Appl Environ Microbiol* 1996; 62(11):3954-9.

7. Michel R, Borneff M. [The significance of amoebae and other protozoa in water conduit systems in dental units]. *Zentralbl Bakteriol Mikrobiol Hyg [B]* 1989; 187(4-6):312–23. [Article in German].
8. Michel R, Just HM. [Acanthamoebae, Naegleria and other free-living Amoebae in cooling and rinsing water of dental treatment units]. *Zentralbl Bakteriol Mikrobiol Hyg [B]* 1984; 179(1):56–72. [Article in German].
9. Seal DV. Acanthamoeba keratitis update — incidence, molecular epidemiology and new drugs for treatment. *Eye* 2003; 17(8):893–905.
10. Marciano-Cabral F, Cabral G. Acanthamoeba spp. as agents of disease in humans. *Clin Microbiol Rev* 2003; 16(2):273–307.
11. Meier PA, Mathers WD, Sutphin JE, Folberg R, Hwang T, Wenzel RP. An epidemic of presumed Acanthamoeba keratitis that followed regional flooding. Results of a case-control investigation. *Arch Ophthalmol* 1998; 116(8):1090–4.
12. Weissman-Fickler c. Bouzaglo, 2004 CanLII 646 (QC C.S.). Available from URL: [www.canlii.org/qc/jug/qccs/2004/2004qccs13261.html](http://www.canlii.org/qc/jug/qccs/2004/2004qccs13261.html).
13. Levin ML, Maddrey WC, Wands JR, Mendeloff AL. Hepatitis B transmission by dentists. *JAMA* 1974; 228(9):1139–40.
14. Centers for Disease Control (CDC). Recommendations for prevention of HIV transmission in health-care settings. *MMWR Morb Mortal Wkly Rep* 1987; 36(Suppl 2):1S–18S.
15. Palca J. The case of the Florida dentist. *Science* 1992; 255(5043):392–4.
16. CDC reports 6th Acer patient diagnosed with HIV. [News Update] *J Can Dent Assoc* 1993; 59(7):573.
17. Barbeau J. Waterborne biofilms and dentistry: the changing face of infection control. *J Can Dent Assoc* 2000; 66(10):539–41.
18. American Dental Association. ADA Positions and Statements. ADA Statement on Dental Unit Waterlines. July 2004. Available from URL : [www.ada.org/prof/resources/positions/statements/lines.asp](http://www.ada.org/prof/resources/positions/statements/lines.asp).
19. Organization for Safety and Asepsis Procedures. Dental unit waterlines: OSAP recommendations to clinicians. Available from URL : [www.osap.org/displaycommon.cfm?an=1&subarticlenbr=27](http://www.osap.org/displaycommon.cfm?an=1&subarticlenbr=27).
20. Kohn WG, Collins AS, Cleveland JL, Harte JA, Eklund KJ, Malvitz DM; Centers for Disease Control and Prevention (CDC). Guidelines for infection control in dental health-care settings – 2003. *MMWR Recomm Rep* 2003; 52(RR–17):1–61.
21. Wilson K, Wilson M, Hebert PC, Graham I. The application of the precautionary principle to the blood system: the Canadian blood system's vCJD donor deferral policy. *Transfus Med Rev* 2003; 17(2):89–94.
22. Foster KR, Vecchia P, Repacholi MH. Risk management. Science and the precautionary principle. *Science* 2000; 288(5468):979–81.
23. ElSaadany S, Giulivi A. Comprehensive risk assessment for vCJD in France and other countries for Canadians and the Canadian blood supply. Blood Borne Pathogens Division. Health Canada, June 26, 2000.