

The “Point of Care” section answers everyday clinical questions by providing practical information that aims to be useful at the point of patient care. The responses reflect the opinions of the contributors and do not purport to set forth standards of care or clinical practice guidelines. Readers are encouraged to do more reading on the topics covered. If you would like to contribute to this section, contact editor-in-chief Dr. John O’Keefe at jokeefe@cda-adc.ca.

QUESTION 1

Do missing teeth need to be replaced or is a “shortened dental arch” acceptable?

Background

For many years, it was thought that any missing tooth should be replaced,¹ although numerous clinicians and researchers questioned this opinion. Arnd Käyser was the first to coin the term “shortened dental arch” (SDA) to describe the concept of acceptable oral function with partial dentition.² Through a number of clinical studies, he and his co-workers came to the conclusion that many people could function without a full complement of teeth and that not all missing teeth require replacement.²⁻⁶ For many people, a functional dentition consists of as little as opposing anterior and premolar teeth.¹ In terms of a minimum number of teeth that patients need, Käyser and colleagues suggested that, in addition to anterior teeth, most people require at least 4 occlusal units of posterior teeth (1 pair of opposing, occluding premolars would be 1 occlusal unit, a pair of occluding molars would represent 2 occlusal units).² People with asymmetrical tooth loss

noticed a change in chewing function when they had fewer than 6 units (Figs. 1 and 2).²

The Effect of a Shortened Dental Arch on Oral Function

In general, studies comparing people with a full complement of teeth with those with SDAs have not demonstrated significant differences in ability to chew.¹ Among patients with the minimum recommended number of occlusal units, the insertion of a removable partial denture does not significantly improve oral function.³ According to some studies, the more teeth missing beyond the minimum, the more difficulty a person will have chewing.¹

In addition, those without molar support have not been shown to have a higher incidence of the signs and symptoms of temporomandibular disorders.⁵ Similarly, SDA has not been associated with significant discomfort, distress or occlusal wear.¹

Although it seems that most people can function acceptably with an SDA, this is not true

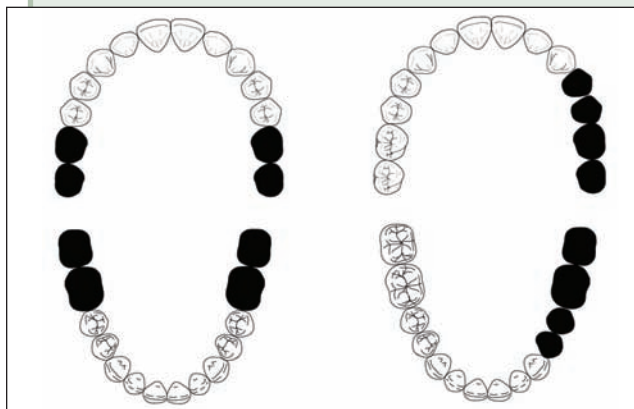


Figure 1: Patients with symmetrical tooth loss (left) normally require 4 occlusal units for acceptable function, while patients with asymmetrical tooth loss normally require 6 occlusal units (right). Darkened teeth are missing.

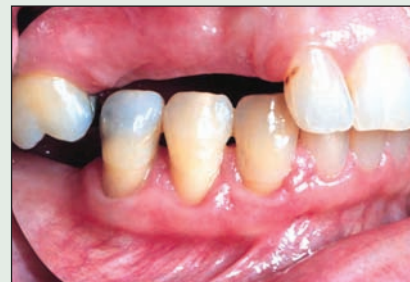

Figure 2: Here molar 16 and premolars 44 and 45 are unopposed; thus, they cannot be counted as occlusal units. Although overeruption of teeth, as seen here, can be a sequela to missing teeth, long-term studies have tended to show that occlusal changes are usually self-limiting and minor.¹

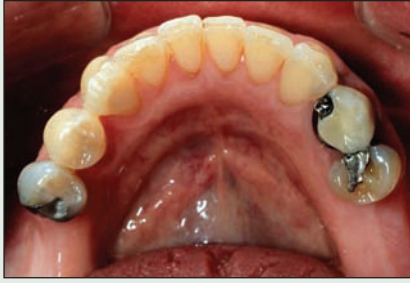

Figure 3: This patient has 4 premolars left. If they are opposed by maxillary teeth, there are no other complicating factors and the patient has no functional or esthetic complaints, then replacement of the missing teeth may not be necessary.

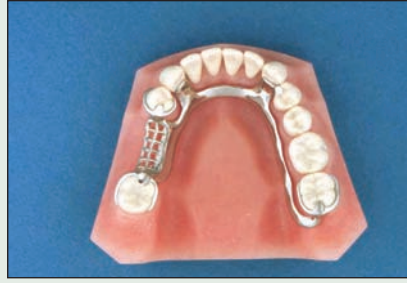

Figure 4: A prosthesis for replacement of only a few missing teeth may be unnecessary if the patient has no functional or esthetic complaints and there are no other reasons for replacement.

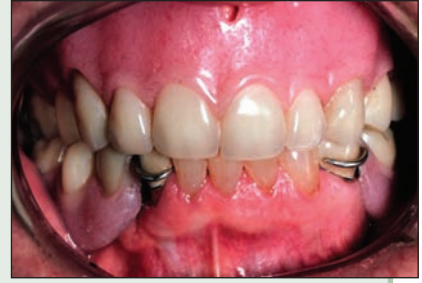

Figure 5: A maxillary complete denture against mandibular anterior teeth does not meet the minimum number (4) of occlusal units required for normal function. A mandibular prosthesis may be helpful for such patients.

for everyone: 7% to 20% of people with an SDA have reported that their chewing ability is hindered or that they had to change food preparation practices.¹

An SDA may also be associated with greater tooth migration and interdental spacing among patients younger than 40 years, although the migration was deemed small and clinically insignificant.¹ An SDA may also be associated with greater overeruption of teeth, although only 2% of such patients reported that it hindered their oral function.¹ People with SDA have been found to have more mobile teeth and lower alveolar bone levels. The combination of increased occlusal loading and existing periodontal disease probably represents a risk factor for further loss of teeth in these people. Patients with SDA probably also represent a high-risk group in terms of periodontal disease. Additional longitudinal studies have been recommended to study this relationship.¹

Shortened Dental Arch Options in Dental Practice

The SDA concept is increasingly accepted, although in some areas, it is not widely put into practice.¹ For dentists who provide services to patients with limited financial resources or patients who do not wish to acquire a prosthesis, the evidence provides a measure of reassurance that “no treatment” can be a sound option. Considering the implications of informed consent and the evidence collected by Käyser and others, it is prudent to ensure that treatment planning for all partially edentulous patients includes a discussion of the option of not replacing missing teeth and the pros and cons of this choice. For many patients, there

may be no need to replace missing teeth, unless they are unhappy with their ability to chew or their appearance (Figs. 3 and 4). For patients with 4 or more occlusal units who do not feel they can chew as well as they wish, replacements can still be fabricated (Fig. 5).

The SDA concept is based on the notion that patients have an adaptive capacity to function with missing teeth. This capacity clearly varies, and not all patients will feel they have optimum function with the same number of teeth. Future research will most likely improve our understanding of this clinically relevant subject. ♦

THE AUTHOR



Dr. Robert Loney is professor and head, division of removable prosthodontics, faculty of dentistry, Dalhousie University, Halifax, Nova Scotia. Email: robert.loney@dal.ca.

References

1. Kanno T, Carlsson GE. A review of the shortened dental arch concept focusing on the work by the Kayser/Nijmegen group. *J Oral Rehabil* 2006; 33(11):850–62.
2. Kayser AF. Shortened dental arches and oral function. *J Oral Rehabil* 1981; 8(5):457–62.
3. Witter DJ, van Elteren P, Kayser AF, van Rossum MJ. The effect of removable partial dentures on the oral function in shortened dental arches. *J Oral Rehabil* 1989; 16(1):27–33.
4. Witter DJ, de Haan AF, Kayser AF, van Rossum GM. A 6-year follow-up study of oral function in shortened dental arches. Part I: Occlusal stability. *J Oral Rehabil* 1994; 21(2):113–25.
5. Witter DJ, De Haan AF, Kayser AF, Van Rossum GM. A 6-year follow-up study of oral function in shortened dental arches. Part II: Craniomandibular dysfunction and oral comfort. *J Oral Rehabil* 1994; 21(4):353–66.
6. Witter DJ, van Palenstein Helderma WH, Creugers NH, Kayser AF. The shortened dental arch concept and its implications for oral health care. *Community Dent Oral Epidemiol* 1999; 27(4):249–58.

QUESTION 2

A patient new to my practice had a heart transplant a few years ago. What are the chief considerations in the management of this patient?

Background

Since the pioneering surgery of Dr. Christian Barnard and his team in the 1960s, human heart transplantation has evolved into a surgical procedure with a reasonably predictable outcome. Many heart transplant recipients now have a greatly increased life expectancy and are able to return to normal daily life. Although medically compromised, they are typically more stable from a cardiovascular perspective than patients with a history of severe cardiac disease.¹ With special care, routine dental or minor oral surgical procedures may be undertaken within the dental practice setting. However, for more invasive procedures, referral may be appropriate. There is no general systematic approach to dental treatment for these patients, making close liaison with the primary care physician and cardiologist essential.

A medical letter sent to the cardiologist and physician will help to confirm the patient's medical history and current medications. The letter should include proposed dental surgical treatment, along with the concentration and dose of drugs that will be used (e.g., local anesthetics, antibiotics and analgesics). The response to this correspondence will report the medical status and stability of the transplant and the fitness of the patient to undergo dental procedures in an office setting.

Management in the Dental Office

The transplanted heart is unable to respond to stress because of the lack of innervation; thus, it is

prudent to monitor blood pressure throughout the dental appointment. Furthermore, stress management measures, such as oral sedation, inhalation or sedation, may be indicated. The lack of sensory innervation of the transplanted heart also implies that, in the event of angina or myocardial infarction, the patient would not experience the retrosternal pain associated with both emergencies.²

The transplanted heart is nevertheless acutely sensitive to circulating catecholamines and is consequently affected by epinephrine-containing solutions.³ Among transplant recipients surviving for 5 years or longer, about 40% will have accelerated graft atherosclerosis. The cardiac complications that may arise include myocardial infarction, congestive heart failure, ventricular arrhythmias and sudden death.² It is good clinical practice to limit the amount of epinephrine necessary to maintain local anesthesia among these patients to 0.04 mg for dental procedures.⁴

The 2007 American Heart Association guidelines on antibiotic prophylaxis to prevent infective endocarditis do not advise blanket coverage for cardiac transplant patients.⁵ Unless a patient develops cardiac valvulopathy, is immunosuppressed or has been directed by the cardiology team to have antibiotic coverage, prophylaxis is unnecessary.

The Effects of Immunosuppressant Therapy

Heart transplant recipients generally take 3 types of immunosuppressant drugs to prevent rejection. Each class of drug has a distinct effect on

Table 1 Types of immunosuppressants

Class of drug	Example	Side effects	Effect on dental treatment	Precautionary measures
Antimetabolites	Azathioprine Rapamycin	Leukopenia, thrombocytopenia	Increase risk of bleeding and infection	Order blood work before invasive dental procedures (INR, CBC, ptt)
Steroids	Prednisone	Possible adrenal suppression	Impaired response to stress	Consult with physician to determine whether steroid supplementation is required
Antiproliferatives	Cyclosporine Tacrolimus	Adverse effects on kidney	Hypertension	Monitor blood pressure, notify physician if elevated

INR = international normalized ratio; CBC = complete blood count; ptt = partial thromboplastin time.

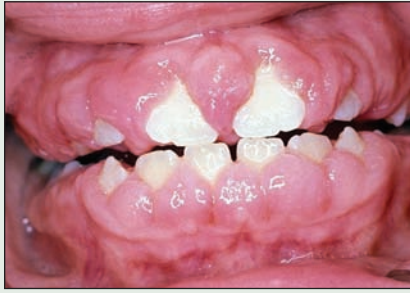

Figure 1: Cyclosporine-induced gingival hyperplasia.

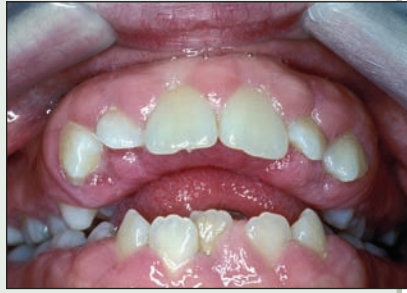

Figure 2: Gingival hyperplasia in a pediatric patient.

the immune system as well as important side effects that may affect dental treatment (Table 1).^{4,6}

Cyclosporine induces gingival hyperplasia. The predisposing factors are multifactorial and hyperplastic cases range from mild to severe (Fig. 1). The severity has been linked to oral hygiene status. Transplant patients benefit from a 3–4 month recall program of professional oral hygiene maintenance and education reinforcing the importance of personal oral hygiene measures. Not all patients develop gingival hyperplasia, but those affected acquire clinical manifestations within 6 months post-transplant.⁷ Following 36 months post-transplant, many affected patients show a gradual improvement in tissue overgrowth due to progressive reduction in the sensitivity of the periodontium to cyclosporine. Therefore, surgical intervention to manage gingival hyperplasia is delayed until 36 months has passed.⁷

Pediatric Considerations

Many of the treatment concerns described above apply to the pediatric transplant patient; however, some problems are specific to the pediatric patient. Children appear to be more susceptible to gingival hyperplasia than adults because of less attention to oral hygiene and a shorter period of administration of immunosuppressants.⁸ In children, hyperplastic tissue caps may develop over erupting teeth, which can delay, prevent or modify eruption patterns⁹ (Fig. 2). Surgical intervention is sometimes required; thus, regular monitoring of pediatric patients allows better treatment planning to assist the natural eruption of the permanent dentition. ➤

THE AUTHORS

Acknowledgements: We would like to thank Dr. Ian Matthew for his help with the preparation of the manuscript and Dr. Tom Daley for providing the photographs.



Dr. Krista D. Lee recently completed a residency in the General Practice Residency Program at the University of British Columbia, Vancouver General Hospital, Vancouver, British Columbia. Email: klee2006@dents.uwo.ca.



Dr. Anthony Antoniazzi recently completed a residency in the Advanced Education in General Dentistry Program, Temple University Kornberg School of Dentistry, Philadelphia, Pennsylvania.

The authors have no declared financial interests.

References

- Montebugnoli L, Prati C. Circulatory dynamics during dental extractions in normal, cardiac and transplant patients. *J Am Dent Assoc* 2002; 133(4):468–72.
- Little JW, Rhodus NL. Dental management of the heart transplant patient. *Gen Dent* 1992; 40(2):126–31.
- Meechan JG, Parry G, Rattray DT, Thomason JM. Effects of dental local anaesthetics in cardiac transplant recipients. *Br Dent* 2002; 192(3):161–3.
- Haas DA. An update on local anesthetics in dentistry. *J Can Dent Assoc* 2002; 68(9):546–51.
- Wilson W, Taubert KA, Gewitz M, Lockhart PB, Baddour LM, Levison M, and others. Prevention of infective endocarditis: guidelines from the American Heart Association: a guideline from the American Heart Association Rheumatic Fever, Endocarditis and Kawasaki Disease Committee, Council on Cardiovascular Disease in the Young, and the Council on Clinical Cardiology, Council on Cardiovascular Surgery and Anesthesia, and the Quality of Care and Outcomes Research Interdisciplinary Working Group. *J Am Dent Assoc* 2007; 138(6):739–60.
- Little JW, Falace DA, Miller CS, Rhodus NL. Dental management of the medically compromised patient. St. Louis: Mosby Inc.; 2002. p. 271–82.
- Montebugnoli L, Servidio D, Bernardi F. The role of time in reducing gingival overgrowth in heart-transplanted patients following cyclosporine therapy. *J Clin Periodontol* 2000; 27(8):611–4.
- Khocht A, Schneider LC. Periodontal management of gingival overgrowth in the heart transplant patient: a case report. *J Periodontol* 1997; 68:1140–6.
- Ansari F, Ferring V, Schulz-Weidner N, Wetzel WE. Concomitant oral findings in children after cardiac transplant. *Pediatr Transplant* 2006; 10(2):215–9.

QUESTION 3

What is the best technique for obturating the root canal system?

Background

The steps in successful root canal treatment include access and identification of all canal orifices; instrumentation to the canal terminus; irrigation to disinfect and dissolve pulpal tissue; obturation; and, finally, placement of an orifice seal and definitive restoration to prevent microleakage and tooth fracture. Inadequate treatment at any of these steps will likely result in the persistence, occurrence or recurrence of apical periodontitis (**Fig. 1a** and **1b**).

Three of the most commonly used techniques for obturation are cold lateral condensation (CLC), warm vertical condensation (WVC) and warm carrier-based obturation (WCBO). All 3 are used to seal in (entomb) any potential irritants that could not be removed with instrumentation and irrigation; to remove space for regrowth of bacteria; and to eliminate leakage, including from the periradicular tissue into the root canal system. Although certain methods may appear conceptually better and *in vitro* leakage studies have shown differences, no single approach has shown unequivocal evidence of superior healing in outcome studies.^{1,2} Choice of an obturation method may be based on such factors as speed, simplicity, economics or practitioners' impressions from experience and individual and serial case reports.

Management of the Issue

CLC is the obturation technique most commonly taught in dental school, as it is safe, cost

effective and user friendly. It involves fitting a standard size master cone corresponding to the master apical file size. It requires a continuously flared canal with an apical stop or tapering control zone. For optimal deformation of material, the spreader must be prefitted so that it extends deeply into the empty canal without binding. Nickel titanium hand spreaders may penetrate more deeply, generate less internal stress and distribute forces more evenly than others.³ Accessory cones must be sequentially added to eliminate voids and minimize sealer thickness. The major limitation of CLC is the inability to move the obturation material or sealer into irregularities of the main canal or branches.

WVC has been described as obturating in 3-D, indicating an intention to fill all ramifications of the pulp space including accessory canals. It is the experience of most endodontists that the ability to fill canal irregularities and branches has been best demonstrated with this technique. For WVC to be effective, the canal must be properly cleaned and shaped to provide the hydraulics necessary to force the softened material and sealer into these irregularities, while providing the resistance needed to prevent overfilling. This is accomplished by preparation that continually tapers to an apical control zone with the canal patent to the terminus. For obturation, a medium or fine-medium cone is cut to fit snugly in the apical control zone. Fit must be precise to prevent migration of the cone with apical pressure, and the canal must have been shaped

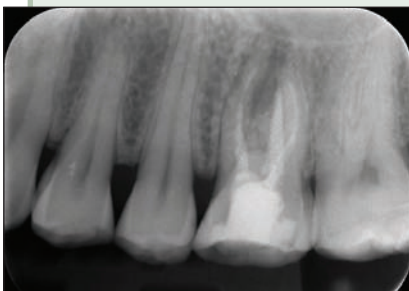


Figure 1a: Poor fill is an indication of insufficient cleaning and disinfection.

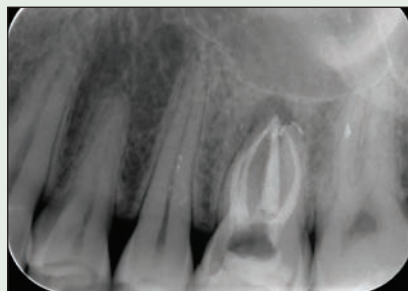

Figure 1b: Retreatment involved finding a fourth canal and cleaning and disinfecting to the canal terminus to set up the conditions for healing.

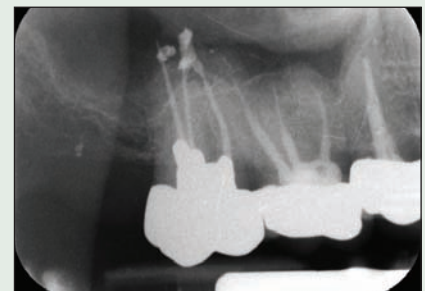


Figure 2: This tooth remained symptomatic following treatment. Poor apical control and the use of excess sealer with carrier-based obturators resulted in extrusion of excess material beyond the apex.



Figure 3: (a) Two small-diameter, carrier-based obturators were used in an attempt to seal this large canal. Insufficient fill resulted. (b) Retreatment involved removal of the carriers. (c) The canal was then cleaned, disinfected and obturated with mineral trioxide aggregate in the apical half followed by application of a core material to seal.

sufficiently to allow the heat source to penetrate (ideally, 5 mm from cone length).⁴ The cone is compacted and excess material removed, leaving an apical plug. Backfilling with obturation material against this plug completes the procedure.

WCBO attempts to provide the advantages of a warm technique in a simplified, fast, controlled manner. Following instrumentation and disinfection, a verifier file is used to check length; the carrier, surrounded with warm gutta-percha, is then placed to this length. This technique has been embraced by many general dentists because it is fast, and apical control is achieved by pushing the carrier to length. Radiographically, the fill will appear dense due to the radiopacity of the carrier, and additional anatomy may be captured.

Disadvantages include the inability to obtain a film verifying cone fit, stripping of the gutta-percha away from the carrier and possible expression of material beyond the apex (Fig. 2).⁵ In cases of persistent or recurrent disease, the plastic carrier can sometimes be difficult and frustrating to remove, particularly when instrumentation was insufficient (Figs. 3a–3c). For these reasons WCBO has not been widely embraced by endodontists.

Sealer is always necessary to fill the space between the obturation material and canal wall irregularities, fins and branches. It should cover the entire wall and be of minimal thickness. Sealer is also required to fill the spaces between the master and accessory cones in lateral condensation. When WVC is used, the cone can be liberally coated with sealer because excess can flow out coronally during cone placement. Downpack hydraulics then

express the sealer into canal irregularities and ensure minimal film thickness. With a carrier-based technique, it is extremely important to use a very light coating of sealer on the walls, as placement of the warmed carrier will have a piston effect, with potential expression of excess sealer into the periradicular tissues.³

Conclusion

Shortfalls in obturation are most often a result of inadequate canal preparation. Indeed, contemporary research points to cleaning and disinfection of the root canal as the single most important step in preventing and treating endodontic disease.⁶ From a clinical standpoint, each practitioner should employ an obturation technique that provides consistent, predictable results that meet a high standard. When the practitioner is in doubt as to whether a high standard can be achieved, he or she should seek help from an endodontist who is trained, equipped and experienced in treating these cases. ♦

THE AUTHOR



Dr. Mike Rampado maintains an endodontic specialty practice in Kelowna, British Columbia. Email: drrampado@shaw.ca.

References

1. Wu MK, Wesseling PR. Endodontic leakage studies reconsidered. Part I. Methodology, application and relevance. *Int Endod J* 1993; 26(1):37–43.
2. Kirkevang LL, Horsted-Bindslev P. Technical aspects of treatment in relation to treatment outcome. *Endod Topics* 2002; 2:89–102.
3. Whitworth J. Methods of filling root canals: principles and practices. *Endod Topics* 2005; 12:2–24.
4. Wu MK, van der Sluis LW, Wesseling PR. A preliminary study of the percentage of gutta-percha-filled area in the apical canal filled with vertically compacted warm gutta-percha. *Int Endod J* 2002; 35(6):527–35.
5. Clinton K, Van Himel T. Comparison of a warm gutta-percha obturation technique and lateral condensation. *J Endod* 2001; 27(11):692–95.
6. Haapasalo M, Endal U, Zandi H, Coil JM. Eradication of endodontic infection by instrumentation and irrigation solutions. *Endod Topics* 2005; 10:77–102.

QUESTION 4

How should I treat a young patient in the primary or early mixed dentition stage who presents with unilateral posterior crossbite and mandibular shift?

Background

Posterior crossbite of the primary or mixed dentition can be caused by a skeletal or a dental discrepancy. Skeletal crossbite is due to deficiency of the transverse maxillary arch, a wider-than-normal mandibular arch or both. Dental crossbite can occur when the arches are of adequate width but the maxillary teeth are tipped lingually and/or the mandibular teeth are tipped buccally. The incidence of posterior crossbite in the primary, mixed and permanent dentitions ranges between 7% and 23%.¹

A crossbite affecting only one tooth is often dental in nature and can occur as a result of crowding. For example, early loss of a maxillary primary second molar may cause lingual displacement of the second premolar.² Dental crossbite in the primary dentition is uncommon, because crowding is rare. A crossbite affecting one tooth can also occur when a retained primary tooth disrupts the eruption path of its permanent successor.

A posterior crossbite may be unilateral or bilateral. True unilateral crossbite results from intra-arch or skeletal asymmetry, which may have a pathologic cause, such as unilateral cleft lip and palate or unilateral condylar hyperplasia. Bilateral crossbite may have the same underlying causes as unilateral crossbite, but there is more maxillary constriction distributed throughout the arch and no forced shift of the mandible. Although most crossbites of the primary or early mixed dentition are unilateral in appearance as a result of a mandibular shift to one side on closure, they are actually bilateral crossbites.

Diagnosis

Frontal examination may demonstrate lateral deviation of the chin toward the side of the functional shift. Mandibular asymmetry may occur as a result of asymmetric growth due to the functional shift. If such asymmetry is present, posteroanterior or submental radiography may help to assess its presence and extent. Lateral cephalometric radiography (at maximum intercuspation and at the point of initial contact, before the functional shift occurs) may be helpful but can be technically challenging if the patient is very young.

Evaluating the axial inclination of the posterior teeth in study models can be used to determine whether the crossbite is dental or skeletal. If this evaluation shows that the crossbite could be corrected by removing the transverse dental compensation, the discrepancy is probably dental in nature. If the crossbite appears worse after the compensations are removed, it is probably skeletal in origin.

Intraoral examination may reveal a functional shift of the mandible into maximum intercuspation. This may be due to dental interferences (usually of the primary canines) but is often a result of bilateral maxillary constriction. However, severe constriction may result in bilateral crossbite without a functional shift. To diagnose a functional mandibular shift, the patient can be asked to roll the tongue to the posterior palate, which helps to bring the mandible into a retrusive position. With gentle guidance the clinician can move the mandible into retrusion and will see the first point of contact and then the slide.

Timing of Treatment

Crossbite with functional shift is one of the few conditions requiring treatment in the primary dentition.³ If the permanent first molars are expected to erupt in less than 6 months, treatment can be delayed so that these teeth can be included in the correction. The proportion of posterior crossbites that persist into the permanent dentition is significant but variable (8% to 45%).^{4,5} If not corrected, a functional shift may lead to undesirable adaptation of the temporomandibular joint, asymmetric mandibular growth, dental compensations and dental abrasion. Treatment in the early mixed dentition stage also leads to improvement in mandibular asymmetry.⁶

Delaying treatment until the late mixed or permanent dentition stage has been advocated,^{3,4} to allow possible spontaneous correction, to avoid multiple phases of treatment and to allow the patient to reach a developmental stage with better cooperation and self-motivation. However, such a delay risks development or worsening of mandibular asymmetric growth.

Crossbite should not be corrected in the presence of a sucking habit, as the crossbite will

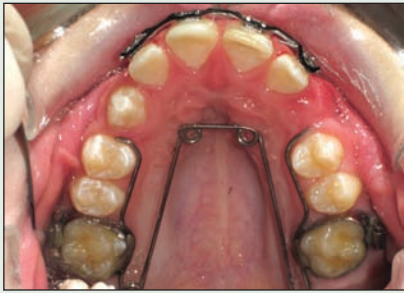

Figure 1: Fixed quad helix in a patient with maxillary deficiency. Compliance is not an issue with this appliance, which can be activated intraorally if further expansion is required. The arms can be removed and the appliance can act as a cost-effective fixed retainer.

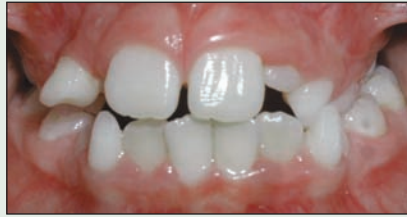

Figure 2: A 7-year-old girl presented with unilateral posterior crossbite on the left side, along with a 3-mm functional shift to the left and a midline discrepancy.

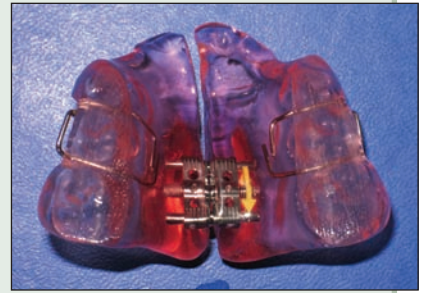


Figure 3: A removable maxillary expansion appliance was delivered, with instructions for full-time wear and turning 2 times per week.

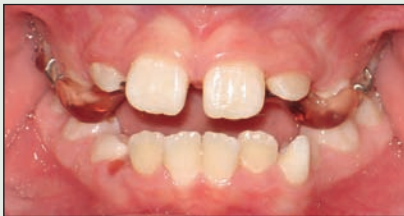

Figure 4: At 12 weeks, 6 mm of expansion had been achieved, and the unilateral posterior crossbite and functional shift had been corrected.

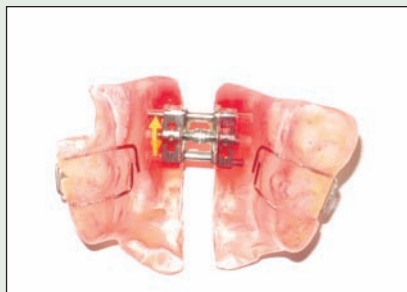


Figure 5: The appliance was worn as a retainer.

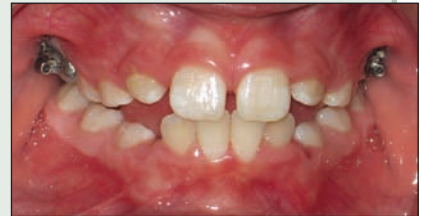

Figure 6: Six months after initial presentation, the functional shift and crossbite remained absent and the midlines were coincident. The patient was compliant with use of the removable appliance.

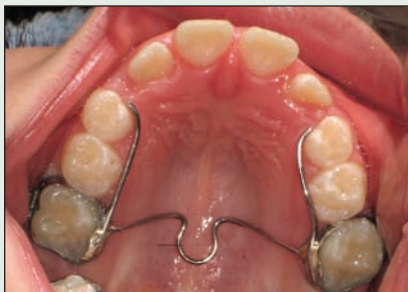

Figure 7: A fixed transpalatal arch was then cemented with bands on the first permanent molars, with arms extending to the lingual surface of the primary first and second molars for retention.

a minor functional shift (less than 1 mm); expansion of the maxillary arch; or repositioning of individual teeth, combined with use of crossbite elastics, to deal with intra-arch asymmetries, in cases of localized dental crossbite.

Application of light transverse expansive forces at the midpalatal suture can result in skeletal and dental changes to correct the crossbite or transverse deficiency. Heavy forces from a rapid palatal expander in the primary or early mixed dentition may cause distortion of the nose and should therefore be delayed until the patient is in the middle to late mixed dentition stage.

In a patient with unilateral crossbite as a result of a functional mandibular shift, bilateral transverse expansion is generally necessary. Removable maxillary expanders are advantageous, as they require little chair time and can include a bite plate to assist in the disarticulation of the posterior teeth. Fixed appliances such as the quad helix (Fig. 1)

probably return after treatment unless the habit is eliminated. However, appliance therapy may simultaneously discourage the sucking habit and correct the crossbite.

There are 3 approaches to treating moderate posterior crossbite in children³: occlusal equilibration to eliminate interferences, in cases with

or W-arch are also useful and do not depend on patient compliance. They act quickly, have minimal effects on speech and generally deliver a continuous light force. After the expansion has been achieved, the active component of the quad helix can be removed and the buccal arms left in place to provide a cost-effective means of retention.

For true unilateral crossbite, a removable appliance is preferred, with an asymmetrically placed expansion screw toward the side of the crossbite and more acrylic palatal coverage toward the normal side. This permits more basal bone anchorage on the normal side and more expansion on the side with the crossbite. The case presented here illustrates the successful treatment of a unilateral crossbite with a removable maxillary expansion appliance. Once successful expansion was achieved (Figs. 2–4), the patient continued to wear the appliance as a retainer (Figs. 5 and 6). Six months after initial presentation (3 months after completed expansion), a fixed transpalatal arch was cemented in place (Fig. 7). The patient's facial musculature was balanced, and the buccal segments had effective interdigitation, which should assist in establishing long-term retention. She will be monitored every 3 to 6 months.

Conclusion

Treatment of posterior crossbite in the primary or early mixed dentition is indicated when a functional mandibular shift is present. Otherwise, there is a risk of long-term asymmetric mandibular growth. Treatment usually takes the form of an expansion appliance in the maxilla; retention protocols should be considered once successful expansion has been achieved and the crossbite has been eliminated. ➤

THE AUTHORS



Dr. James Noble is a senior orthodontic resident in the faculty of dentistry, University of Manitoba, Winnipeg, Manitoba. Email: umnoble@cc.umanitoba.ca.



Dr. Robert C. Baker is senior scholar, department of orthodontics, University of Manitoba, Winnipeg, Manitoba.



Dr. Nicholas Karaiskos is a senior orthodontic resident in the faculty of dentistry, University of Manitoba, Winnipeg, Manitoba.



Dr. William A. Wiltshire is professor and head of the department of orthodontics, division of preventive dental science, University of Manitoba, Winnipeg, Manitoba.

References

- Kennedy DB, Osepchook M. Unilateral posterior crossbite with mandibular shift: a review. *J Can Dent Assoc* 2005; 71(8):569–73.
- Ninou S, Stephens C. The early treatment of posterior crossbites: a review of continuing controversies. *Dent Update* 1994; 21(10):420–6.
- Proffit WR. Contemporary orthodontics. 3rd ed. St. Louis (MO): Mosby Co., 2000. p. 187–8, 435–9.
- Malandris M, Mahoney EK. Aetiology, diagnosis and treatment of posterior cross-bites in the primary dentition. *Int J Paediatr Dent* 2004; 14(3):155–66.
- Marshall SD, Southard KA, Southard TE. Early transverse treatment. *Semin Orthod* 2005; 11(3):130.
- Hesse KL, Artun J, Joondeph DR, Kennedy DB. Changes in condylar position and occlusion associated with maxillary expansion for correction of functional unilateral posterior crossbite. *Am J Orthod Dentofacial Orthop* 1997; 111(4):410–8.

Further Reading

- Bartzela T, Jonas I. Long-term stability of unilateral posterior crossbite correction. *Angle Orthod* 2007; 77(2):237–43.
- Harrison JE, Ashby D. Orthodontic treatment for posterior crossbites. *Cochrane Database Syst Rev* 2006; 2:CD 000879.
- Petren S, Bondemark L, Soderfeldt B. A systematic review concerning early orthodontic treatment of unilateral posterior crossbite. *Angle Orthod* 2003; 73(5):588–96.
- Pinto AS, Buschang PH, Throckmorton G, Chen P. Morphological and positional asymmetries in young children with functional unilateral posterior crossbite. *Am J Orthod Dentofacial Orthop* 2001; 120(5):513–20.
- Schiffman PH, Tuncay OC. Maxillary expansion: a meta analysis. *Clin Orthod Res* 2001; 4(2):86–96.
- Turpin DL. Dealing with posterior crossbite in young patients. *Am J Orthod Dentofacial Orthop* 2004;126(5):531–2.