

Epidermoid Cyst of the Floor of the Mouth: A Case Report

*Bruno C. Jham, DDS, MS; Gabriela V. Duraes, DDS; Andre C. Jham, DDS;
Cassio R. Santos, DDS, PhD*

Contact Author

Dr. B.C. Jham
Email: [brunocjham@
yahoo.com.br](mailto:brunocjham@yahoo.com.br)



ABSTRACT

Dermoid cysts are malformations that are rarely observed in the oral cavity. Histologically, they can be further classified as epidermoid, dermoid or teratoid. We report a case in which a 25-year-old man developed an epidermoid cyst presenting as a large sublingual swelling causing speech and swallowing difficulties. The differential diagnosis for dermoid cysts includes infections, tumours, mucous extravasation phenomena and abnormalities arising during embryonic development. In this case, aspiration of the cyst produced a keratin-containing liquid, which proved to be useful in preoperative diagnosis. The lesion was surgically excised using an intraoral approach. Microscopic examination revealed a dermoid cyst of the epidermoid type. After 12 months of follow up, the cyst had not recurred. This case shows that dermoid cysts may be successfully diagnosed and managed using a series of simple yet effective clinical manoeuvres.

For citation purposes, the electronic version is the definitive version of this article: www.cda-adc.ca/jcda/vol-73/issue-6/525.html

Dermoid cysts are cystic malformations lined with squamous epithelium; they constitute 1.6% to 6.9% of all cysts in the head and neck area. Histologically, they can be further classified as epidermoid (lined with simple squamous epithelium), dermoid (when skin adnexa are found in the cyst wall) or teratoid (when other tissues, such as muscle, cartilage and bone are present).¹

These cysts occur most often in patients in their second or third decade of life. Clinically, the lesion presents as a slow-growing asymptomatic mass, usually located in the midline, above or below the mylohyoid muscle. When located above the muscle, the cyst manifests itself as a sublingual swelling; when below the muscle, the clinical aspect will be a submental

swelling.² Consequently, tongue elevation, speech alteration or double-chin development are frequent complaints.³ Because they are almost always asymptomatic, dermoid cysts are usually diagnosed only after they have reached a considerable size. Recommended treatment is surgical excision via intraoral or extraoral access, depending on the lesion's size and location.^{4,5}

In this report, we describe a man who presented with a cystic sublingual lesion occupying the entire floor of the mouth. We discuss the clinical steps required to achieve an accurate diagnosis, the differential diagnosis, useful imaging techniques and treatment of dermoid cysts.

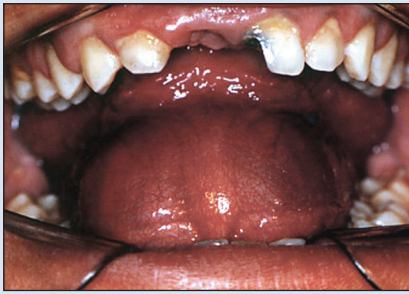

Figure 1a: Intraoral mass in the floor of the mouth.

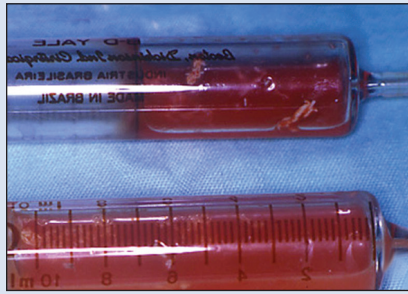


Figure 1b: Liquid obtained through aspirative puncture; note keratin-like substance.

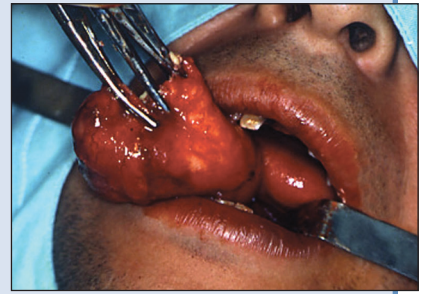


Figure 1c: Surgical excision of the lesion.

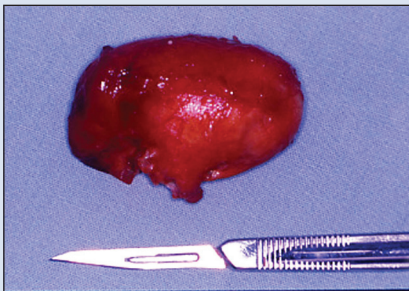


Figure 1d: Macroscopic aspect of the removed lesion.

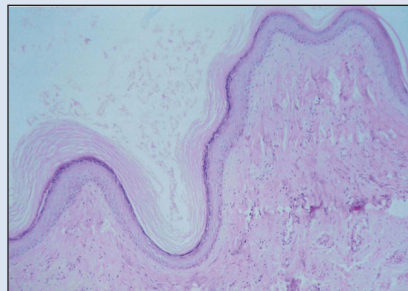


Figure 2a: Fibrous connective tissue, epithelial lining and keratin-filled cystic cavity (low magnification; hematoxylin-eosin stain).

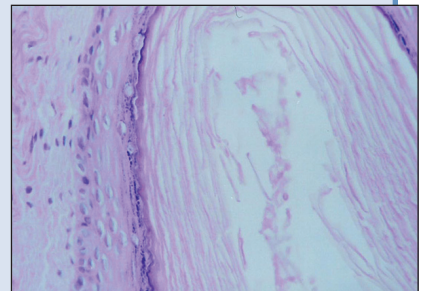


Figure 2b: Stratified squamous epithelium lining and keratin within the cyst lumen (high magnification; hematoxylin-eosin stain).

Case Report

A 25-year-old man presented with a swelling below his tongue. Medical history was noncontributory. The patient could not say precisely when the lesion initially developed, but reported speech and swallowing difficulties for the past 2 months. Extraoral examination was unremarkable, and palpable lymph nodes could not be identified. Intraoral examination revealed a 5 cm × 5 cm, sessile, nonulcerated, smooth-surfaced, normal-coloured, well-defined sublingual swelling occupying the entire floor of the mouth (**Fig. 1a**). The lesion was slightly movable, rubbery and painless on palpation. No additional mucosal lesions were present. With the tentative diagnosis of ranula, aspiratory puncture was carried out. This revealed a keratin-containing liquid (**Fig. 1b**), which pointed to a new diagnostic hypothesis of dermoid cyst.

Surgical excision of the lesion was performed through an intraoral midline incision under local anesthesia (**Fig. 1c**). Macroscopically, the lesion appeared encapsulated and contained a keratin-like yellow material (**Fig. 1d**). Microscopic examination revealed a cystic cavity lined with orthokeratinized squamous epithelium, with keratin in the lumen. The cyst wall was composed of fibrous connective tissue. Skin appendages, such as sebaceous glands, hair follicles and sweat glands, were absent

(**Figs. 2a** and **2b**). Final histologic diagnosis was dermoid cyst of the epidermoid type. The patient was followed for 12 months with no signs of recurrence.

Discussion

Several theories have been proposed to explain the development of dermoid cysts.¹ They may result from entrapment of ectodermal tissue of the first and second branchial arches during fetal development. They could represent a variant form of the thyroglossal duct cyst. Finally, previous surgical or accidental events could lead to traumatic implantation of epithelial cells into deeper tissues.

Longo and others⁶ found that men are affected more often than women in the ratio 3:1, with mean age 28 years. Other authors claim that no gender predilection exists. In our case, the sublingual swelling suggests that the lesion was above the mylohyoid muscle, which is the most common location.² Our patient reported speech and swallowing difficulties, which are fairly common symptoms.³ However, the patient could not determine precisely when the swelling had initially developed. We believe it is unlikely that the lesion achieved the size on presentation in only 2 months; most likely, the cyst had

Table 1 Differential diagnosis of swellings of the floor of the mouth or neck

Category	Lesion	Signs and symptoms
Tumours	Benign (mesenchymal, salivary gland) tumours	Displacement of adjacent structures, slow-growing, smooth surface
	Malignant tumours	Ulcerated surface, invasion of adjacent structures, metastatic lymph nodes
Mucous extravasation phenomena	Ranula	Bluish-translucent coloration, soft, fluctuant
Embryonic abnormalities	Dermoid cyst	Swelling in midline floor of the mouth or neck; slow-growing, painless
	Cervical lymphoepithelial cyst	Upper lateral neck swelling without an intraoral component
	Thyroglossal duct cyst	Classically in the midline of the neck; first 2 decades of life
Infections	Intraoral source of infection (periapical abscess, pericoronitis, sialadenitis)	Rapid progression, pain, fever; warm overlying skin; obvious intraoral source

gone unnoticed until it grew large enough to cause the reported symptoms.

When dealing with swellings in the sublingual region, 4 main groups of lesions should be considered: infections, tumours, mucous extravasation phenomena and anatomic abnormalities arising during embryonic development.² **Table 1** summarizes the clinical features important in the differential diagnosis of sublingual or cervical swellings. In our case, the hypothesis of an infection was discarded due to the period of evolution and the absence of pain and of intraoral infectious foci. Malignant tumour was ruled out in view of the lesion's clinical aspect and the absence of lymphadenopathy, although the latter is admittedly an imprecise indicator of malignancy. We were then left with 2 main diagnostic possibilities: a mucous extravasation phenomenon and an anatomic abnormality. Because the clinical aspect was compatible with ranula and because ranulas are far more common than dermoid cysts, this was our first hypothesis. Later, on collection of keratin-containing fluid through aspiratory puncture, a dermoid cyst became the more plausible choice.

In some instances, where the differential diagnosis of sublingual swellings is more challenging, imaging techniques may be used for preoperative diagnosis and surgical planning. Fine-needle aspiration is a safe, cost-effective and reliable tool for preoperative diagnosis of dermoid cysts. Magnetic resonance imaging (MRI) and computed tomography (CT) allow more precise localization of the lesion, and also enable the surgeon to choose the most appropriate approach.⁶ Some authors prefer MRI over CT as a diagnostic tool for dermoid cysts,⁷⁻⁹ as it is superior in terms of soft-tissue resolution and, thus, better able to depict the internal structure of a mass lesion. In our case, the patient could not bear the

cost of such techniques. It should be emphasized that it is not possible to determine the specific histologic subtype through fine-needle aspiration, MRI or CT scans. Thus, microscopic examination will always be required following excision of the lesion.⁷⁻⁹

Dermoid cysts are histologically differentiated as epidermoid, dermoid or teratoid. There are no data on the incidence of the various forms; however, epidermoid cysts are said to be most common and teratoid cysts least common.⁷ In our case, the cyst showed simple squamous epithelium without skin appendages, characterizing it as an epidermoid cyst. Dermoid cysts contain skin appendages, and teratoid cysts contain endodermic and mesodermic elements in the cyst wall.¹

In most cases, dermoid cysts are treated by enucleation.⁷ Surgical access depends on the location and size of the lesion. Surgical approaches, such as transcuteaneous, extended median glossotomy, median glossotomy and midline incision, may be performed.⁶ In our case, excision was achieved without major complications by employing intraoral access under local anesthesia. This approach is supported by Akao and colleagues³ who state that intraoral access must be attempted first, even if dealing with a large cyst. The intraoral approach leads to good cosmetic and functional results.^{3,6} Marsupialization has also been proposed as a treatment alternative in cases of giant cysts.⁷

When intraoral access is complicated, a combined intraoral and extraoral approach should be used.³ Extraoral incision is mandatory only when the cyst lies under the geniohyoid muscle. Surgical excision is normally achieved without major complications and prognosis is very good.^{3,6} However, it should be kept in mind that surgery on the floor of the mouth may damage

structures in the sublingual space, leading to potentially life-threatening complications. Hemorrhage and hematoma formation may ensue and could lead to significant swelling and edema of the floor of mouth and tongue, resulting in respiratory distress and airway obstruction from elevation of the tongue against the palatal vault.¹⁰ Recurrence of dermoid cysts is not expected, and malignant transformation is rare.⁷

In conclusion, we describe a case of dermoid cyst successfully diagnosed and managed by following simple yet effective steps. To obtain the correct diagnosis of cystic sublingual swellings, aspiratory puncture should always be performed. Differential diagnosis includes infections, tumours, mucous extravasation phenomena and embryonic abnormalities. Surgical excision is the treatment of choice and may be performed under local anesthesia through intraoral access, with no recurrence expected. ✦

- mouth. A case report.] *An Otorrinolaringol Ibero Am* 2002; 29(2):181–6. [Article in Spanish]
6. Longo F, Maremonti P, Mangone GM, De Maria G, Califano L. Midline (dermoid) cysts of the floor of the mouth: report of 16 cases and review of surgical techniques. *Plast Reconstr Surg* 2003; 112(6):1560–5.
7. Yilmaz I, Yilmazer C, Yavuz H, Bal N, Ozluoglu LN. Giant sublingual epidermoid cyst: a report of two cases *J Laryngol Otol* 2006; 120(3):E19.
8. Burger MF, Holland P, Napier B. Submental midline dermoid cyst in a 25-year-old man. *Ear Nose Throat J* 2006; 85(11):752–3.
9. Babucco O, Isiksacan Ozen O, Hosnuter M, Kargi E, Babucco B. The place of fine-needle aspiration in the preoperative diagnosis of the congenital sublingual teratoid cyst. *Diagn Cytopathol* 2003; 29(1):33–7.
10. Woo BM, Al-Bustani S, Ueek BA. Floor of mouth haemorrhage and life-threatening airway obstruction during immediate implant placement in the anterior mandible. *Int J Oral Maxillofac Surg* 2006; 35(10):961–4. Epub 2006 Jul 7.

THE AUTHORS

Acknowledgement: Dr. B.C. Jham is supported by a doctoral scholarship from CNPq-Brazil (201590/2006-9).



Dr. B.C. Jham is a resident and PhD student in the department of diagnostic sciences and pathology, University of Maryland Dental School, Baltimore, Maryland.



Dr. Duraes is a resident in the department of oral surgery and pathology, School of Dentistry, Universidade Federal dos Vales do Jequitinhonha e Mucuri, Diamantina, Minas Gerais, Brazil.



Dr. A.C. Jham is a resident in the International Student Program, University of Colorado School of Dentistry, Aurora, Colorado.



Dr. Santos is a full professor in the department of oral surgery and pathology, School of Dentistry, Universidade Federal dos Vales do Jequitinhonha e Mucuri, Diamantina, Minas Gerais, Brazil.

Correspondence to: Dr. Bruno Correia Jham, 655 W Baltimore St, 7th Floor North Lab, Baltimore MD 21201

The authors have no declared financial interests.

This article has been peer reviewed.

References

1. De Ponte FS, Brunelli A, Marchetti E, Bottini DJ. Sublingual epidermoid cyst. *J Craniofac Surg* 2002; 13(2):308–10.
2. Louis PJ, Hudson C, Reddi S. Lesion of floor of the mouth. *J Oral Maxillofac Surg* 2002; 60(7):804–7.
3. Akao I, Nobukiyo S, Kobayashi T, Kikuchi H, Koizuka I. A case of large dermoid cyst in the floor of the mouth. *Auris Nasus Larynx* 2003; 30(suppl): S137–9.
4. Lima SM Jr, Chrcanovic BR, de Paula AM, Freire-Maia B, de Souza LN. Dermoid cyst of the floor of the mouth. *ScientificWorldJournal* 2003; 3:156–62.
5. Santiago Juan C, Pellicer Soria M, Ramos Asensio R, Iriarte Ortabe JI, Caubet Biayna J, Hamdan H, and others. [Dermoid cyst of the floor of the