


# Autotransplantation of a Supplemental Premolar: A Case Report

*Shiu-yin Cho, BDS, MDS, FRACDS; Chun-kei Lee, BDS, MDS, FRACDS*

## Contact Author

*Dr. Cho*  
*Email: rony\_cho@dh.gov.hk*



## ABSTRACT

In this article, we describe the autotransplantation of a supplemental premolar to replace an extracted first permanent molar in a 12-year-old boy. Although the end results are not ideal due to the small size of the donor tooth, the esthetics and function of the dental arch are partly restored using a natural tooth rather than a prosthesis. This case report illustrates the usefulness of autotransplantation as a viable treatment option in children with missing permanent teeth.

For citation purposes, the electronic version is the definitive version of this article: [www.cda-adc.ca/jcda/vol-73/issue-5/425.html](http://www.cda-adc.ca/jcda/vol-73/issue-5/425.html)

The replacement of missing permanent teeth in children can be challenging, as the growth and development of the oral structures need to be taken into account. In addition, the substitute should have the potential for long-term survival. Of the various replacement means, autotransplantation is a viable option.<sup>1-4</sup>

Autotransplantation involves the transfer of a tooth from its alveolus to another site in the same person.<sup>5</sup> The recipient site may be either an extraction site or a surgically prepared alveolus. Autotransplantation has been used in repositioning impacted teeth, in replacement of congenitally missing teeth or teeth lost due to trauma or dental disease and in replacement of teeth with poor prognosis.<sup>5-8</sup> Among these situations, replacement of first permanent molars that have been lost due to caries is common.<sup>5,8-11</sup>

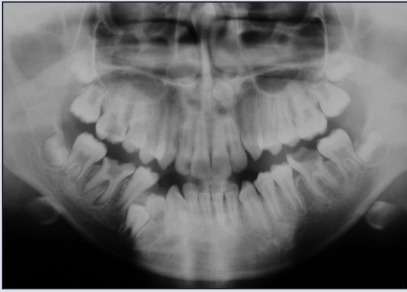First permanent molars are said to be the most caries-prone teeth in the permanent dentition.<sup>12</sup> Their early exposure to the oral environment and the presence of pits and fissures, which are less protected from fluoride

than smooth surfaces, are contributory factors.<sup>12,13</sup> Late extraction of a first permanent molar will bring about marked mesial tipping and some lingual rotation of the second molar if the space is not restored.<sup>13</sup> Treatment options for the extraction space in a growing child may include replacement with a removable prosthesis, orthodontic space closure, use of the extraction space orthodontically to relieve crowding, or tooth replacement by autotransplantation.

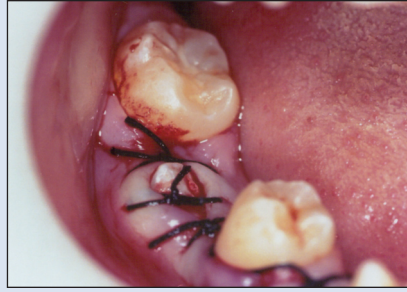
A donor tooth chosen for autotransplantation should be of limited value in the dentition, e.g., a third molar,<sup>5</sup> a premolar in a crowded arch<sup>1</sup> or a supplemental tooth.<sup>14</sup> Supplemental premolars are relatively uncommon; their prevalence has been estimated to be less than 0.7%.<sup>15</sup> In this article, we report the autotransplantation of a supplemental premolar to replace an extracted first permanent molar.

## Case Report

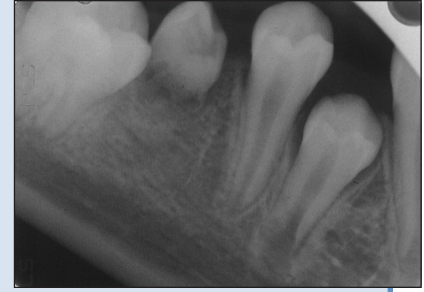The patient was a 12-year-old boy with an unremarkable medical history. He was referred to the authors for management of an



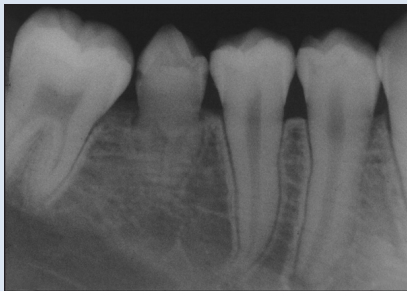**Figure 1:** Orthopantomogram, taken when the patient was 11 years, 11 months of age, shows the presence of a premaxillary mesiodens and a mandibular right supplemental premolar.



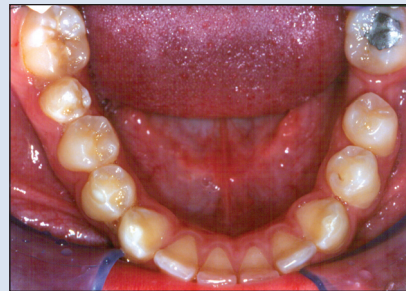
**Figure 2:** Immediate postoperative view of the autotransplant stabilized with sutures.



**Figure 3:** Periapical radiograph of the supplemental premolar taken 6 months after autotransplantation shows alveolar healing.



**Figure 4:** Periapical radiograph of the supplemental premolar taken 40 months after autotransplantation shows completed root growth with partial pulp obliteration.



**Figure 5:** Clinical view of the mandibular arch shows the autotransplant at the right side with acceptable alignment. Resorption of the alveolar bone is seen in the left extraction site.

impacted mandibular right first premolar. On examination, the boy was found to be in permanent dentition with the mandibular right first premolar and all third molars unerupted. Both his mandibular first permanent molars had been extracted by his referring dental therapist when the boy was 11 years, 11 months of age. The orthopantomogram taken at the time of extraction revealed an unerupted premaxillary mesiodens and a supplemental premolar impacted with the mandibular right first premolar (**Fig. 1**). Crown formation on the supplemental premolar was complete. The parents agreed that early removal of the supplemental premolar would be needed to facilitate eruption of the impacted first premolar. However, they preferred not to extract the mesiodens as it was deeply seated and not associated with pathosis.

Treatment options for spaces created by extraction of the first molars were explained. However, the parents and patient declined orthodontic space closure or removable prostheses as the cost of these treatments was not covered by the public dental service in which the patient was enrolled. Autotransplantation of the supplemental premolar

to the mandibular right molar region was then proposed as a possible, although less desirable, option. The parents accepted this option and understood that some tilting of the second molar would still occur due to the size discrepancy between a permanent molar and the premolar. Undesirable tilting of the mandibular left permanent second molar could also be expected as the first molar space would be left untreated.

The autotransplantation was performed by the first author. Under local anesthesia, mucoperiosteal flaps were raised in the mandibular right first premolar and first molar areas. As partial healing of the first molar socket had occurred, the recipient site was prepared with a surgical round bur cooled with sterile saline. The supplemental premolar was carefully extracted, keeping the radicular part intact and untouched, and was transplanted to the first molar area without extraoral storage. The transplant was stabilized by black silk sutures, which were also used for wound closure (**Fig. 2**). The patient was prescribed chlorhexidine rinse and amoxicillin for 1 week. He was reviewed at 1 week, 1 month, 3 months

and then every 6 months (Fig. 3). Continued root growth was observed during this period, and there was no clinical or radiographic sign of root resorption.

The patient was last seen when he was 15 years, 4 months old. Radiographic examination revealed completed root growth, with intact lamina dura and partial pulp obliteration in the transplanted tooth (Fig. 4). The final crown-to-root ratio was close to 1, but the root structure appeared less radiopaque than in the adjacent premolars. The tooth responded positively to the ethyl chloride test and no periodontal lesion was seen. Initial caries lesions were seen on the proximal surfaces of the transplant and were treated by topical fluoride. The mandibular right first premolar had also fully erupted, but the second molar had tilted slightly mesially (Fig. 5). In contrast, a large gap was seen in the mandibular left first molar area with resorption of the alveolar ridge.

## Discussion

High autotransplantation success rates have been reported in the literature. Andreasen and others,<sup>2</sup> who investigated the long-term prognosis of autotransplanted premolars for up to 13 years, reported 95% and 98% survival rates for teeth with incomplete and complete root formation, respectively. Autotransplantation is considered successful if there is no progressive root resorption, hard and soft periodontal tissues adjacent to the transplanted tooth are normal and the crown-to-root ratio is less than 1.<sup>16,17</sup> Using these criteria, Kristerson and Lagerstrom<sup>16</sup> evaluated 50 teeth autotransplanted to the maxillary incisor region after a mean period of 7.5 years and found an 82% success rate. Likewise, Tsukiboshi<sup>7</sup> reported an 82% success rate among 220 cases of autotransplantation after a mean of 6 years. Jonsson and Sigurdsson<sup>18</sup> followed 40 transplanted premolars for a mean period of 10 years, 4 months and showed a 93% success rate. In their long-term study of 33 autotransplanted teeth, Czochrowska and others<sup>17</sup> reported a 79% success rate after 17–41 years.

The factors that lead to successful autotransplantation have been extensively investigated. Although variations in the surgical protocol have been reported, the consistent message is the necessity for an atraumatic technique to preserve an intact periodontal ligament and Hertwig's root sheath in the donor tooth.<sup>6</sup> Pulp survival is also an important factor in root growth in immature teeth. An apical foramen diameter greater than 1 mm decreases the risk of pulpal necrosis after transplantation, and root resorption is more frequent in transplanted teeth with mature root development than in teeth with immature roots.<sup>3</sup> Although these findings indicate that greater success rates are achieved using teeth with immature roots for autotransplantation, teeth in the early stages of root development show less post-transplant root growth than those with more mature roots but incompletely formed

apices.<sup>4</sup> As there is a possibility of no additional root growth after transplantation, it has been suggested that the donor tooth should preferably have at least three-quarter of the root formed and an apical opening more than 1 mm at the time of autotransplantation.<sup>7</sup> This is regarded as the best compromise to achieve a successful outcome in terms of root growth and healing of the periodontal ligament and pulp.<sup>19</sup> Transplantation of a fully formed root negates the potential for pulp regeneration, but adequate endodontic therapy will still ensure high survival rates.<sup>2,7</sup>

In the present case, the premolar was transplanted at a less than ideal stage of root development. However, the timing of the autotransplantation was governed by the urgent need to remove the supernumerary premolar and delayed removal might have compromised the eruption of the impacted first premolar. Autotransplantation using the third molars was not feasible at the time due to their early stage of development. As the first permanent molars had already been extracted when the authors first saw this patient, progressive resorption of the alveolar ridge was expected if treatment was delayed.<sup>7,19</sup> Partial pulp obliteration was observed in the transplanted tooth in this case, which is common in transplanted teeth showing pulpal healing.<sup>3,18,20</sup> The transplanted tooth was stabilized using sutures for 1 week postoperatively, as rigid long-term fixation of transplanted teeth may have adverse effects on periodontal and pulpal healing.<sup>2,6,9</sup> Although the use of antibiotics before and after surgery has been suggested by many authors,<sup>1,6–10</sup> antibiotics have not been shown to improve pulpal or periodontal healing.<sup>2,3</sup> In this case, the supplemental premolar was transplanted to a surgically prepared socket as partial healing had occurred after extraction. Although the success of autotransplantation depends mainly on the presence of vital periodontal ligament on the donor root surface,<sup>6</sup> a higher success rate has been found when a donor tooth is transplanted to an extraction socket immediately after extraction than when it is placed in an artificially prepared site.<sup>7,19</sup> In the latter case, healed periodontal ligament is less functionally aligned.<sup>19</sup> The periodontal ligament in the alveolar socket may also play a role in periodontal healing after transplantation.

The choice of treatment in this case was limited by financial constraints. Otherwise the management options for this case would have been:

1. **No treatment of the extraction spaces.** This would help maintain the centre line and increase the space for eruption of mandibular third molars.<sup>21</sup> However, as the first molars had been extracted after eruption of the second molars, space closure would probably have been incomplete with undesirable tipping of the adjacent teeth.<sup>13</sup>


2. **Restoration of the spaces with a removable prosthesis.** This option is relatively simple and could restore occlusal function and prevent space loss and overeruption of the opposing teeth. The disadvantages of a prosthesis are its tendency to retain plaque, the requirement for periodic replacement or adjustment as the child grows, its failure to prevent atrophy of the alveolar ridges, the laboratory fabrication cost and long-term maintenance cost.<sup>22</sup>
3. **Orthodontic closure of the extraction spaces.** This option eliminates the need for a prosthesis, prevents atrophy of the alveolar ridges, increases space for mandibular third molar eruption and provides the best esthetic and functional results.<sup>13</sup> The disadvantages are high cost and duration of treatment. Orthodontic closure of the space left by extraction of a first permanent molar can be technically demanding, although this is now greatly facilitated by additional anchorage provided by mini-implants.<sup>23</sup>
4. **Autotransplantation of the supplemental premolar to restore 1 extraction site.** This option only partly solved the problem as there was only 1 donor tooth. There was also a size discrepancy between the donor tooth and the extraction space. Nonetheless, this option restored 1 side with a natural tooth rather than a prosthesis. The transplanted tooth has a natural gingival contour, normal periodontal support and does not require long-term maintenance.<sup>6</sup> Although only 1 side could be restored, extensive centre-line shift to the untreated side is considered unlikely, as there would still be spacing around the transplanted tooth postoperatively due to its small size.
5. **Implants and fixed prostheses are contraindicated in a growing child.** Fixed bridgework may interfere with the growth of the dental arch, and implants are osseointegrated and would result in infraocclusion as the child grows.<sup>7</sup>

The parents of the child in this case chose option 4, as the treatment cost was covered by their public dental service. The overall treatment outcome is considered less than optimum, as the left extraction site was not restored and the final root length and root mass of the transplanted premolar were less than those of adjacent teeth. Donor teeth in an ectopic position before transplantation and those at an early stage of development will have reduced root growth.<sup>4</sup> In addition, the donor tooth in this case was a supernumerary and its root growth is unpredictable. The small size of the donor tooth allowed the adjacent second molar to tilt slightly mesially. The loose interproximal contacts with the adjacent teeth might also have contributed to the initiation of caries. Nevertheless, the treatment restored esthetics and occlusal function in the right side to a certain extent without the need for a prosthesis.

## Conclusion

Autotransplantation can be a viable option in the replacement of missing permanent teeth in children. When space closure seems undesirable, autotransplantation of a donor tooth can restore the patient's dentition using a natural tooth rather than an artificial device. Clinicians who treat children should, therefore, keep this option in mind during treatment planning. ♦

## THE AUTHORS



*Dr. Cho is senior dental officer, School Dental Care Service, Department of Health, Hong Kong.*



*Dr. Lee is acting senior dental officer, School Dental Care Service, Department of Health, Hong Kong.*

**Correspondence to:** Dr. Shiu-yin Cho, Fanling School Dental Clinic, 2/F Fanling Health Center, 2 Pik Fung Road, Fanling, NT, Hong Kong.

*The authors have no declared financial interests.*

*This article has been peer reviewed.*

## References

1. Andreasen JO, Paulsen HU, Yu Z, Ahlquist R, Bayer T, Schwartz O. A long-term study of 370 autotransplanted premolars. Part I. Surgical procedures and standardized techniques for monitoring healing. *Eur J Orthod* 1990; 12(1):3–13.
2. Andreasen JO, Paulsen HU, Yu Z, Bayer T, Schwartz O. A long-term study of 370 autotransplanted premolars. Part II. Tooth survival and pulp healing subsequent to transplantation. *Eur J Orthod* 1990; 12(1):14–24.
3. Andreasen JO, Paulsen HU, Yu Z, Schwartz O. A long-term study of 370 autotransplanted premolars. Part III. Periodontal healing subsequent to transplantation. *Eur J Orthod* 1990; 12(1):25–37.
4. Andreasen JO, Paulsen HU, Yu Z, Bayer T. A long-term study of 370 autotransplanted premolars. Part IV. Root development subsequent to transplantation. *Eur J Orthod* 1990; 12(1):38–50.
5. Mendes RA, Rocha G. Mandibular third molar autotransplantation — literature review with clinical cases. *J Can Dent Assoc* 2004; 70(11):761–6.
6. Thomas S, Turner SR, Sandy JR. Autotransplantation of teeth: is there a role? *Br J Orthod* 1998; 25(4):275–82.
7. Tsukiboshi M. Autotransplantation of teeth: requirement for predictable success. *Dent Traumatol* 2002; 18(4):157–80.
8. Clokie CM, Yau DM, Chano L. Autogenous tooth transplantation: an alternative to dental implant placement? *J Can Dent Assoc* 2001; 67(2):92–6.
9. Bauss O, Schilke R, Fenske C, Engelke W, Kiliaridis S. Autotransplantation of immature third molars: influence of different splinting methods and fixation periods. *Dent Traumatol* 2002; 18(6):322–8.
10. Kim E, Jung JY, Cha IH, Kum KY, Lee SJ. Evaluation of the prognosis and causes of failure in 182 cases of autogenous tooth transplantation. *Oral Surg Oral Med Oral Pathol Oral Radiol Endod* 2005; 100(1):112–9.
11. Akkocaoglu M, Kasaboglu O. Success rate of autotransplanted teeth without stabilisation by splints: a long-term clinical and radiological follow-up. *Br J Oral Maxillofac Surg* 2005; 43(1):31–5.
12. Batchelor PA, Sheiham A. Grouping of tooth surfaces by susceptibility to caries: a study in 5–16 year-old children. *BMC Oral Health* 2004; 4:2 Available from URL: [www.biomedcentral.com/1472-6831/4/2](http://www.biomedcentral.com/1472-6831/4/2) (accessed April 11, 2007).
13. Gill DS, Lee RT, Tredwin CJ. Treatment planning for the loss of first permanent molars. *Dent Update* 2001; 28(6):304–8.
14. Cooper H, Scherer W, Antonelli J. Autogenous transplant involving a supernumerary tooth. *Gen Dent* 1992; 40(5):432–3.

15. Solares R, Romero MI. Supernumerary premolars: a literature review. *Pediatr Dent* 2004; 26(5):450–8.
16. Kristerson L, Lagerstrom L. Autotransplantation of teeth in cases with agenesis or traumatic loss of maxillary incisors. *Eur J Orthod* 1991; 13(6):486–92.
17. Czochrowska EM, Stenvik A, Bjercke B, Zachrisson BU. Outcome of tooth transplantation: survival and success rates 17-41 years posttreatment. *Am J Orthod Dentofacial Orthop* 2002; 121(2):110–9.
18. Jonsson T, Sigurdsson TJ. **Autotransplantation of premolars to premolar sites.** A long-term follow-up study of 40 consecutive patients. *Am J Orthod Dentofacial Orthop* 2004; 125(6):668–75.
19. Tsukiboshi M, Asai Y, Nakagawa K, Ichiokawa H, Sanada H. Wound healing in transplantation and replantation. In: Tsukiboshi M, editor. *Autotransplantation of teeth*. Chicago: Quintessence Publishing Co Inc.; 2001. p. 21–56.
20. Czochrowska EM, Stenvik A, Album B, Zachrisson BU. Autotransplantation of premolars to replace maxillary incisors: a comparison with natural incisors. *Am J Orthod Dentofacial Orthop* 2000; 118(6):592–600.
21. Ay S, Agar U, Bicakci AA, Kosger HH. Changes in mandibular third molar angle and position after unilateral mandibular first molar extraction. *Am J Orthod Dentofacial Orthop* 2006; 129(1):36–41.
22. Dyson JE. Prosthodontics for children. In: Wei SH, editor. *Pediatric dentistry: total patient care*. Philadelphia: Lea & Febiger; 1988. p. 259–74.
23. Ismail SF, Johal AS. The role of implants in orthodontics. *J Orthod* 2002; 29(3):239–45.