

# Sympathetically Maintained Pain Presenting First as Temporomandibular Disorder, then as Parotid Dysfunction

Subha Giri, BDS, MS; Donald Nixdorf, DDS, MS

## Contact Author

Dr. Nixdorf  
Email: [nixdorf@umn.edu](mailto:nixdorf@umn.edu)



## ABSTRACT

Complex regional pain syndrome (CRPS) is a chronic condition characterized by intense pain, swelling, redness, hypersensitivity and additional sudomotor effects. In all 13 cases of CRPS in the head and neck region reported in the literature, nerve injury was identified as the etiology for pain initiation. In this article, we present the case of a 30-year-old female patient with sympathetically maintained pain without apparent nerve injury. Her main symptoms — left-side preauricular pain and inability to open her mouth wide — mimicked temporomandibular joint arthralgia and myofascial pain of the masticatory muscles. Later, symptoms of intermittent preauricular pain and swelling developed, along with hyposalivation, which mimicked parotitis. After an extensive diagnostic process, no definitive underlying pathology could be identified and a diagnosis of neuropathic pain with a prominent sympathetic component was made. Two years after the onset of symptoms and initiation of care, treatment with repeated stellate ganglion blocks and enteral clonidine pharmacotherapy provided adequate pain relief.

**MeSH Key Words:** complex regional pain syndrome; pain, intractable; parotitis; temporomandibular joint disorders

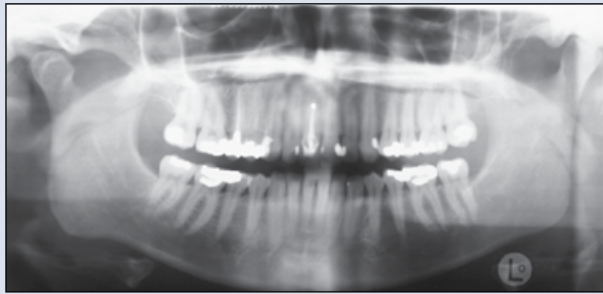
For citation purposes, the electronic version is the definitive version of this article: [www.cda-adc.ca/jcda/vol-73/issue-2/163.html](http://www.cda-adc.ca/jcda/vol-73/issue-2/163.html)

Complex regional pain syndrome (CRPS) is a chronic condition that usually affects extremities, such as the arms or legs. It is characterized by intense pain, swelling, redness, hypersensitivity in a region not defined by a single peripheral nerve and additional sudomotor effects, such as excessive sweating.<sup>1</sup> The clinical criteria for the diagnosis of sympathetically maintained pain as outlined by the International Association for the Study of Pain include:

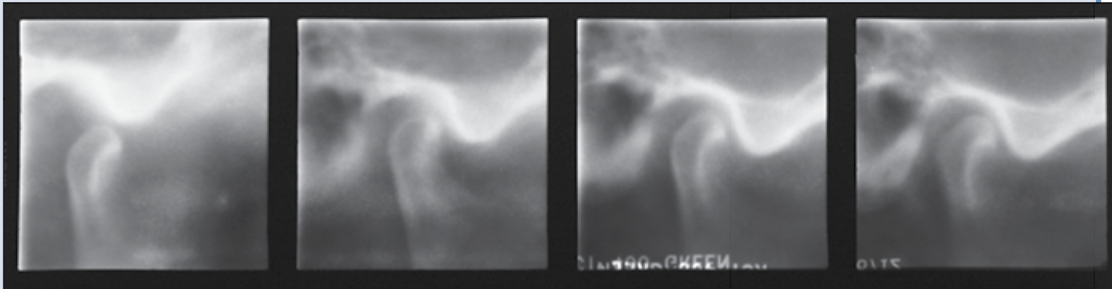
- onset following an initiating noxious event (CRPS-type I) or nerve injury (CRPS-type II)

- spontaneous allodynia that is not limited to peripheral nerve distribution and is not proportionate to the inciting event
- abnormal sudomotor activity, skin blood flow abnormality, edema, other autonomic symptoms
- exclusion of other conditions that may otherwise contribute to the extent of the symptoms.<sup>2</sup>

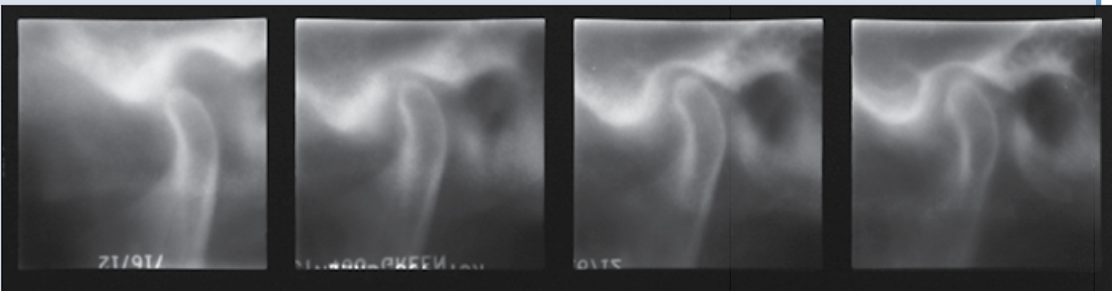
Only 13 cases of CRPS involving sympathetically maintained pain in the head and neck region have been described, and all reported trauma as the identifiable etiologic factor.<sup>3</sup> The case presented here is another



**Figure 1:** Panoramic radiograph showing no overt odontogenic or osseous pathology.



**Figure 2a:** Tomography of the right side of the temporomandibular joint indicating mild regressive bony remodelling.



**Figure 2b:** Tomography of the left side of the temporomandibular joint appearing within normal limits.

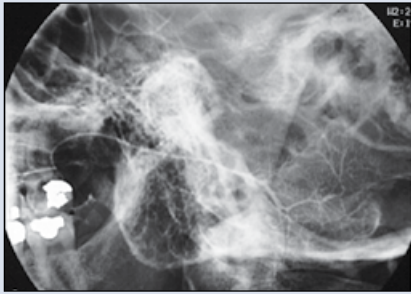
occurrence of sympathetically maintained pain in the head and neck region, but without nerve injury as a clear initiating factor.

### Case Report

A 30-year-old woman initially presented with left-side jaw pain and inability to open her mouth wide. She was not aware of any initiating factors and reported that she had experienced this type of pain intermittently since she was 19 years old. The pain had presenting symptoms typical of a left-side temporomandibular disorder (TMD): dull intermittent preauricular pain of moderate intensity that caused sleep disruption, was aggravated by jaw activity and was alleviated by analgesic use. She reported an episode of pain in the left side of her face one year before the onset of the current complaint; that pain had been diagnosed as an ear infection and was treated

with antibiotics and surgical drainage. In the past, she had been prescribed gabapentin and opioid analgesics for her pain. Clinical findings, also typical of TMD, included mandibular range of motion less than 40 mm, absence of joint noises and excursions, and tenderness of the left temporomandibular joint (TMJ) and masseter muscle to palpation. Panoramic and tomographic imaging revealed slight sclerosis of the anterior aspect of the right condyle with mild flattening (Figs. 1 and 2). No sensory abnormalities of the face or jaws were detected from the history or physical examination using sharp–dull discrimination and sensation of touch with a wisp of cotton. Based on this information, a diagnosis of left-side TMJ arthralgia and myofascial pain of the left masseter muscle was made.

Conservative treatment was initiated — self-care, a maxillary flat-plane occlusal splint and pharmacotherapy with nonsteroidal anti-inflammatory drugs (diclofenac



**Figure 3:** Sialogram of the left parotid gland with no evidence of sialolithiasis.

and nabumetone) and low-dose nortriptyline — but only minimal beneficial effects were achieved. Lidocaine trigger-point injections on the left masseter resulted in reduction of pain to a minimal level; thus, injections were continued monthly for the following 4 months.

After 9 months of stable pain control, the pain progressively increased in intensity. The patient described it as a pressure sensation in her ear, which she perceived as an ear infection. Swelling and redness was noted in the left preauricular, facial and posterior mandibular areas. Clinical examination revealed that the maximal mandibular opening was less than 30 mm; left-side preauricular areas were tender to palpation although the patient's left ear tympanic membrane appeared normal. A diagnosis of acute capsulitis with effusion was made and an intra-articular joint injection of corticosteroids was provided. At this time, chronic pain pharmacotherapy was initiated; nortriptyline, titrated to 30 mg before bedtime, resulted in excellent pain relief. Pain, swelling and redness continued to recur intermittently for about one month.

Six months following the TMJ injection, the patient was referred for an oral medicine consultation to assess for parotitis, despite the normal clear appearance of her saliva. A parotid sialogram revealed no calcification or fibrous tissue within the left parotid gland. She was referred to an ear, nose and throat surgeon for biopsy to confirm a tentative diagnosis of Sjögren's syndrome. Minor salivary gland biopsies of the lower lip, at 2 different times, revealed normal salivary gland histology. Another flare-up of symptoms occurred with the additional new symptom of reduced amounts of saliva. A diagnosis of medication-induced xerostomia with probable secondary infectious sialadenitis was made. A second sialogram was obtained and, again, no abnormalities were detected (**Fig. 3**). Regional magnetic resonance imaging (MRI), from above the TMJs to below the clavicles, was also normal.

A diagnosis of probable sympathetically maintained pain was made based on the presence of fluctuating autonomic symptoms and the absence of any other organic

causes of this patient's pain complaint. A left-side diagnostic stellate ganglion block was performed using 0.5% bupivacaine. Pre-injection pain intensity was 6/10 on a numeric rating scale. Immediate exacerbation of her left-side jaw and neck pain with final needle placement (which was rated as 10/10) occurred with the pain level reduced to 2/10 15 minutes post-injection. An ipsilateral Horner's syndrome was present confirming adequate blockade.

Because of the patient's desire not to receive further injections, pharmacotherapy treatment was initiated, with enteral clonidine starting at 0.1 mg/day at bedtime and increased when sedation was unacceptable to 0.9 mg/day. Topical clonidine was used in a 50% dimethyl-sulfoxide cream, along with gabapentin at 400 mg 4 times a day and Senokot-S (Purdue Pharam, Pickering, Ont.) to counteract the anticholinergic effects of the medication. The pain decreased to an intensity level of 4/10, but over the following 5 months the patient's symptoms slowly progressed with increasing pain and further spread into her left neck, shoulder and forearm.

During this time, the patient displayed symptoms of depression and in a desperate attempt to alleviate her pain she self-administered cannabinoids. When discussing this, she reluctantly revealed that no appreciable pain reduction was experienced, but smoking did provide a "vacation from her situation." Consultation with a psychologist was insisted on (previous attempts to refer her to a psychologist had failed).

The idea of a series of stellate ganglion blocks was reinitiated and executed, resulting in excellent pain relief; a pain level of 0/10 was achieved with occasional exacerbations to 2/10. Pain control was so successful that the dose of enteral clonidine was reduced to 0.1 mg every morning and 0.3 mg at bedtime, and the topical cream was discontinued. After 4 months of good pain control with weekly to biweekly stellate ganglion blocks, the patient was lost to follow-up due to relocation of the care provider.

## Discussion

Very few cases of CRPS in the head and neck region have been reported in the literature. All can be traced back to identifiable etiologic factors involving trauma<sup>3</sup> — CRPS due to penetrating trauma,<sup>4</sup> surgical procedures in the face and jaw,<sup>5-7</sup> vascular surgery of the neck,<sup>8</sup> motor vehicle accident leading to head and neck injury<sup>9,10</sup> and dental extractions.<sup>6,11,12</sup> Our case report is a rare occurrence of sympathetically maintained pain in the head and neck region without identifiable nerve injury as a causative factor. Therefore, the most appropriate diagnosis would be CRPS-type I.

The pathophysiology underlying CRPS is not well understood, but small-fibre degeneration has been shown in patients diagnosed with CRPS-type I despite a lack of clinical findings indicating nerve injury.<sup>13</sup> Obtaining

a skin biopsy to assess for peripheral nerve degeneration, along with detailed neurosensory testing (QST), may help determine the most appropriate diagnosis. (As a full review of the pathophysiology is not within the scope of this article, see Harden and others<sup>14</sup> and Melis and others<sup>3</sup>). Under normal physiological conditions, the sympathetic nervous system does not have a modulatory effect on the nociceptive pathway and does not arise from trigeminal nerve injury.<sup>15,16</sup> Therefore, from a clinical perspective, 2 different factors can be identified as sympathetically maintained pain: sympathetic dysfunction resulting in altered blood flow, temperature and sweating; and alleviation of pain with an anesthetic block of the sympathetic efferent nerves.<sup>14</sup>

The uniqueness of the current case lies in its symptomatic presentation as TMD pain, otherwise known as TMJ arthralgia and myofascial pain of the masticatory muscles, with no apparent trauma to the tissue. In the present case, the initiating noxious event could be viewed as the persistent left-side TMD pain associated with an inner-ear infection. The inability to identify a direct trauma or nerve injury excludes the possibility of causalgia or CRPS-type II. At the same time, it supports the diagnosis of TMD, which often presents with unidentifiable etiology. The clinical findings of spontaneous excruciating pain not proportionate to the extent of the pathology of the region and the sympathetic features of swelling, redness and parotid dysfunction also fulfill the criteria for CRPS. Further support may be drawn from the negative sialograms, which ruled out parotid gland pathology, MRI for the head and neck region, which excluded vascular pathologies, and the effectiveness of the stellate ganglion blocks that reinforced evidence for the involvement of the sympathetic nervous system.

It could be speculated that the involvement of the sympathetic nervous system in the current case resulted from the neuropathic effects of longstanding TMD pain that transformed over time into sympathetically mediated pain. In an animal study of TMJ inflammation and pain, changes within the nerves innervating the disc were shown to be induced.<sup>17</sup> Changes similar to these may result in the expression of adrenergic receptors in the peripheral sensory fibres resulting in sympathetic dysfunction. This is evidenced by the effectiveness of initial TMD care. Also, autonomic features were minimal in the initial presenting symptoms, but they became more prominent as time passed, with intermittent swelling and pain exacerbation spreading into the neck.

It is also possible that the sympathetic involvement pre-existed the labelling of the condition as TMD pain, as evidenced by the patient's admissions to hospital with complaints of preauricular pain and pharmacotherapy with gabapentin before her initial TMD consultation. Also, pre-existing sympathetically maintained pain may have been precipitated by factors, such as minor periph-

eral inflammation and nerve injury secondary to the treatment provided, TMD pain itself or the prior inner ear infection. This pre-existing sympathetic component could have been merely masquerading as a TMD pain complaint, then parotid dysfunction, requiring time and adequate stressors to cause an exacerbation of this centrally mediated pain phenomenon. The initial interpretation of periauricular hyperalgesia with intermittent swelling as being TMD or parotid gland dysfunction would then be best explained as practitioner bias.

## Conclusion

This case report is an example of CRPS-type I with sympathetically maintained pain presenting in the head and neck region that required expertise in both orofacial pain and oral medicine to arrive at an accurate diagnosis. We can extrapolate 2 possible clinical scenarios, which are not mutually exclusive, for how this pain presented: persistent TMD arthralgia and myalgia resulting in central changes that ultimately led to sympathetically maintained pain; and sympathetically maintained pain, masquerading as TMD pain and parotid dysfunction before becoming readily identifiable.

The absence of any identifiable etiologic factors makes this case unique among reported cases of CRPS in the head and neck. It is important for us, as clinicians, to be alert and closely observe patients with long-standing TMD symptoms, so that if neuropathic components of pain arise, they can be identified and treated. ♦

## THE AUTHORS

**Acknowledgements:** The valuable input of Dr. Mariona Mulet at the University of Minnesota and Dr. Seema Ganatra at the University of Alberta is gratefully acknowledged.



**Dr. Giri** is a TMJ specialist with the Minnesota Head and Neck Pain Clinic in Minnesota, Minneapolis.



**Dr. Nixdorf** is an assistant professor in the department of diagnostic and biological sciences, University of Minnesota, Minneapolis, Minnesota.

**Correspondence to:** Dr. Donald Nixdorf, Division of TMJ and Orofacial Pain, School of Dentistry, University of Minnesota, 6-320 Moos Tower, 515 Delaware St, Minneapolis, MN 55455, USA.

The authors have no declared financial interests in any company manufacturing the types of products mentioned in this article.

This article has been peer reviewed.

## References

- Merskey H, Bogduk N, editors. Classification of chronic pain: descriptions of chronic pain syndromes and definitions of pain terms. 2nd ed. Seattle, Wash.: IASP Press; 1994.
- Stanton-Hicks M, Janig W, Hassenbusch S, Haddox JD, Boas R, Wilson P. Reflex sympathetic dystrophy: changing concepts and taxonomy. *Pain* 1995; 63(1):127-33.

3. Melis M, Zawawi K, al-Badawi E, Lobo Lobo S, Mehta N. Complex regional pain syndrome in the head and neck: a review of the literature. *J Orofacial Pain* 2002; 16(2):93–104.
4. Bingham JA. Causalgia of the face: two cases successfully treated by sympathectomy. *BMJ* 1947; 1:804–5.
5. Hanowell ST, Kennedy SF. Phantom tongue pain and causalgia: case presentation and treatment. *Anesth Analg* 1979; 58(5):436–8.
6. Jaeger B, Singer E, Kroening R. Reflex sympathetic dystrophy of the face. Report of two cases and a review of literature. *Arch Neurol* 1986; 43(7):693–5.
7. Khoury R, Kennedy SF, Macnamara TE. Facial causalgia: report of case. *J Oral Surg* 1980; 38(10):782–3.
8. Arden RL, Bahu SJ, Zuazu MA, Berguer R. Reflex sympathetic dystrophy of the face: current treatment recommendations. *Laryngoscope* 1998; 108(3):437–42.
9. Veldman PH, Jacobs PB. Reflex sympathetic dystrophy of the head: case report and discussion of diagnostic criteria. *J Trauma* 1994; 36(1):119–21.
10. Figuerola M, Bruera O, Leston J. Reflex sympathetic dystrophy of the face: an unusual cause of facial pain. *Headache Q* 2000; 11(2):135–7.
11. Behrman S. Facial neuralgias. *Br Dent J* 1949; 86:197–203.
12. Saxen MA, Campbell RL. An unusual case of sympathetically maintained facial pain complicated by telangiectasia. *Oral Surg Oral Med Oral Pathol Oral Radiol Endod* 1995; 79(4):455–8.
13. Oaklander AL, Rissmiller JG, Gelman LB, Zheng L, Chang Y, Gott R. Evidence of focal small-fiber axonal degeneration in complex regional pain syndrome-I (reflex sympathetic dystrophy). *Pain* 2006; 120(3):235–43.
14. Harden RN, Baron R, Janig W. Complex regional pain syndrome: progress in pain research and management, volume 22. Seattle, Wash.: IASP Press; 2001. p. 22.
15. Bongenhillem U, Boissonade FM, Westermark A, Robinson PP, Fried K. Sympathetic nerve sprouting fails to occur in the trigeminal ganglion after peripheral nerve injury in the rat. *Pain* 1999; 82(3):283–8.
16. Benoliel R, Eliav E, Tal M. No sympathetic nerve sprouting in rat trigeminal ganglion following painful and non-painful infraorbital nerve neuropathy. *Neurosci Lett* 2001; 297(3):151–4.
17. Shinoda M, Honda T, Ozaki N, Hattori H, Mizutani H, Ueda M, and other. Nerve terminals extend into the temporomandibular joint of adjuvant arthritic rats. *Eur J Pain* 2003; 7(6):493–505.