

The “Point of Care” section answers everyday clinical questions by providing practical information that aims to be useful at the point of patient care. The responses reflect the opinions of the contributors and do not purport to set forth standards of care or clinical practice guidelines. Readers are encouraged to do more reading on the topics covered. If you would like to submit or answer a question, contact editor-in-chief Dr. John O’Keefe at jokeefe@cda-adc.ca.

QUESTION 1

What should I think about when examining a child who has a primary tooth below the plane of occlusion?

Background to the Problem

Infra-eruption or submersion of a tooth is due to a failure in eruption. The causes include ankylosis, impaction, absence of a permanent successor, disturbances in local metabolism, gaps in the periodontal membrane, trauma, infection, chemical or thermal irritation, failure in bone growth and abnormal tongue pressure.

According to the literature, the prevalence ranges between 1.3% and 38.5%. This wide variation is due to the different criteria used for diagnosis, as well as patient age, type of dentition and ethnicity. It occurs most frequently in the early mixed dentition of children about 8 and 9 years old, but can be seen as early as 3 years of age. It is 10 times more likely in the primary dentition than in the permanent dentition, and the mandibular second primary molar is the tooth most commonly affected, followed by the mandibular first primary molar.¹

Infra-eruption leads to multiple complications, including insufficient development of width and height of supporting bone, increased risk of caries, and gingival hyperplasia and bleeding. If

the permanent successor is present, eruption of a submerged tooth may be delayed or redirected from its normal path into a malaligned position. If the permanent successor is absent, loss of dental arch space is likely, and a midline discrepancy may occur because the mesiodistal width of the primary submerged tooth is greater than that of the contralateral premolar. Also, overeruption of the opposing teeth and tilting of the adjacent teeth can occur, which further contributes to dental malocclusion (Fig. 1).

Diagnosis

Clinical examination reveals that the primary tooth is below the level of the occlusal plane (Fig. 2). Tapping the tooth reveals an abnormal percussive “cracked teacup” sound; if there is ankylosis, the tooth is immobile. Radiographic images show lack of a well-defined periodontal ligament and lamina dura space and fusion of the root with bone. However, fusion may occur in an isolated area, often at the furcation, and this method of detection is therefore unreliable.¹ Sometimes, there is a depression in the marginal bone surrounding the submerged teeth, and often the permanent successor is lacking.

Management of the Problem

The course of treatment in the primary or mixed dentition depends on whether the tooth is ankylosed and whether a permanent successor is present.

If the tooth is not ankylosed, waiting for normal exfoliation has been suggested; this process is usually delayed by 6 to 12 months relative to the unaffected contralateral tooth. If the premolar is present, spontaneous eruption is possible.² To prevent tipping of the adjacent tooth and overeruption of the opposing tooth, restoration of the occlusal surface is recommended, including a stainless steel crown or composite

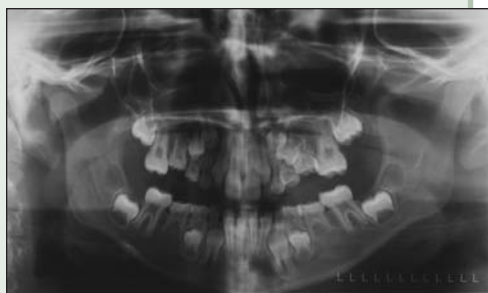

Figure 1: Panoramic radiograph displays mesial tipping of maxillary and mandibular first permanent molars due to submergence of the maxillary and mandibular second primary molars.

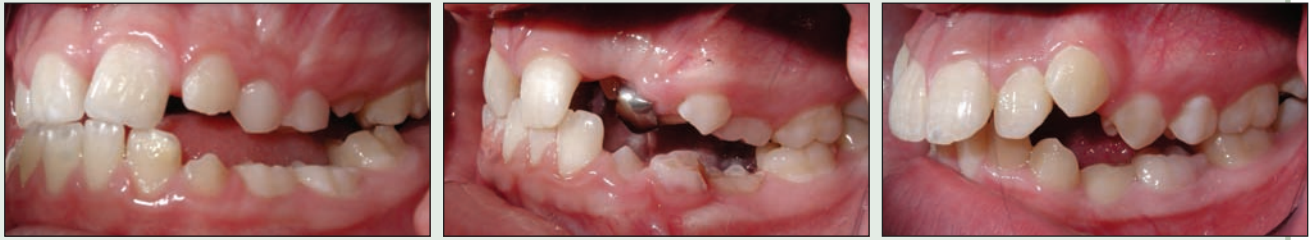

Figure 2: Clinical photographs of submerged mandibular first and second primary molars.

resin buildup.³ Extraction is recommended if there is a progressive, deep infraocclusion below the gingival margin, severe tipping, ectopic eruption of the permanent successor or formation of caries and abscess.

If the permanent successor is absent, the decision to extract depends on the condition of the tooth, the amount of root support, the degree of occlusion and the patient's preference. If a malocclusion exists, the patient should be referred to an orthodontist for evaluation, as extraction of the nonankylosed submerged tooth may influence future orthodontic treatment.

The vast majority of submerged teeth are ankylosed.⁴ If ankylosis is diagnosed, the tooth should be monitored until it interferes with eruption of the succedaneous tooth or until tipping of the adjacent teeth or supraeruption of opposing teeth occurs. It can then be temporarily treated with a stainless steel crown or composite resin buildup to maintain space. As the teeth continue to erupt, the ankylosed tooth is once again left out of eruption. If the dentist notices that tipping is occurring and space is being lost, the tooth should be extracted and space maintenance should be undertaken until the permanent successor has erupted.⁵

Effective diagnosis and careful management of a patient with an infraerupted primary tooth can reduce the need for complex orthodontic treatment in the future. ♦

THE AUTHORS



Dr. James Noble is a second-year orthodontic resident in the faculty of dentistry, University of Manitoba, Winnipeg, Manitoba. Email: umnoble@cc.manitoba.ca.



Dr. Nicholas Karaikos is a second-year orthodontic resident in the faculty of dentistry, University of Manitoba, Winnipeg, Manitoba.



Dr. William A. Wiltshire is professor, head of orthodontics and head of the department of preventive dental science, University of Manitoba, Winnipeg, Manitoba.

References

1. Teague AM, Barton P, Parry WJ. Management of the submerged deciduous tooth: I. Aetiology, diagnosis and potential consequences. *Dent Update* 1999; 26(7):292-6.
2. Kuroi J, Thilander B. Infraocclusion of primary molars and the effect on occlusal development, a longitudinal study. *Eur J Orthod* 1984; 6(4):277-93.
3. Teague AM, Barton P, Parry WJ. Management of the submerged deciduous tooth: 2. Treatment. *Dent Update* 1999; 26(8):350-2.
4. Antoniadis K, Kavadia S, Milioti K, Antoniadis V, Markovitsi E. Submerged teeth. *J Clin Pediatr Dent* 2002; 26(3):239-42.
5. Proffit WR. Contemporary orthodontics. 3rd ed. St. Louis (MO): Mosby Co.; 2000. p. 430-1.

QUESTION 2

How do I manage incisor alignment in the mixed dentition?

Background

Incisor irregularity or poor alignment of the permanent incisors in the early mixed dentition is a common clinical problem. Because of increased awareness of dental esthetics in our society, parents occasionally express concern about this problem when their children are still very young. In addition, some clinicians believe that improving alignment in the mixed dentition results in greater long-term stability and reduces the risk of periodontal problems associated with ectopic eruption. Early interventions may also benefit those who may not have an opportunity for comprehensive orthodontic treatment in the future.

In most cases, alignment problems are caused by inadequate space between the primary canines; however, displacement and/or rotation of the incisors does sometimes occur in the presence of adequate space.

Management of Incisor Alignment

Incisor alignment can be accurately assessed after eruption of the lateral incisors. The first step is to determine the cause of any problems observed and the orthodontic diagnosis. A clinical examination and review of the appropriate clinical records, including orthodontic study models and a panoramic radiograph, are useful in this regard. Specifically, the clinician must determine whether poor alignment of the incisors is due to inadequate space between the primary canines. The options for management are observation or interceptive orthodontics, disking of the

primary teeth, extraction of the primary canines or referral to a specialist.

No Deficiency of Arch Length

Dentists occasionally see patients whose incisors have erupted with rotation and/or displacement, even though adequate space is available. In many of these patients, the alignment improves spontaneously over time. However, in cases where self-correction is minimal, orthodontic correction with fixed or removable appliances is required. A fixed appliance that is commonly used to improve alignment in the mixed dentition is a 2 × 4 preadjusted, fixed edgewise appliance, consisting of bands on the first molars and brackets on the 4 incisors. If such an appliance is used in the maxillary arch, the relationship of the developing canines to the roots of the lateral incisors must be assessed. Any movement of the lateral incisor roots toward the canine crowns can lead to irreversible damage to the roots. Labial or distal flaring of the lateral incisor crowns is a good clinical warning sign of potential problems (**Figs. 1a, 1b**). In these cases it is advisable not to engage the lateral incisors in the arch wire.

Minor (1–4 mm) Crowding

Minor crowding of the incisors is the most commonly encountered scenario. Disking the primary canine is a conservative method of managing these cases. In most patients, up to 2 mm of crowding can be corrected by disking the mesial surface of the deciduous canines; 4 mm of space can be gained by disking the mesial *and* distal surfaces, which allows distal migration of the deciduous canines. Reduction should be done symmetrically to maintain coincident midlines. Disking is best done with a narrow carbide bur (e.g., 169L) in a high-speed handpiece or a one-sided diamond disk. In most cases local anesthetic is not required, and an interproximal wedge can be used to protect the papilla. Fluoride varnish can be applied to the cut surface to minimize sensitivity and the risk of interproximal caries.

Substantial Crowding (5 mm or More)

A deficiency of 5 mm or more usually requires removal of the primary

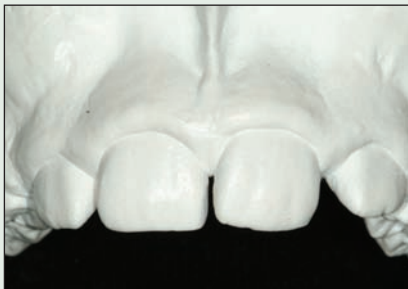

Figure 1a: Incisor alignment before treatment with a 2 × 4 appliance. Note distal flaring of the lateral incisors.

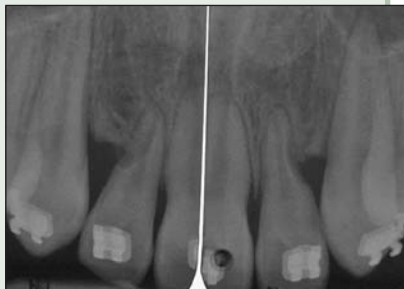

Figure 1b: Periapical radiographs obtained after treatment demonstrate damage to the roots of the lateral incisor.

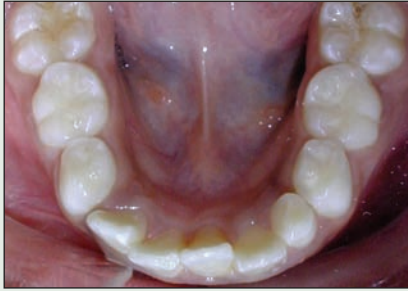

Figure 2: Midline shift after unilateral extraction of the primary canines.

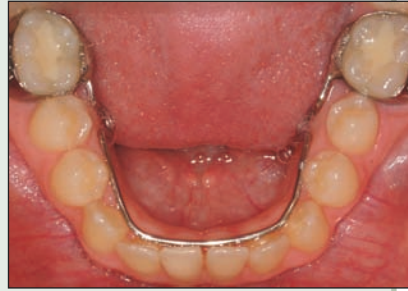

Figure 3: Successful outcome after placement of a lower lingual holding arch in the mixed dentition. Note the excellent alignment of the incisors and maintenance of arch length.

canines to achieve incisor alignment. The space created will allow the incisors to unravel with lateral movement. Spontaneous correction into perfect alignment is unlikely, but several studies have shown significant improvement without further intervention. Space deficiency of this degree is a reliable predictor of future crowding of the entire arch, and consultation with a specialist is therefore recommended. Extraction of the primary canines moves the crowding problem into the posterior segments, where it will probably need to be addressed through comprehensive orthodontics in the future.

If a decision to extract is made, multiple factors should be considered.

- **Symmetry:** Even if there is crowding on only one side, canines should be extracted symmetrically within each arch. Unilateral extractions can cause drifting of the incisors and a midline discrepancy (Fig. 2).
- **Mandibular arch:** Removal of the primary mandibular canines allows the incisors to tip lingually and erupt vertically, resulting in increased overbite and overjet. In addition, mesial movement of the posterior teeth and overall loss of arch length may occur. Placement of a lower lingual holding arch provides an easy and effective solution to prevent these adverse effects. The bar should have a smooth, rounded contour with contact on the cingula of the lower incisors. This will encourage improved alignment while the incisors unravel, prevent any lingual or vertical movement, and preserve existing arch length (Fig. 3).
- **Maxillary arch:** A discussion with the parent regarding the risks and benefits of extracting

the primary maxillary canines is recommended. Removal of the primary canines will improve incisor alignment, but this is usually accompanied by a temporary esthetic impact that may not be acceptable to the patient or parent. If done before the patient is 11 years of age, an additional benefit is prevention of impaction of the permanent canines. Impacted canines are difficult to manage orthodontically and can cause resorption of the roots of the lateral incisors. Extraction of the primary canines should therefore be considered for patients with ectopically erupting permanent canines and a crowded anterior segment. ♦

THE AUTHORS



Dr. Neville Jeannotte is a dentist with an interest in orthodontics practising in Steveston, British Columbia. Email: njeannotte@telus.net.



Dr. Lucien Bellamy is a graduate student in orthodontics at the University of Washington, Seattle, Washington.

Further Reading

- Foley TF, Wright GZ, Weinberger SJ. Management of lower incisor crowding in the early mixed dentition. *ASDC J Dent Child* 1996; 63(3):169–75.
- Kau CH, Durning P, Richmond S, Miotti FA, Harzer W. Extractions as a form of interception in the developing dentition: a randomized controlled trial. *J Orthod* 2004; 31(2):107–14.
- Shapira Y, Kuftinec MM. Early diagnosis and interception of potential maxillary canine impaction. *J Am Dent Assoc* 1998; 129(10):1450–4.

QUESTION 3

Why and how should I remove the smear layer after root canal instrumentation?

Background

Chemomechanical instrumentation of root canals creates a smear layer, an amorphous structure 1–2 μm thick composed of both organic (pulp tissue, microorganisms) and inorganic (dentin debris) materials (Fig. 1). These substances may also be packed to a depth of 40 μm into the dentinal tubules, also known as smear plugs (Fig. 2). By covering the root canal walls and occluding the dentinal tubules, this material prevents optimal penetration of chemicals, medications and root filling agents into the lateral canals and dentinal tubules. Therefore, after root canal preparation is completed, a final rinsing procedure should be performed to remove the smear layer and smear plug (Figs. 3 and 4). This procedure allows effective action of chemicals and intracanal medication within the root canal system and permits a better bond between sealers and dentinal walls. For removal of not only the inorganic but also the organic components of the smear layer, a final rinse with first sodium hypochlorite (NaOCl) and then an acid is recommended. NaOCl has the

unique capacity to dissolve pulp tissue and is an established bactericidal agent. It also has excellent dissolving action on the other organic components of the smear layer. Demineralizing agents such as EDTA (ethylenediaminetetra-acetic acid) and citric acid can dissolve inorganic dentin particles. These acids are highly biocompatible and show high efficiency in removing the smear layer, but they seem to have little or no antibacterial action. Therefore, antiseptics such as detergents (EDTA-C, EDTA-T) or detergents plus tetracycline antibiotics (BioPure MTAD, Tulsa Dental Products, Tulsa, Okla.) have been added to EDTA and citric acid, respectively, to increase their antimicrobial capacity. Prevention and elimination of infection in the root canal system is one of the most important steps for a successful root canal treatment, and the irrigating solutions play an important role in achieving this goal. Performing a final rinse for removal of the smear layer is one more tool for a good treatment outcome, especially when one-appointment therapy is performed and an antibacterial medication is not used.




Figure 1: Micrograph showing the root canal surface covered with smear layer.

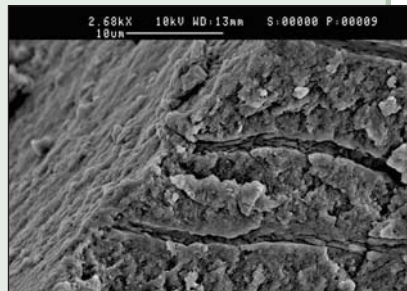


Figure 2: Micrograph showing the entrances of the dentinal tubules filled with smear plugs.




Figure 3: Micrograph showing that the root canal wall is free of smear layer.




Figure 4: Micrograph showing dentinal tubules free of smear plugs.

Procedure

Once the shaping procedure is completed, the canals should be thoroughly rinsed with NaOCl to remove the organic components of the smear layer. All of the NaOCl must then be removed with suction. Reaching the apical third of the root canal is very important. This can be achieved by using a 30-gauge irrigation needle tip and trying to get 1 to 2 mm short of the working length. A #25-30 master apical file must be used for the irrigation needle tip to reach this point. Each canal must then be rinsed for 3 minutes using 5 to 10 mL of a chelator irrigant (15%–17% EDTA, EDTA-C, EDTA-T, or 10% citric acid) and applying an up-and-down motion to the needle. After removal of the smear layer, a final rinse with NaOCl appears beneficial to eliminate any microorganisms that may be inside the dentinal tubules. Then, 1 mL of a 5-mL portion of MTAD must be injected into the canal and allowed to sit for 5 minutes; the

canal is then rinsed with the remaining 4 mL of MTAD, which is removed by suction. The manufacturer does not recommend irrigation with any other irrigant after MTAD. After these procedures, the canal is ready for interappointment medication or for obturation. ✦

THE AUTHOR



Dr. Isabel Mello is a visiting assistant professor in the department of oral biological and medical sciences, faculty of dentistry, University of British Columbia, Vancouver, British Columbia. Email: imello2@hotmail.com.

The author has no declared financial interests in any company manufacturing the types of products mentioned in this article.

Further Reading

- Czonstkowsky M, Wilson EG, Holstein FA. The smear layer in endodontics. *Dent Clin North Am* 1990; 34(1):13–25.
- Haapasalo M, Endal U, Zandi H, Coil JM. Eradication of endodontic infection by instrumentation and irrigation solutions. *Endod Topics* 2005; 10(1):77–102.
- Scelza MF, Antoniazzi JH, Scelza P. Efficacy of final irrigation — a scanning electron microscopic evaluation. *J Endod* 2000; 26(6):355–8.
- Torabinejad M, Handysides R, Khademi AA, Bakland LK. Clinical implications of the smear layer in endodontics: a review. *Oral Surg Oral Med Oral Pathol Oral Radiol Endod* 2002; 94(6):658–66.
- Zehnder M. Root canal irrigants. *J Endod* 2006; 32(5):389–98.

QUESTION 4

Why should chlorhexidine be used as a root canal irrigant?

Background

The major objective in endodontic therapy is to disinfect the entire root canal system. This goal can be accomplished with mechanical instrumentation and chemical irrigation, in conjunction with medication of the canal between treatment sessions.

The current irrigant of choice is sodium hypochlorite (NaOCl). It is an effective antimicrobial agent and acts as an excellent tissue solvent. However, NaOCl can be toxic to the periapical tissues, causing severe inflammatory reactions. In addition, it tends to discolour and corrode operatory items, and it has an unpleasant odour. Instrumentation combined with NaOCl irrigation

has been shown to yield negative results on culture in 37% to 63% of cases. However, even with the use of NaOCl, reliable elimination of organisms from root canal systems remains an elusive goal, and bacteria frequently survive the cleaning and shaping procedures.

Chlorhexidine in Endodontics

Chlorhexidine (CHX), a cationic bisguanide with a pH of 5.5 to 7, was developed more than 50 years ago during investigation of antiviral agents. It had poor antiviral but good antibacterial efficacy.

CHX is a wide-spectrum antibacterial agent and is active against gram-positive and gram-negative bacteria, facultative anaerobic and aerobic bacteria, spores and yeasts (Fig. 1). Being cationic, CHX binds electrostatically to the negatively charged surfaces of bacteria, damaging the outer layers of the bacterial cell wall and rendering it permeable. The resulting penetration of CHX into the cell causes precipitation of the cytoplasm. Its cationic properties also allow CHX to bind electrostatically to the surfaces of the teeth and the CHX molecules are gradually released from the teeth, as the concentration of CHX in the oral environment decreases. This reversible mechanism of uptake and release of CHX is known as “substantivity.” For example, 2% CHX that had been in a root canal for up to 12 weeks still showed antimicrobial activity. CHX has low grade of toxicity.

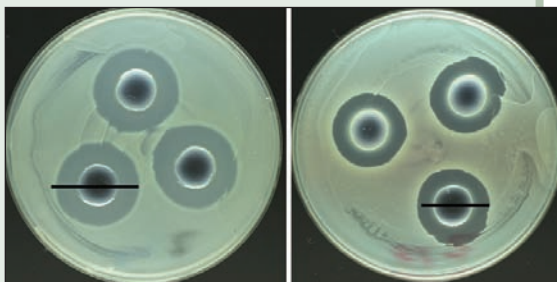


Figure 1: Agar diffusion test with 2% chlorhexidine (left) and 0.2% chlorhexidine (right). The antibacterial effect is concentration-dependent.

CHX has some limitations, including an inability to dissolve organic matter, lack of action on the smear layer, and lack of effect on biofilms. Because CHX forms a precipitate when mixed with NaOCl, interaction with NaOCl should be avoided.

Suggested Clinical Protocol for Irrigation in Endodontics

1. NaOCl solution should be employed throughout instrumentation. The canals should always be filled with fresh NaOCl to dissolve the organic matter present in the canal and to increase the working time of the irrigant.
2. If removal of the smear layer is desired, the canals can be thoroughly rinsed with aqueous EDTA (ethylenediaminetetra-acetic acid) or citric acid once the shaping procedure is completed.
3. After the smear layer is removed, a final rinse with an antiseptic solution such as 2% CHX appears beneficial. CHX is particularly helpful in retreatment cases, where high proportions of

gram-positive bacteria can be expected in the root canal system.

Other indications for the use of CHX are for patients allergic to NaOCl or where it would not be desirable to have NaOCl in contact with periodontal tissues such as perforations or open apices.

Finally, 2% CHX has been suggested for use as an intracanal medication either alone (in liquid form), mixed with a vehicle (in gel form) or mixed with calcium hydroxide (either in gel form or in a slurry preparation). ♦

THE AUTHOR



Dr. Bettina Basrani is an assistant professor and coordinator of the postgraduate endodontic program at the faculty of dentistry, University of Toronto, Toronto, Ontario. Email: bettina.basrani@utoronto.ca. Dr. Basrani is a member of the Canadian Academy of Endodontics.

Further Reading

Basrani B, Lemonie C. Chlorhexidine gluconate. *Aust Endod J* 2005; 31(2):48-52.
Zehnder M. Root canal irrigants. *J Endod* 2006; 32(5):389-98.



IFEA 7TH ENDODONTIC WORLD CONGRESS

IFEA 7th Endodontic World Congress – SuperNatural Endodontics

August 22-25, 2007

Vancouver, British Columbia

Hosted by the International Federation of Endodontic Associations (IFEA) and the Canadian Academy of Endodontics

Held every 3 years, the IFEA Endodontic World Congress is expected to attract over 1,000 participants to Vancouver in August 2007. Global leaders in endodontics will be sharing their knowledge and experience at this multidisciplinary event.

With its theme of SuperNatural Endodontics, the congress will feature a scientific program designed to appeal to all dentists, including restorative and implantologist specialists, general practitioners, teachers of endodontics and dental assistants. The congress will also feature several workshops and hands-on sessions that will offer participants supervised experience in the use of new technologies.

For more information, including a list of speakers and the program at a glance, visit www.ifea2007.com.

ALL DENTISTS ARE WELCOME!