

Use of Autogenous Bone Graft from the Iliac Crest to Restore an Atrophic Maxilla with Implant-Retained Prosthesis

Jack G. Zosky, DDS, FRCD(C), FICD



The "Clinical Showcase" section features step-by-step case demonstrations of clinical problems encountered in dental practice. This month's article is by Dr. Jack G. Zosky, a member of the Canadian Association of Oral and Maxillofacial Surgeons.

In patients with early loss of teeth and protracted denture wear, the residual bony ridge undergoes atrophic changes. This resorption is exacerbated when natural teeth are still present in the opposing arch. The excessive force from the natural dentition causes severe bone loss, producing a so-called "combination syndrome." As a result, the removable prosthesis becomes nonretentive and unstable. In addition, masticatory capacity is diminished, taste buds are negatively affected, speech patterns are altered and pain can ensue through the development of a sharp crest on the ridge. As well, loss of vertical dimension produces an aged appearance.

Fortunately, it is possible to reconstitute the lost structure with surgical grafting techniques. Once the hard-tissue and soft-tissue volumes have been restored, dental implants can be placed, which in turn are used to retain and stabilize a palateless overdenture prosthesis or a fixed ceramic restoration.

The case presented here demonstrates the harvesting of a corticocancellous block bone graft from the anterior iliac crest along with particulate marrow bone. A 63-year-old woman had been edentulous in the maxilla (except for teeth 17 and 27) for over 30 years and had worn a maxillary denture since loss of the maxillary teeth. Extreme atrophy had caused loss of vertical dimension and a pseudo-Class III appearance. The patient was extremely unhappy with the appearance and function of the denture (Figs. 1 and 2). The severely atrophic maxillary ridge was augmented with the block bone in the anterior region, and the particulate bone was used to vertically augment the sub-antral regions following bilateral elevation

of the sinus floor (Figs. 3 to 11). After 5 months for graft consolidation, 8 maxillary endosteal dental implants were placed (Figs. 12 to 16), and ultimately a fixed ceramometal prosthesis was fabricated (Figs. 17 to 21).

After completion of the maxillary treatment, the failing fixed partial denture for the left posterior mandible was replaced with implant-retained posts and crowns, the cantilever pontic in the 46 position was sectioned off, and an implant was placed and restored to give the patient first molar occlusion bilaterally with a level occlusal plane (Fig. 22).

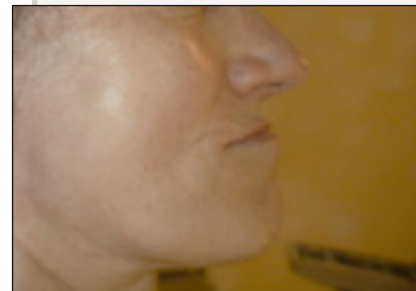

Figure 1: Profile of 63-year-old woman after 30 years of maxillary denture wear. The extreme atrophy has caused loss of vertical dimension and the pseudo-Class III appearance.

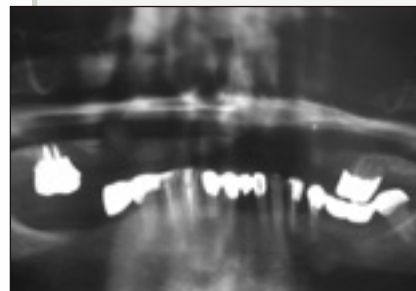


Figure 2: Panorex radiograph shows minimal maxillary alveolar bone with pneumatization of the antra and periodontally hopeless teeth 17 and 27. Note the natural mandibular dentition.

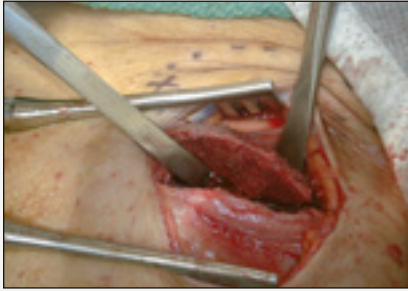

Figure 3: Harvesting of corticocancellous block bone graft from anterior iliac crest.

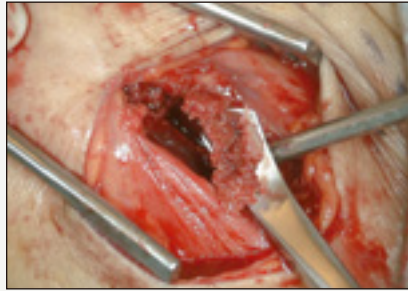


Figure 4: Harvesting of particulate marrow bone.

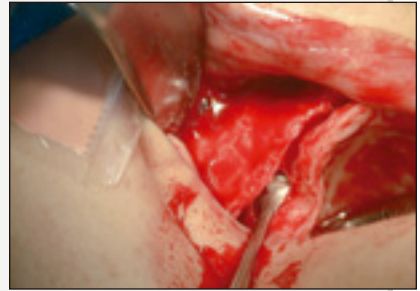


Figure 5: Full-thickness mucoperiosteal flap is raised, exposing the extremely atrophic maxillary ridge. Note the sharp crest.

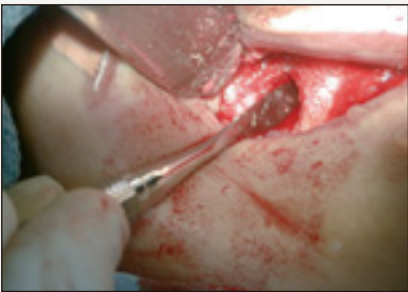

Figure 6: Lateral bony window and elevation of schneiderian membrane of the maxillary antrum.

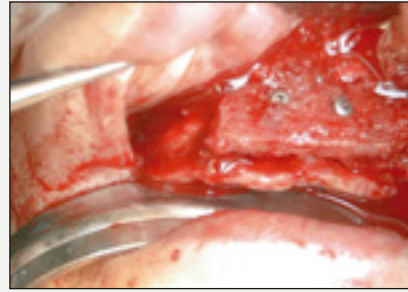

Figure 7: Donor block bone secured to maxillary recipient sites with fixation lag screws for onlay augmentation.

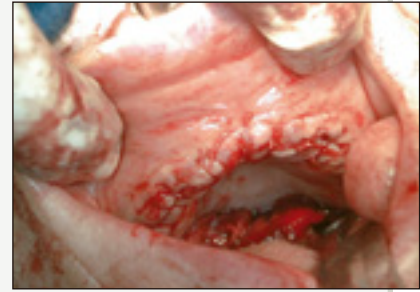


Figure 8: Advancement of soft-tissue flaps to achieve complete coverage of grafted areas. Note new volume of ridge form that has been created.

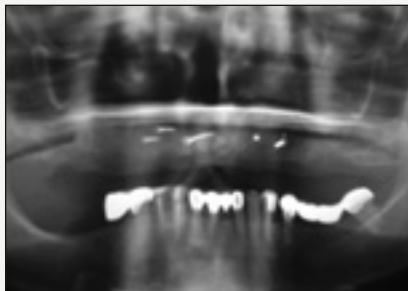


Figure 9: Panorex radiograph shows bone graft with fixation screws in anterior maxilla plus bilateral subantral vertical augmentations in posterior maxilla.

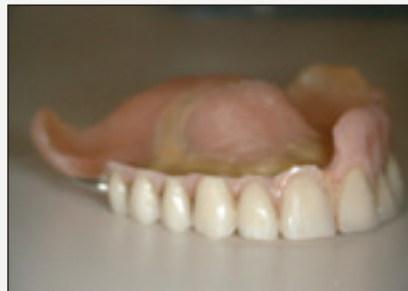

Figure 10: Ten days after graft surgery, the patient's existing denture, which has not been worn in the interim, is adjusted by cutting away the flange and creating a pontic-designed prosthesis.

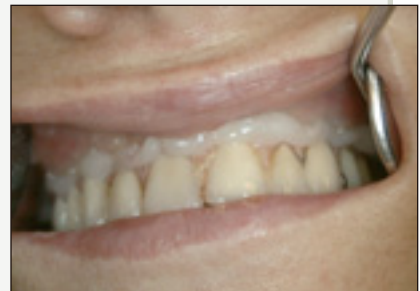

Figure 11: Prosthesis in place with Visco-gel (Dentsply DeTrey GmbH, Konstanz, Germany) soft liner adapted to the intaglio surface of the prosthesis.

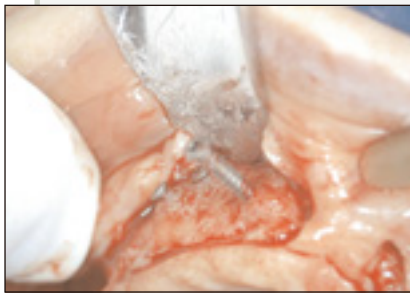

Figure 12: After 5 months of healing, the augmented maxilla is ready for placement of implants. In this image, the fixation screws are being removed. Observe the confluence of the bone graft to the native recipient alveolus.

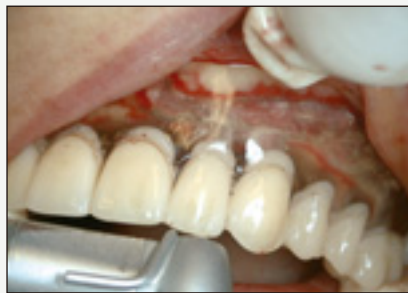

Figure 13: A surgical template based on a diagnostic wax-up of the final prosthesis is being used to position and align the implants in the ideal relationship.

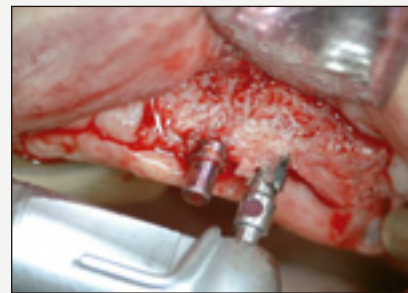


Figure 14: Implants (Nobel Biocare Replace Select, Nobel Biocare, Yorba Linda, Calif.) being placed and positioned parallel to the guide pins.

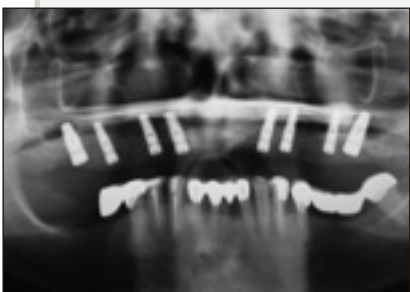


Figure 15: Panorax radiograph of 8 maxillary implants well spaced around the arch.

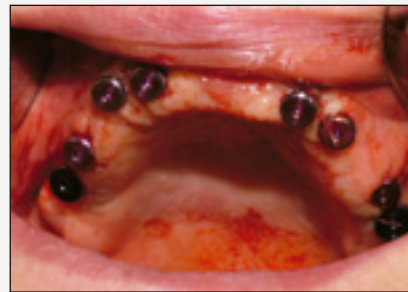

Figure 16: The implants at second-stage surgical uncovering, with healing abutments in place.

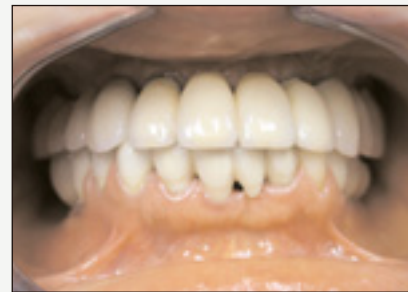

Figure 17: Frontal view of the final fixed ceramometal prosthesis after 2 years in function.

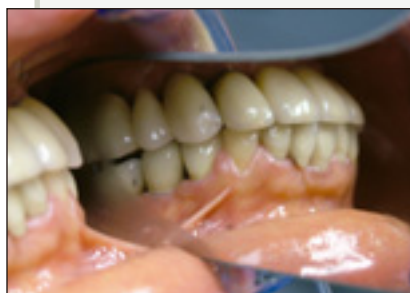

Figure 18: Right profile view of prosthesis.

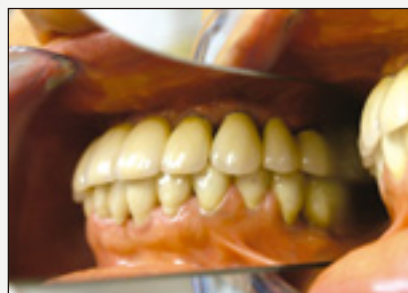

Figure 19: Left profile view of prosthesis.

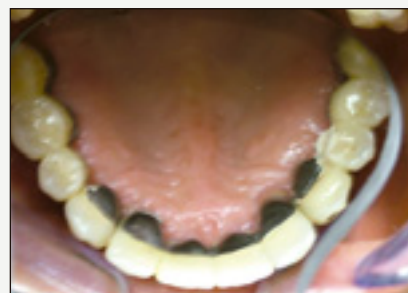


Figure 20: Occlusal view of prosthesis.

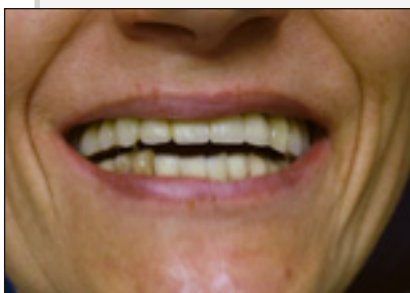

Figure 21: Patient in full smile.

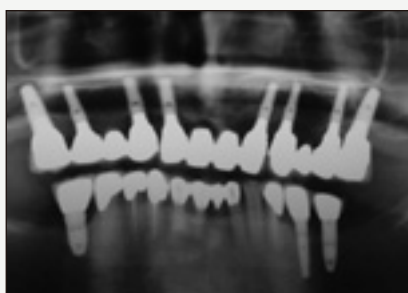

Figure 22: Panorax radiograph of the patient's mouth after 2 years in function. Note the implant-assisted mandibular reconstruction.

Summary of Planning Considerations for Implant Treatment of the Edentulous Maxilla

1. Patient's objective, such as a simple desire for better retention and stability of a removable prosthesis or a preference for a fully fixed prosthesis.
2. Patient's general health.
3. Evaluation of quality and quantity of available bone.
4. Esthetic demands dictated by lip support, smile line, and other factors.
5. Patient consent regarding potential morbidity associated with graft harvest sites.
6. Financial capabilities.

Conclusions

This comprehensive surgical and prosthetic rehabilitation is complex and exacting but with insightful cooperation between surgeon, restorative dentist and laboratory technician, the patient's quality of life can be greatly enhanced. Many long-term edentulous patients suffer from masticatory deficiency, mucosal hypertrophy with epulides, inflammatory palatal mucositis, halitosis, nutritional concerns and low self-esteem with emotional and psychological overtones. An implant-borne fixed prosthesis can eliminate most if not all of these problems. ♦

THE AUTHOR

Acknowledgement: The author wishes to acknowledge the fine prosthetic rehabilitation performed by Dr. Tudor Dabuleanu.



Dr. Zosky is an oral and maxillofacial surgeon with a private practice in Toronto, Ont. He is also an associate in dentistry at the University of Toronto and on staff at the Trillium Health Centre.

Correspondence to: Dr. Jack Zosky, 1401-123 Edward St., Toronto, ON M5G 1E2. Email: jzosky@bellnet.ca.

Dr. Zosky is a clinical consultant for Nobel Biocare and teaches continuing education courses for the company.

Further Reading

Branemark PI, Grondahl K, Worthington P. Osseointegration and autogenous onlay bone grafts: reconstruction of the edentulous atrophic maxilla. Chicago: Quintessence Publishing Co., 2001.

Jensen OT. The sinus bone graft. Chicago: Quintessence Publishing Co., 1999.

Block M. Colour atlas of dental implant surgery. Philadelphia: W.B. Saunders Co., 2001.

Music puts a smile on their faces!

To find out if you need a SOCAN performing rights licence, visit our Website or call 1-800-557-6226 today.



what's right for music
la musique a ses droits

