

Cleidocranial Dysplasia: 2 Generations of Management

John Daskalogiannakis, DDS, MSc, FRCD(C); Luis Piedade, BSc, DDS;
Tom C. Lindholm, DDS, PhD; George K.B. Sándor, DDS, MD, PhD, FRCD(C), FRCS(C), FACS;
Robert P. Carmichael, DDS, MSc, FRCD(C)

Contact Author

Dr. Daskalogiannakis
Email:
[john.daskalogiannakis@
sickkids.ca](mailto:john.daskalogiannakis@sickkids.ca)



ABSTRACT

Patients with cleidocranial dysplasia (CCD) commonly present with significant dental problems, such as retention of multiple deciduous teeth, impaction or delay in eruption of permanent teeth and, often, the presence of supernumerary teeth. Several approaches have been described for the management of such patients. We report 2 cases illustrating the shift in the management paradigm from edentulation and prosthetic replacement to orthodontically assisted forced eruption and fixed appliance orthodontic treatment combined with orthognathic surgery.

MeSH Key Words: cleidocranial dysplasia; malocclusion/prevention & control; orthodontic appliances

© J Can Dent Assoc 2006; 72(4):337–42
This article has been peer reviewed.

Cleidocranial dysplasia (CCD) is a rare disorder of autosomal dominant inheritance that causes disturbances in the growth of the bones of the cranial vault, the clavicles, the maxilla, the nasal and lachrymal bones and the pelvis. Patients with CCD usually present with shorter stature and frontal, parietal and occipital bossing of the skull. An increased interorbital distance may occur, with the bridge of the nose appearing wide and flat. Underdevelopment of the maxilla and relative mandibular prognathism are common.¹ The ability to approximate the shoulders anteriorly is related to clavicular hypoplasia and is the classic diagnostic sign of the disorder.²

Dental problems present the most significant manifestation of CCD; they usually include retention of multiple deciduous teeth, impaction or delay in eruption of permanent teeth and the presence of a varying number of supernumerary teeth.¹ Jensen and Kreiborg³ have suggested that supernumerary teeth form as a result of activation of remnants of the dental lamina left unresorbed during odonto-

genesis. Crowding of the dental arches caused by these supernumerary teeth may play a role in arresting the eruption of permanent teeth or forcing them into ectopic locations. However, the contributory role of supernumerary teeth to the arrested eruption of permanent teeth is believed to be secondary to that of diminished bone resorption. In radiographic images of people afflicted with CCD, alveolar bone can appear striated and hyperostotic. Delayed or arrested eruption has also been attributed to lack of cellular cementum.⁴ However, after histomorphometric analysis of 2 permanent teeth extracted from a person with CCD, Counts and others⁵ concluded that there was no difference in the percentage of root covered by cementum between these teeth and others extracted from control patients.

In terms of dental management of CCD, several approaches have been reported over the years. The option of no treatment was common in the past.⁶ Edentulation followed by provision of dentures has also been suggested.¹ Some regard this approach as too invasive, especially considering the extensive bone loss experienced after removal

Case 1

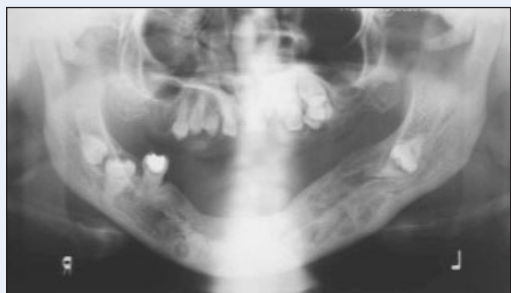

Figure 1a: Pretreatment panoramic radiograph.

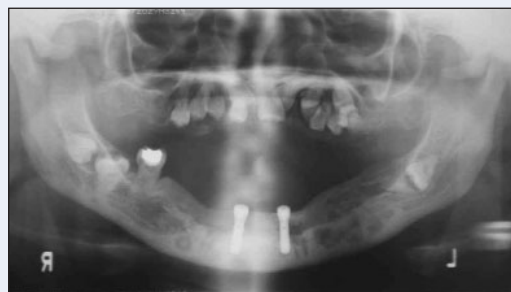

Figure 1b: Post-treatment panoramic radiograph.

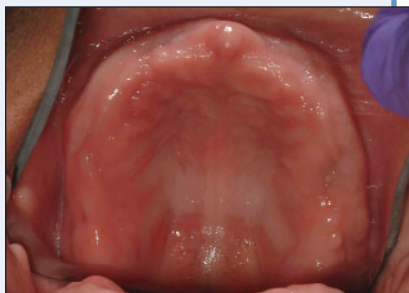
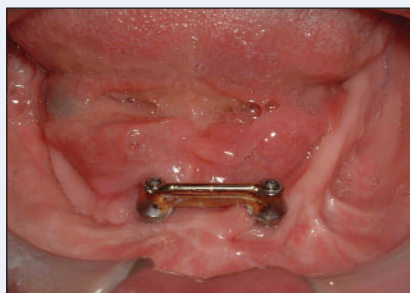
Figure 1c: Post-treatment intraoral views.

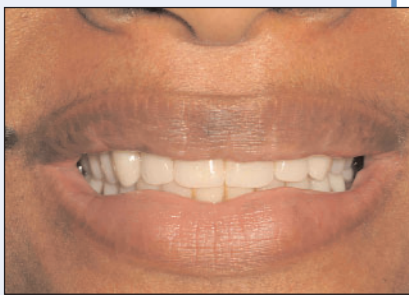
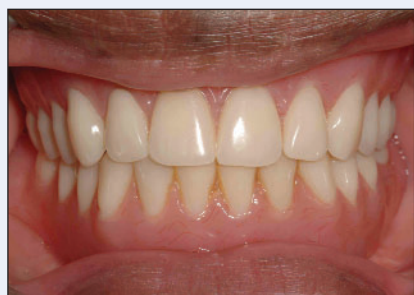
Figure 1d: Post-treatment frontal intraoral view of the prosthesis and “tooth-to-lip” relationship.

The current “state-of-the-art” treatment involves a combination of orthodontics and maxillofacial surgery.^{8–10} Our protocol involves timely extraction of deciduous teeth, staged surgical removal of supernumerary teeth, exposure of selected unerupted permanent teeth and orthodontic forced eruption. The process is usually carried out in stages, as teeth that are guided into their ideal position in the arch can subsequently serve as vertical stops to maintain the vertical dimension while the next group of unerupted teeth is exposed and bonded. Following alignment of all permanent teeth, any underlying skeletal discrepancy (most commonly a Class III skeletal malocclusion) can be corrected through orthognathic surgery after completion of growth.^{8,11,12}

What follows is a report of the treatment of 2 patients with CCD, a mother and her son. The contrast between treatments of the 2 patients reflects the shift in the management paradigm over the span of a generation.

Case 1

A 39-year-old woman with a history of CCD originally presented with the chief complaint of an ill-fitting mandibular complete denture. Most of her mandibular teeth had been removed at a young age and she had not been able to tolerate a lower denture since her teenage years. In the maxilla, however, the patient wore a denture comfortably. The only occlusal contact of the upper denture was with tooth 46. Multiple impacted teeth were present in the maxilla, whereas in the mandible, both third molars were horizontally impacted and tooth 47 was vertically impacted (Fig. 1a)

To minimize the risk of a pathologic fracture of the mandible, the deeply impacted mandibular molars were retained. Dental implants (solid screw, 4.1-mm diameter, SLA; Straumann, Waldenburg, Switzerland) were placed at sites 33 and 43 and a bar-retained

overdenture was provided for the mandibular arch¹³ (Figs. 1b–1d).

The patient has returned annually for 4 years. Her implants remain stable, there is no radiographic evidence of any marginal bone loss and the prostheses remain well fitting.

of teeth in a patient already deficient in alveolar bone. Pusey and Durie⁷ suggested removal of only the erupted teeth and use of a removable prosthesis to minimize alveolar bone loss. However, subsequent eruption of retained teeth can require further surgery and modification of the prosthesis.⁶

Case 2

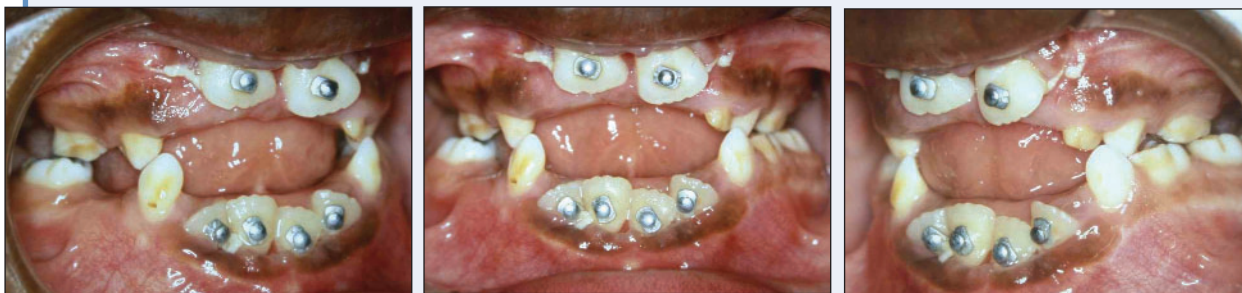

Figure 2a: Intraoral photos at the start of treatment.

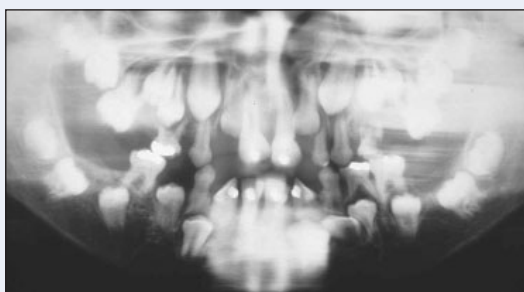


Figure 2b: Panoramic radiograph at the start of treatment.

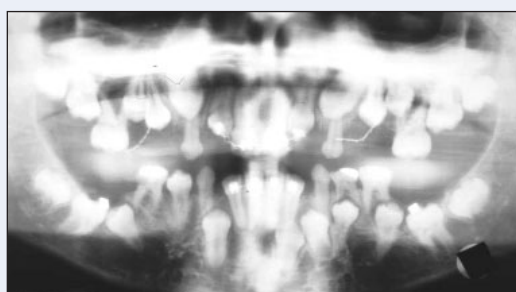


Figure 2c: Exposure of the maxillary lateral incisors and first premolars and bonding of neodymium-iron-boron magnets to the mandibular second molars.

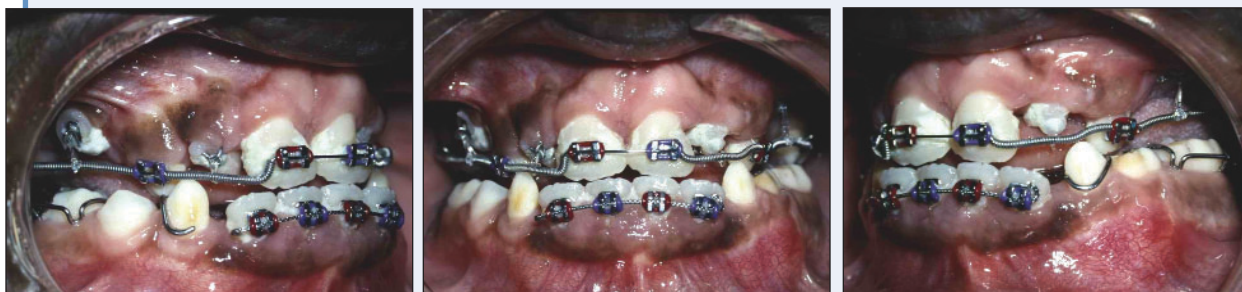

Figure 2d: A maxillary 0.016-inch by 0.022-inch stainless steel base arch is used to tie the exposed lateral incisors and first premolars with elastomeric thread.

Case 2

The son of the patient described in Case 1 — an 8-year-old boy with CCD — initially presented to the orthodontic clinic at the Hospital for Sick Children with retention of multiple deciduous teeth and delay in eruption of permanent teeth. The maxillary central incisors and the mandibular central and lateral incisors were only partly erupted, and a severe anterior open bite was present (Fig. 2a). As the edges of the maxillary and mandibular incisors were situated somewhat apical to the alveolar crest, the anterior open bite was deemed to be due to incomplete eruption of the incisors rather than a habit. A mesial-step terminal place relationship existed between the maxillary and mandibular second deciduous molars.

The maxillary first permanent molars were also partly erupted, whereas the mandibular first molars had already been lost to caries. A supernumerary tooth was present in the lower left canine area (Fig. 2b).

Initially, buttons were bonded to the erupted maxillary and mandibular incisors and vertical intermaxillary elastic traction was applied to assist their further eruption and promote closure of the anterior open bite. The occlusal contacts between teeth 54 and 85, 63 and 74 and 64 and 75 served to maintain the vertical dimension of the occlusion during this time. Once the mandibular incisors were adequately erupted, segmental orthodontic appliances were placed to aid in preliminary alignment of the maxillary central incisors and the mandibular central and lateral incisors.

Case 2 continued

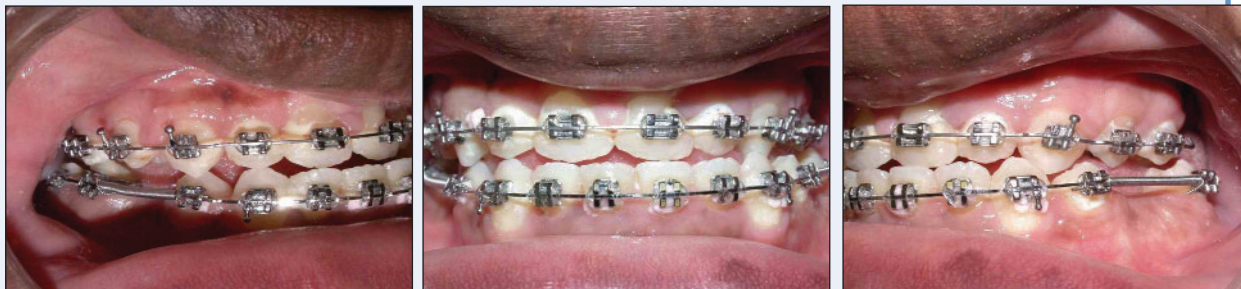

Figure 2e: Presurgical occlusal relationship.

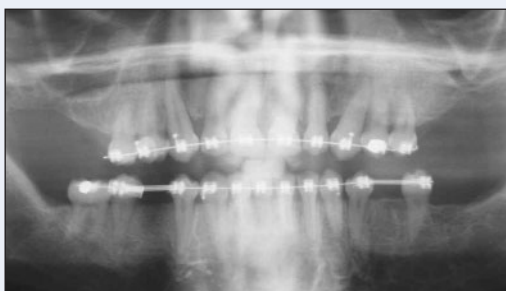

Figure 2f: Presurgical panoramic radiograph.

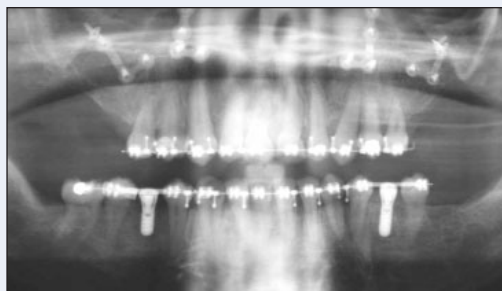


Figure 2g: Postsurgical panoramic radiograph.

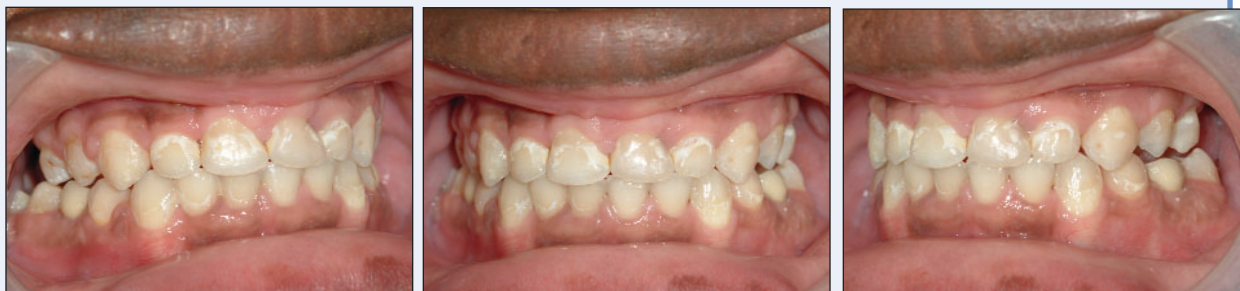

Figure 2h: Intraoral views after removal of orthodontic appliances and completion of the mandibular implant-supported crowns.

Following this, the maxillary lateral incisors and first premolars were exposed and traction hooks were placed on them (Fig. 2c). At the same time, forced eruption of the deeply impacted mandibular second molars was attempted by bonding parylene-coated neodymium-iron-boron magnets to them.

A mandibular Hawley appliance was fabricated with 2 larger magnets in direct juxtaposition with the magnets on the teeth to attempt their disimpaction by making use of the attractive magnetic forces through the tissue. This approach proved unsuccessful and, despite a number of modifications to achieve the best position for the larger magnets on the appliance, it was eventually aborted.

The maxillary arch was bonded from first molar to first molar and the traction hooks were tied to a stiff stainless steel archwire with elastic thread (Fig. 2d).

Sequential extractions and exposures followed by forced orthodontic eruption continued over several years as the patient's compliance with appointments dwindled under the taxing burden of care. The limited mouth opening (16 mm) made access to the posterior teeth very difficult. The maxillary first molars were lost to caries and, later, the maxillary second molars and the mandibular left second molar were deemed to be ankylosed. They were subsequently removed along with the third molars.

Eventually, good arch alignment of the remaining teeth was achieved, although a Class III interarch relation and an anterior crossbite remained due to the maxillary hypoplasia. The plan was to address this through orthognathic surgery. To avoid over-retraction of the mandibular incisors, which would compromise the skeletal correction,

a decision was made to open 7–8-mm-wide spaces for additional prosthetic teeth between the mandibular premolars in each quadrant (Figs. 2e and 2f).

A Le-Fort I maxillary osteotomy was undertaken to advance the maxilla by 4–5 mm asymmetrically and achieve coincident midlines while correcting the anterior crossbite. During the same procedure, 2 dental implants (Standard Plus, 4.1-mm diameter, SLA; Straumann) were placed in the mandibular spaces (Fig. 2g). The occlusal and skeletal outcomes were highly satisfactory. However, due to the significantly prolonged duration of the orthodontic treatment (a little over 10 years) and the patient's deficient oral hygiene, generalized marked decalcification was evident at removal of the orthodontic appliances (Fig. 2h).

Discussion

Planning treatment for a patient with CCD is complicated by a host of factors. The plan is largely dependent on both the chronological and dental ages of the patient, which, due to the frequency of delayed eruption in this condition, are frequently not coincident. The timing of diagnosis is not only important in choosing an appropriate treatment plan but also in attaining a successful result.^{3,14} Because typically no pain, swelling or difficulty in functioning is present in the young patient with CCD and the distinctive facial features are not usually sufficiently disfiguring,¹⁰ the patient's perception of the need for treatment may deviate from that of the treating practitioner. Coupled with the fact that the parent (often also afflicted with CCD) may have some personal experience of the burden of care involved, this makes it difficult for the patient to consent to a treatment involving multiple surgical exposures and forced eruption of teeth. In our experience, treatment initiated early has a better prognosis, but patients and parents should be informed at the outset of its extended duration and the unpredictability of achieving eruption of all teeth, especially in more severe cases.

In the first reported case, placement of 2 dental implants in the anterior mandible and replacement of the existing prostheses was the treatment of choice. This treatment has become widely regarded as the standard of care for the edentulous mandible.¹⁴ In this case, the impacted mandibular molars were retained because they did not obstruct optimal placement of the implants and their removal would have potentially weakened the mandible to the point of risking a pathologic fracture.

The second case reported involved multiple surgical exposures of unerupted teeth and orthodontic treatment to establish an intact and aligned dental arch. Following this, at skeletal maturity, the underlying skeletal deformity was corrected and an improved occlusal relationship was attained through a maxillary advancement osteotomy. This combined orthodontic–surgical approach yielded

satisfactory results, as the natural dentition could be spared and good occlusal function and esthetics achieved. The obvious disadvantage of this approach is the extensive duration of treatment, requiring multiple surgical procedures, which taxes the patient and challenges the treating practitioners.

Conclusion

Two very different cases of CCD are presented, each with radically diverse goals. Both treatments successfully met the objectives set out for each case. When establishing an appropriate treatment plan for a patient with CCD, the expected duration of treatment, the age of the patient and the patient's attitude toward treatment are important considerations. For patients with questionable motivation, a prosthetic alternative may be a more realistic option. ♦

THE AUTHORS



Dr. Daskalogiannakis is coordinator of orthodontics at the Bloorview Kids Rehab, staff orthodontist at The Hospital for Sick Children, and assistant professor in the department of orthodontics, University of Toronto, Ontario.



Dr. Piedade is a dental intern at Mount Sinai Hospital, Toronto, Ontario.



Dr. Lindholm is formerly clinical fellow in oral and maxillofacial surgery. He is currently in private practice in Turku, Finland.



Dr. Sándor is coordinator of pediatric oral and maxillofacial surgery at The Hospital for Sick Children and Bloorview Kids Rehab, professor at the University of Toronto, and docent in oral and maxillofacial surgery, University of Oulu, Finland.



Dr. Carmichael is coordinator of prosthodontics at The Hospital for Sick Children and Bloorview Kids Rehab and assistant professor at the University of Toronto, Ontario.

Correspondence to: Dr. John Daskalogiannakis, Division of Orthodontics, The Hospital for Sick Children, 555 University Ave., Toronto, ON M5G 1X8.

The authors have no declared financial interests in any company manufacturing the types of products mentioned in this article.

References

1. Winter GR. Dental conditions in cleidocranial dysostosis. *Am J Orthod Surg* 1943; 29(2):61–89.
2. Mundlos S. Cleidocranial dysplasia: clinical and molecular genetics. *J Med Genet* 1999; 36(3):177–82.
3. Jensen BL, Kreiborg S. Development of the dentition in cleidocranial dysplasia. *J Oral Pathol Med* 1990; 19(2):89–93.
4. Rushton MA. An anomaly of cementum in cleido-cranial dysostosis. *Br Dent J* 1956; 100:81–83.
5. Counts AL, Rohrer MD, Prasad H, Bolen P. An assessment of root cementum in cleidocranial dysplasia. *Angle Orthod* 2001; 71(4):293–8.
6. Becker A. The orthodontic treatment of impacted teeth. London: Martin Dunitz Ltd.; 1998. p. 199–227.

7. Pusey RF, Durie JF. A case of cleidocranial dysostosis showing failure of eruption of teeth. *Br Dent J* 1943; 75:11–13.
8. Hall RK, Hyland AL. Combined surgical and orthodontic management of the oral abnormalities in children with cleidocranial dysplasia. *Int J Oral Surg* 1978; 7(4):267–73.
9. Smylski PT, Woodside DG, Harnett BE. Surgical and orthodontic treatment of cleidocranial dysostosis. *Int J Oral Surg* 1974; 3(6):380–5.
10. Becker A, Lustmann J, Shteyer A. Cleidocranial dysplasia: Part 1—General principles of the orthodontic and surgical treatment modality. *Am J Orthod Dentofacial Orthop* 1997; 111(1):28–33.
11. Farrar EL, Van Sickels JE. Early surgical management of cleidocranial dysplasia: a preliminary report. *J Oral Maxillofac Surg* 1983; 41(8):527–9.
12. Trimble LD, West RA, McNeill RW. Cleidocranial dysplasia: comprehensive treatment of the dentofacial abnormalities. *J Am Dent Assoc* 1982; 105(4):661–6.
13. Feine JS, Carlsson GE, Awad MA, Chehade A, Duncan WJ, Gizani S, and others. The McGill consensus statement on overdentures. Mandibular two-implant overdentures as first choice standard of care for edentulous patients. In: Feine JS, Carlsson GE, editors. *Implant overdentures: the standard of care for edentulous patients*. Chicago: Quintessence; 2003. p. 155–7.
14. Tasar F, Bulut E, Tumer C, Saysel M, Muhtarogullari M. Cleidocranial dysplasia. Case report. *Aust Dent J* 1995; 40(6):352–6.