

Sinonasal Undifferentiated Carcinoma of the Maxillary Sinus

Paul C. Edwards, MSc, DDS; Stephen J. Hess, MS, DDS; Tarnjit Saini, MS, DDS

Contact Author

Dr. Edwards

Email:

Pedwards@creighton.edu



ABSTRACT

We describe the case of a 43-year-old man who was referred to our dental school's acute care clinic with pain and swelling of presumed dental origin in the left maxillary quadrant. Radiographic examination revealed extensive dental decay and periodontal disease. On questioning, the patient admitted to paresthesia of recent onset. Paresthesia associated with pain or swelling of the jaws is an ominous sign that should alert the clinician to the possibility of an underlying aggressive neoplasm. In this case, biopsy of the lesion confirmed that the patient had a rare malignant tumour of maxillary sinus origin, a sinonasal undifferentiated carcinoma.

MeSH Key Words: carcinoma/diagnosis; maxillary sinus; paranasal sinus neoplasms/diagnosis; paranasal sinus neoplasms/pathology

© J Can Dent Assoc 2006; 72(2):163-7
This article has been peer reviewed.

A healthy 43-year-old man was referred to our dental school's acute care clinic with the chief complaint of pain and swelling of the left maxillary quadrant. The patient had just completed a 10-day course of penicillin VK (500 mg, 4 times daily) for a presumed infection of odontogenic origin with minimal improvement in his symptoms. His past medical history revealed a 3 pack/day cigarette smoking habit. He had been taking ibuprofen for pain.

Clinical examination showed a moderately firm soft-tissue swelling in the area of the left maxillary buccal sulcus; its maximum dimension measured 3 cm. The lesion was mildly painful to palpation. A panoramic radiograph submitted by the referring dentist (**Fig. 1**) revealed multiple missing and decayed teeth and generalized moderate to severe periodontal bone loss. In the left maxillary quadrant, teeth 22, 23 and 28 had moderate to extensive decay. Teeth 22, 24, 25, 27 and 28 had M3 mobility. Tooth 22 was percussion sensitive and was initially deemed by the referring

clinician to be the source of the apparent infection. A poorly defined opacification was noted in the area of the left maxillary sinus. The floor, roof and posterior and medial walls of the left maxillary sinus appeared intact. An incidental dome-shaped radiopacity, consistent with an antral pseudocyst, was noted in the right maxillary sinus.

On further questioning, the patient reported slight paresthesia involving the distribution of the middle and posterior superior alveolar nerves.

Teeth 22, 23, 24, 25, 27 and 28 were judged to be nonrestorable and were extracted under local anesthesia. Some purulent drainage was obtained. In light of the patient's history of paresthesia, a biopsy of the involved areas was deemed necessary to rule out the possibility of an underlying malignant process. Surgical exploration of the area revealed an irregular 1 cm by 1 cm bony defect filled with granulation-like tissue on the anterior-facial wall of the left maxillary sinus. This soft tissue was submitted for histopathologic examination.

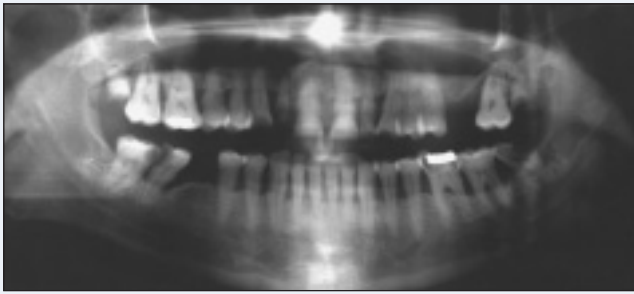


Figure 1: Panoramic radiograph reveals a poorly defined opacification located in the area of the left maxillary sinus. The inferior, posterior and medial walls of the left maxillary sinus and the left orbital floor all appear to be intact. An incidental dome-shaped radiopacity, consistent with an antral pseudocyst, is noted in the right maxillary sinus.

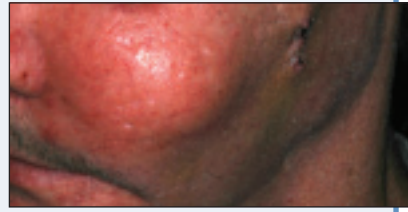

Figure 2: Post-treatment extraoral photograph taken at the follow-up appointment. Substantial expansion is apparent over the area of the left maxillary sinus. The skin lesion lateral to the swelling (right side of photograph) represents the site of a previously biopsied incidental benign skin lesion.

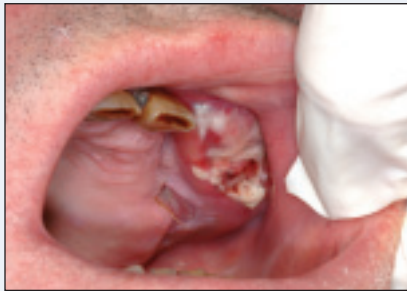

Figure 3: Post-treatment intraoral photograph taken at the follow-up appointment. A sizable intraoral mass is evident in the area of the left maxillary buccal sulcus. The healing extraction sockets along the residual alveolar ridge are still visible.

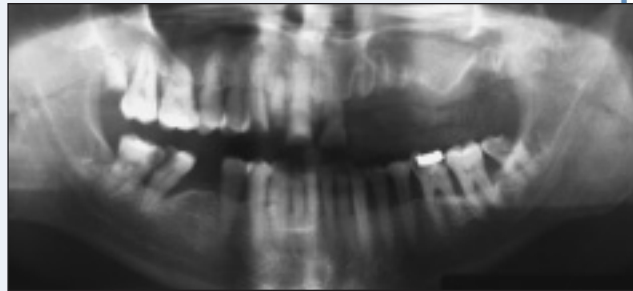

Figure 4: Post-treatment panoramic radiograph taken at the follow-up appointment. The opacification of the left maxillary sinus has expanded to involve the entire left maxillary sinus. Intraoral extension of this mass is also evident. The inferior, posterior and medial walls of the left maxillary sinus and the left orbital floor still appear to be intact.

The patient was prescribed 300 mg clindamycin every 6 hours for 7 days and scheduled for follow-up.

At the follow-up appointment, the swelling had significantly increased in size, as viewed both extraorally (**Fig. 2**) and intraorally (**Fig. 3**). A post-treatment panoramic radiograph (**Fig. 4**) revealed that the area of opacification had expanded to involve the entire left maxillary sinus.

Microscopic examination of the biopsy specimen revealed a malignant nonkeratinizing epithelial neoplasm, consisting primarily of small round cells with minimal cytoplasm and hyperchromatic nuclei (**Fig. 5a**). Histologically, this represented a small round blue-cell tumour. Immunohistochemical staining was performed to further clarify the nature of this neoplasm. The tumour cells were positive for epithelial markers (cytokeratin 7, cytokeratin 20, AE1/AE3 [**Fig. 5b**]) and negative for neuroendocrine markers (neuron-specific enolase, chromogranin, synaptophysin), melanoma markers (S-100, Mart-1), muscle markers (myogenin), white-blood-cell markers (leukocyte common antigen) and markers of

connective tissue origin (vimentin). A diagnosis of sinonasal undifferentiated carcinoma (SNUC) was reached.

The patient was referred to the head and neck surgery department of a local hospital where contrast-enhanced computed tomography was performed. The scan revealed significant destruction of the medial and lateral walls of the maxillary sinus as well as of the left orbital floor.

The patient opted to undergo combined surgical and radiation treatment, consisting of a left hemi-maxillectomy with left lateral nasal wall excision followed by postoperative radiation therapy. In preparation for radiation therapy, the patient also underwent complete dental clearance. Due to the extensive infiltration of the maxillary sinus by the tumour, complete surgical resection with negative margins could not be achieved.

Discussion

In the vast majority of cases, clinical examination of patients presenting with pain and swelling of the jaws will

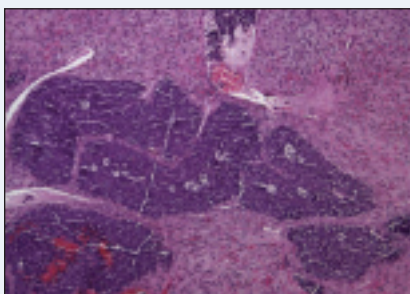


Figure 5a: Histologic examination of the biopsy specimen. Conventional hematoxylin and eosin staining demonstrates a malignant non-keratinizing epithelial neoplasm, consisting primarily of small round cells with minimal cytoplasm and hyperchromatic nuclei (original magnification 50x).

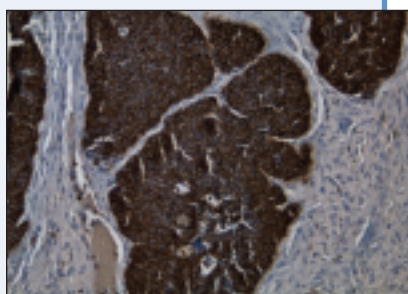


Figure 5b: Immunohistochemical staining. The specimen has been stained with an anti-epithelial specific antibody (anti-AE1/AE3) in conjunction with immunoperoxidase staining. The brown areas represent neoplastic cells of presumed epithelial origin (original magnification 100x).

reveal lesions of dental etiology, most commonly related to pulpal or periodontal pathology. However, when faced with such a situation, the dental practitioner must consider the possibility of a nondental etiology.

When formulating a differential diagnosis for a swelling in proximity to the jaws, it is often helpful to determine first, by radiographic examination, whether the enlargement originates primarily in bone or in the extraosseous soft tissue. Common intraosseous expansile radiolucent lesions would include central giant-cell granulomas, developmental odontogenic cysts (e.g., dentigerous cyst, odontogenic keratocyst), as well as odontogenic tumours (e.g., ameloblastoma). When faced with an expansile radiopaque or mixed radiopaque–radiolucent intraosseous lesion, the practitioner should also consider the possibility of a benign fibro-osseous lesion.

An infection of odontogenic origin is the most common cause of a soft tissue swelling of the maxillary buccal vestibule. Less common reactive or neoplastic lesions of connective tissue origin, such as inflammatory myofibroblastic tumour, nodular fasciitis, myofibroma and desmoplastic fibroma, should also be included in the differential diagnosis.¹ Finally, the possibility of a malignant neoplasm of the maxillary antrum, although uncommon, should be considered.

Given this patient's extensive dental decay and periodontal disease and the absence of obvious bony destruction on panoramic radiography, it was initially felt that this swelling was most likely the result of an acute dental abscess secondary to pulpal involvement. However, in light of the patient's history of paresthesia, surgical exploration of the area was performed, revealing extensive destruction of the facial wall of the left maxillary sinus. The associated soft tissue swelling was the result of

tumour expansion through a defect in the anterior–facial wall of the left maxillary sinus. Biopsy confirmed the presence of a malignant tumour of the maxillary sinus.

Signs that should alert the clinician to the possibility of a malignant tumour include paresthesia, radiographic evidence of irregular bone resorption and localized irregular widening of the periodontal ligament.² Of these, altered sensation (paresthesia) is an especially ominous sign. Although paresthesia can be related to nerve damage secondary to previous surgical procedures, metabolic disorders or infection,³ it is mandatory that the possibility of a malignant neoplasm be ruled out in all patients presenting with paresthesia. Additional symptoms that

are commonly noted with involvement of the sinonasal complex include maxillary swelling, epistaxis, nasal obstruction or discharge, diplopia and proptosis.⁴ When these classic signs are not present, the possibility of a malignant tumour may be overlooked.⁵

The fact that bony destruction was not evident on initial panoramic evaluation should remind the clinician of the limitations of this form of radiographic examination.⁶ Although destruction of maxillary sinus walls, especially the inferior antral wall, can be identified by panoramic radiography in many advanced cases of maxillary sinus malignancies,⁷ this imaging modality may not show evidence of early bone destruction. Computed tomography is the examination of choice in this situation.

Malignant neoplasms of the paranasal sinuses and nasal cavity are rare, comprising only 3% of all head and neck malignancies.⁸ This includes both primary sinonasal neoplasms⁹ (e.g., squamous cell carcinoma, nasopharyngeal carcinoma, lymphoma, esthesioneuroblastoma, primary sinonasal melanoma and adenocarcinoma of minor salivary gland origin) and metastatic disease.

Although a detailed analysis of the histologic findings is beyond the scope of this article, a brief review of the techniques used to arrive at a definitive diagnosis is warranted. Under light microscopy, many sinonasal neoplasms appear to be composed of small to medium-sized cells that stain blue with conventional hematoxylin and eosin (H&E) staining. The category of round blue-cell tumours is quite large and can include malignant tumours such as an olfactory neuroblastoma, small-cell neuroendocrine carcinoma, SNUC, malignant melanoma, lymphoma, rhabdomyosarcoma and Ewing's sarcoma.

Immunohistochemistry is an important tool that can be valuable in reaching a diagnosis in such a situation. It

uses specific antibodies to stain conventionally prepared tissue sections. The antibodies recognize specific antigens expressed by different tumours, depending on their cell of origin. In this case, the use of a panel of immunohistochemical markers showed that the tumour was of epithelial origin and lacked any evidence of neuroendocrine, muscle, melanocyte or leukocyte differentiation. This allowed proper classification of the tumour as an SNUC — a malignant tumour of the sinus (sinonasal) that is of epithelial origin (carcinoma), but lacks evidence of keratin production (undifferentiated).

SNUC is a rare, highly aggressive malignant tumour, apparently derived from the lining epithelium of the paranasal sinuses and nasal cavity. It was first classified as a separate entity in 1986 based on its distinct histology, immunohistochemical profile and clinical course.¹⁰ The etiology of sinonasal carcinomas is unknown. There may be an association with cigarette smoking and a previous history of radiation therapy.¹⁰ In contrast to nasopharyngeal carcinoma, an association with Epstein-Barr virus infection has not been demonstrated. No specific occupational exposure has been implicated.

At initial diagnosis, the tumour is often quite extensive, with orbital and cranial involvement common.¹¹ Due to the small number of cases seen, the ideal treatment regimen has not been systematically evaluated. However, treatment generally involves surgical removal of the tumour.¹² Patients with SNUC have a high rate of both local–regional recurrence and distant metastasis. Moreover, because of the complex anatomy of the head and neck area, complete removal of the tumour with wide margins is not always possible. Consequently, surgery is commonly combined with radiation or chemotherapy or both.

Unfortunately, the prognosis for a patient with SNUC is extremely poor; most patients die of local disease within 1 year of diagnosis.¹³ Nevertheless, long-term survival has been documented in some patients,¹⁴ especially in cases diagnosed early in the disease process.

Conclusions

The presence of paresthesia, irregular bone resorption and localized irregular widening of the periodontal ligament are ominous signs that should alert the clinician to the possibility of a malignant process involving the jaws.

We present the case of a patient with a maxillary soft tissue swelling, initially thought to represent an infection of odontogenic origin. However, a history of paresthesia raised the possibility that this might represent a malignant tumour. Biopsy of the lesion confirmed the clinical suspicion of a rare malignant tumour of maxillary sinus origin: an SNUC.

Clinicians should be aware that the clinical signs and symptoms that might lead one to suspect a malignancy might be relatively nonspecific, potentially leading to a delay in diagnosis. Therefore, it is important for the dental

practitioner to maintain a high index of suspicion to allow for early recognition and referral of these patients. Close follow-up is required in all cases involving swellings of the head and neck. In the presence of ominous signs, such as pain and swelling with associated paresthesia, or if conventional therapy fails to resolve the swelling rapidly, prompt referral for biopsy and advanced imaging techniques, such as computed tomography, is mandatory. ♦

THE AUTHORS

Acknowledgements: We would like to thank Drs. John E. Fantasia and Robert Kelsch, division of oral and maxillofacial pathology, department of dental medicine, Long Island Jewish Medical Center, New Hyde Park, N.Y., and Drs. David Williams and Brad Hammond, department of oral and maxillofacial surgery, Creighton University School of Dentistry, Omaha, Nebraska, for their assistance.



Dr. Edwards is an assistant professor in the division of oral and maxillofacial pathology, department of general dentistry, Creighton University School of Dentistry, Omaha, Nebraska.



Dr. Hess is an assistant professor in the division of oral and maxillofacial pathology, department of general dentistry, Creighton University School of Dentistry, Omaha, Nebraska.



Dr. Saini is a professor in the division of oral and maxillofacial radiology, department of general dentistry, Creighton University School of Dentistry, Omaha, Nebraska.

Correspondence to: Dr. Paul C. Edwards, Division of Oral and Maxillofacial Pathology, Department of General Dentistry, Creighton University School of Dentistry, 2500 California Plaza, Omaha, NE 68122.

The authors have no declared financial interests.

References

- Haddad AJ, Avon SL, Clokie CM, Sandor GK. Nodular fasciitis in the oral cavity. *J Can Dent Assoc* 2001; 67(11):664–7.
- Georgiou AF, Walker DM, Collins AP, Morgan GJ, Shannon JA, Veness MJ. Primary small cell undifferentiated (neuroendocrine) carcinoma of the maxillary sinus. *Oral Surg Oral Med Oral Pathol Oral Radiol Endod* 2004; 98(5):572–8.
- Morse DR. Infection-related mental and inferior alveolar nerve paresthesia: literature review and presentation of two cases. *J Endod* 1997; 23(7):457–60.
- Hone SW, O’Leary TG, Maguire A, Burns H, Timon CI. Malignant sinonasal tumours: the Dublin Eye and Ear Hospital experience. *Ir J Med Sci* 1995; 164(2):139–41.
- Selden HS, Manhoff DT, Hatges NA, Michel RC. Metastatic carcinoma to the mandible that mimicked pulpal/periodontal disease. *J Endod* 1998; 24(4):267–70.
- Lilienthal B, Punna-Moorthy A. Limitations of rotational panoramic radiographs in the diagnosis of maxillary lesions. Case report. *Aust Dent J* 1991; 36(4):269–72.
- Epstein JB, Waisglass M, Bhimji S, Le N, Stevenson-Moore P. A comparison of computed tomography and panoramic radiography in assessing malignancy of the maxillary antrum. *Eur J Cancer Oral Oncol* 1996; 32B(3):191–201.
- Franchi A, Moroni M, Massi D, Paglierani M, Santucci M. Sinonasal undifferentiated carcinoma, nasopharyngeal-type undifferentiated carcinoma, and keratinizing and nonkeratinizing squamous cell carcinoma express different cytokeratin patterns. *Am J Surg Pathol* 2002; 26(12):1597–604.
- Goldenberg D, Golz A, Fradis M, Martu D, Netzer A, Joachims HZ. Malignant tumors of the nose and paranasal sinuses: a retrospective review of 291 cases. *Ear Nose Throat J* 2001; 80(4):272–7.
- Frierson HF Jr, Mills SE, Fechner RE, Taxy JB, Levine PA. Sinonasal undifferentiated carcinoma. An aggressive neoplasm derived from Schneiderian epithelium and distinct from olfactory neuroblastoma. *Am J Surg Pathol* 1986; 10(11):771–9.

11. Kim BS, Vongtama R, Julliard G. Sinonasal undifferentiated carcinoma: case series and literature review. *Am J Otolaryngol* 2004; 25(3):162–6.
12. Day TA, Beas RA, Schlosser RJ, Woodworth BA, Barredo J, Sharma AK, Gillespie MB. Management of paranasal sinus malignancy. *Curr Treat Options Oncol* 2005; 6(1):3–18.
13. Jeng YM, Sung MT, Fang CL, Huang HY, Mao TL, Cheng W, and other. Sinonasal undifferentiated carcinoma and nasopharyngeal-type undifferentiated carcinoma: two clinically, biologically, and histopathologically distinct entities. *Am J Surg Pathol* 2002; 26(3):371–6.
14. Miyamoto RC, Glich LL, Biddinger PW, Gluckman JL. Esthesioneuroblastoma and sinonasal undifferentiated carcinoma: impact of histological grading and clinical staging on survival and prognosis. *Laryngoscope* 2000; 110(8):1262–5.