

Transient Loss of Power of Accommodation in 1 Eye Following Inferior Alveolar Nerve Block: Report of 2 Cases

Wei Cheong Ngeow, BDS (Mal), FFDRCS Ireland, AM (Mal);

Chen Kiong Shim, BDS (Mal), FDSRCS (Eng);

Wen Lin Chai, BDS (Mal), FDSRCS (Eng), MDSc (Mal)

Contact Author

Dr. Ngeow

Email: ngeow@um.edu.my



ABSTRACT

Unintended intravascular injection from inferior alveolar nerve blocks can result in frustrating distant complications affecting such structures as the middle ear and eyes. Possible complications affecting the eyes include blurring of vision, diplopia, mydriasis, palpebral ptosis and amaurosis (temporary or permanent). In this article, we present a complication that has been reported only rarely. Two patients developed transient loss of power of accommodation of the eye resulting in blurred vision after routine inferior alveolar nerve blocks on the ipsilateral side. Clear vision returned within 10–15 minutes after completion of the blocks. The possible explanation for this phenomenon is accidental injection into the neurovascular bundle of local anesthetic agents, which were carried via the blood to the orbital region. This resulted in paralysis of a branch of cranial nerve III, the short ciliary nerves that innervate the ciliary muscle, which controls accommodation.

MeSH Key Words: anesthesia, dental/adverse effects; diplopia/chemically induced; eye/drug effects

© J Can Dent Assoc 2006; 72(10):927–31
This article has been peer reviewed.

The administration of local anesthetic is one of the most common procedures in dentistry. Hundreds of thousands of anesthetic agents are injected daily without serious complications.^{1,2} Nevertheless, this procedure carries the risk of a number of potential complications for the patient, which can be classified as local, distant or systemic.^{1,3–8}

Localized complications include separation of the needle, hyperesthesia or a burning sensation during injection, persistent post-injection paresthesia, hematoma formation that may result in trismus or infection, sloughing of tissues, postanesthetic intraoral lesions and self-inflicted soft-tissue trauma (e.g., cheek biting).^{4–10} Hyperesthesia during

injection may be a result of accidental injection into the neurovascular bundle.

Other nerves may also be affected by intra-oral local anesthesia injection. Facial nerve paralysis will occur if cranial nerve (CN) VII is affected.⁴ There are also reports of trauma to both lingual nerve and chorda tympani after inferior dental injections.^{3,11,12} These accidents have resulted in permanent alteration of sensation in the lingual nerve, inferior alveolar nerve or both.¹¹

Structures further from the oral cavity, including the middle ear¹³ and the eye,¹⁴ can also be affected by intraoral local anesthesia. Distant complications to the eye have been reported more frequently than middle-ear

problems. Patients have experienced visual or motor problems, either from a posterior superior alveolar injection or an inferior alveolar injection.¹⁵ Visual problems include blurring of vision^{16,17} and amaurosis or blindness, which can be temporary¹⁸ or permanent.¹⁹⁻²¹ Motor problems include mydriasis,¹⁴ palpebral ptosis^{14,18} and diplopia.^{18,22-30} Horner-like manifestations involving ptosis, enophthalmos and miosis of the eye have also been reported.¹⁴

Fortunately, most complications in the eye have been transient. For example, Rood¹⁸ reported a case in which 1.5 mL of lidocaine with epinephrine (1:80,000) was injected into an inferior alveolar nerve. Immediate loss of vision developed in the ipsilateral eye, along with upper-eyelid ptosis and medial strabismus, which resulted in double vision. The patient also developed ischemia of the palatal mucosa. However, within 5–45 minutes, all symptoms had disappeared.¹⁸ Unfortunately, cases of permanent complications have also been reported.¹⁹⁻²¹

Systemic complications can result from accidental intravascular injection, drug overdose, rapid absorption, delayed biotransformation, slow elimination, vasovagal syncope, allergies and anaphylactic reaction.^{4,10,31,32} Among complications involving the orbit, the most notable are temporary paralysis of the cranial nerves that govern eye movement: the oculomotor (CN III), trochlear (CN IV) and abducens (CN VI) nerves.^{18,22-26,29} A literature search revealed 2 brief mentions of abnormality in a patient's power of accommodation.^{16,17} This effect has also been discussed briefly in a colour atlas of dental analgesia.³³

Following are 2 case reports of a complication involving only the patient's power of accommodation on the ipsilateral side after administration of local anesthetic using the conventional inferior alveolar nerve block technique.

Case 1

A 20-year-old medically fit woman was scheduled to have her lower right third molar removed under local anesthesia in what was believed to be a routine minor surgical procedure. Her contralateral lower wisdom tooth had been removed without complications about 2 years earlier.

A conventional inferior alveolar nerve block was being administered to the right mandible of the semi-reclined patient when she suddenly felt a sharp shooting pain in the right side of her face. At that point, 4.4 mL of 2% lidocaine with adrenaline (1:80,000), or 2 cartridges, had been delivered. The patient stated she had blurry vision and subsequent examination revealed that power of accommodation was lost in the right eye. She reported only blurred foggy vision. Otherwise, she felt fine, although a little nervous and apprehensive.

Clinical examination revealed that her right eye was able to distinguish gross items, e.g., number of fingers, but was unable to focus on small print. There was no accompanying paresthesia of the lateral parts of the upper and lower eyelids, nor was there any blanching around the same region. She was not experiencing diplopia.

After discussing this unusual complication with the patient and her mother, it was decided to proceed with the minor oral surgery and consult an ophthalmologist should the patient's power of accommodation not improve after the effect of the local anesthetic had disappeared. The surgical procedure was uneventful. The loss of power of accommodation lasted only about 15 minutes, and the patient remained sufficiently numb in the dental region for the surgery to be carried out without pain or additional local anesthetic. The numbness wore off about 3 hours after the initial injection.

Unknown to the surgeons, the patient drove herself home (a 10-minute journey) with the consent of her mother. The authors only learned about this when querying her about the details of her complication for this article. At the time, she felt that her visual acuity had improved sufficiently to allow her to drive.

Case 2

During a practice exercise at the faculty of dentistry of the University of Malaya, a healthy 21-year-old dental student was given a conventional inferior nerve block in the left mandible that resulted in complete anesthesia of the inferior alveolar and lingual nerves. One of the authors (WCN) was demonstrating the standard technique when, on completion of the block, the student complained of not being able to see clearly with her left eye. She was reassured that this effect was transient and, as predicated, her power of accommodation returned to normal 10 minutes later. Half an hour later, her fellow students performed another conventional inferior alveolar nerve block on the opposite side without any further complications.

Discussion

Visual acuity refers to the clarity of one's vision; it is a measure of how well a person sees. This clarity depends on the power of accommodation of the eye. Accommodation is the process that changes the focal length of the eye's lens by altering its curvature. An increase in curvature focuses the eye for near vision, creating a sharp image on the retina, which is interpreted as a clear object by the person concerned. This action depends on the high elasticity of the lens capsule and contraction of the ciliary muscle, which is innervated by the short ciliary nerves.³⁴

The short ciliary nerves are the postganglionic fibres of the ciliary ganglion. The ciliary ganglion is about the size of the head of a pin, quadrangular and flat-

tened; it is reddish-grey in colour and situated in the posterior part of the orbit, close to the apex of the orbit between the optic nerve and the lateral rectus muscle.³³ It generally lies on the outer side of the ophthalmic artery (Fig. 1).³⁴ CN III (occulomotor) provides parasympathetic preganglionic fibres to this ganglion.³⁵ Another nerve, the nasociliary nerve, also provides a communicating branch to the ciliary ganglion. However, it passes through the ganglion without interruption and provides sensation to the eyeball.³⁵

The branches of distribution of the short ciliary nerves are delicate filaments, 6–10 in number. They arise in 2 bundles from the superior and inferior corners of the forepart of the ganglion.³⁴ They run forward with the ciliary arteries in a wavy course, one set above and the other below the optic nerve, and are accompanied by the long ciliary nerves from the nasal branch of the ophthalmic nerve. They pierce the sclerotic plate behind the globe, pass forward in delicate grooves on its inner surface and are distributed to the ciliary muscle, iris and cornea.³⁴

The loss of power of accommodation is a consequence of the paralysis of the ciliary muscle either due to injury or anesthesia of CN III. When complete, paralysis of CN III results in ptosis, external strabismus, dilatation of the pupil and loss of power of accommodation as the sphincter pupillae, the ciliary muscle and the internal rectus are paralyzed.³⁴ Occasionally paralysis may affect only a part of the nerve. Thus, there may be internal strabismus from spasm of the internal rectus; accommodation for near objects only from spasm of the ciliary muscle; or miosis (contraction of the pupil) from irritation of the sphincter of the pupil.³⁴ Similar partial paralysis or, more specifically, paralysis of the short ciliary nerves may have occurred in both cases reported here.

In reporting several cases involving transient amaurosis and diplopia, Blaxter and Britten³⁶ postulated that an intra-arterial injection of the inferior alveolar artery had occurred, with the anesthetic agent travelling to the internal maxillary artery, the middle meningeal artery and, finally, the lacrimal and ophthalmic arteries. Goldenberg^{23,24} reported a similar case following a mandibular injection, and traced the anesthetic to the lacrimal artery. Rood¹⁸ also described a possible arterial route for diffusion of a vasoconstrictive agent from the alveolar artery to the internal maxillary and middle meningeal arteries and, finally, from the lacrimal to the ophthalmic artery by way of anastomotic connections.

The maxillary artery has been shown to have a highly variable relation to the branches of the mandibular

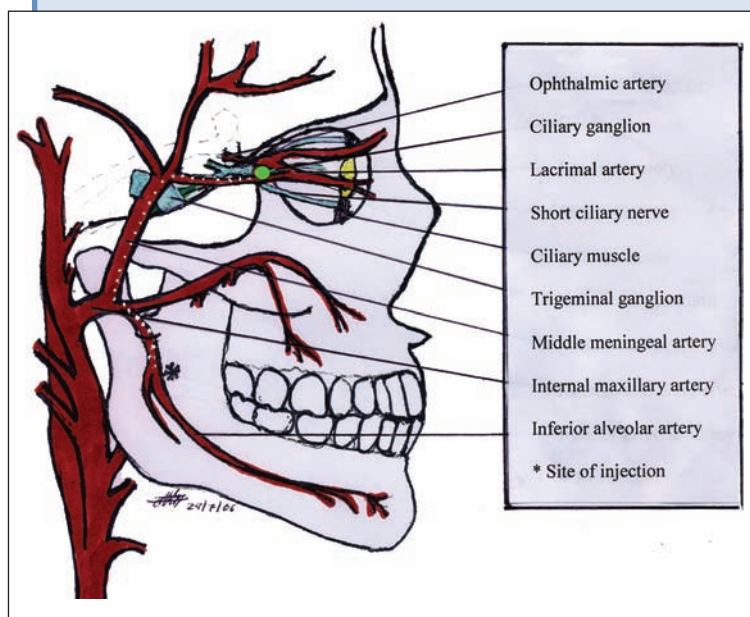


Figure 1: Anatomic relation between the mandible and the orbit. This illustration shows the potential route of dissemination of local anesthetic from the mandible to the short ciliary nerves that innervate the ciliary muscle.

neurovascular bundle³⁷ and enormous individual variation in its topography, diameter, size of the downward loop and its position relative to the mandibular foramen.³⁸ The middle meningeal artery can arise as the second major branch of the maxillary artery.³⁷ Moreover, in 4% of patients, the ophthalmic artery arises not from the internal carotid but from the middle meningeal artery following direct flow from the external carotid artery.³⁹ These variations have been postulated to contribute to ocular complications following intraoral local anesthetic injections. Other authors have proposed the existence of vascular malformations or anomalies that may produce the retrograde anesthetic diffusion phenomenon.^{30,40}

If another block administered to our patient 1 on the same side produced the same loss of visual acuity, then the cause could most certainly be attributed to anatomic variation in the patient.

The frequency of positive aspirations in which injections were given via the conventional inferior alveolar injection technique has been reported to be 7.9%.¹³ Thus, based on the case studies above and the fact that 1 patient (case 1) experienced a sharp shooting pain during the injection, we would like to postulate that due to the constant shifting of position of the needle during administration of the block, the needle penetrated the neurovascular bundle. The surgeon (WCN) may have started depositing the local anesthetic agent when the patient screamed in pain, and the needle was withdrawn

from the painful site. However a tiny bolus of the local anesthetic might have been inadvertently deposited into the artery before withdrawal. This bolus may have found its way into the maxillary artery and, subsequently, been carried to the orbital area, via any of the mechanisms described above.^{16,23–27,30,36–40} We suspect that the amount was only sufficient to anesthetize the short ciliary nerves for a few minutes, but not enough to bring about such signs and symptoms as transient dizziness, paralysis of the eye muscles and anesthesia of the lateral parts of the upper and lower lips.¹⁶ Both our patients remained sufficiently anesthetized for more than 2 hours, compared with Goldenberg's case, where the patient was not anesthetized although exhibiting signs and symptoms of vision problems.^{23,24}

Data obtained by contrast radiography and hemodynamic and electroencephalographic studies in rhesus monkeys indicated that carotid blood flow is reversible.⁴¹ Results showed that even small amounts of local anesthetic agents, when injected inadvertently into a branch of the external carotid artery, may enter the cerebral circulation, most likely through retrograde flow into the common and then internal carotid arteries. Thus, another possible mechanism to explain the loss of power of accommodation is the retrograde flow of local anesthetic agent to the cavernous sinus area. Any cerebral disease causing pressure on the cavernous sinus will result in paralysis of the CN III³⁴ due to their close proximity. In this case, rather than cerebral disease, the cause of paralysis of the nerve concerned was deposition of local anesthetic via retrograde flow.

Although this complication is transient, it is most certainly of concern to both patients and dental surgeons. An aspirating syringe should be used wherever possible to avoid intra-arterial injection. This case also serves as a cautionary tale for all dental surgeons, as patients should be warned of the risks involved.

Conclusions

Unintended intravascular injections from inferior alveolar nerve blocks result in frustrating complications: locally, distally or systemically. It is imperative that dental surgeons diagnose complications and manage them appropriately. Prompt diagnosis and reassurance usually calm the patient. In cases where visual acuity is affected, patients should be advised against dangerous tasks like driving or using sharp instruments, at least until the local anesthetic effect has worn off. ➔

THE AUTHORS



Dr. Ngeow is lecturer in the faculty of dentistry, University of Malaya, Kuala Lumpur.



Dr. Shim is a dental specialist in an oral surgery clinic, Miri General Hospital, Ministry of Health Malaysia.



Dr. Chai is a lecturer in the faculty of dentistry, University of Malaya, Kuala Lumpur.

Correspondence to: Dr. W.C. Ngeow, Department of Oral and Maxillofacial Surgery, Faculty of Dentistry, University of Malaya, 50603 Kuala Lumpur, Malaysia.

The authors have no declared financial interests.

References

- Lustig JP, Zusman SP. Immediate complications of local anesthetic administered to 1,007 consecutive patients. *J Am Dent Assoc* 1999; 130(4):496–9.
- Cawson RA, Curson I, Whittington DR. The hazards of dental local anaesthetics. *Br Dent J* 1983; 154(8):253–8.
- Paxton MC, Hadley JN, Hadley MN, Edwards RC, Harrison SJ. Chorda tympani nerve injury following inferior alveolar injection: a review of two cases. *J Am Dent Assoc* 1994; 125(7):1003–6.
- Malamed SF. Handbook of local anesthesia. 4th ed. St. Louis: Mosby; 1997. p. 51, 132, 193, 193–219, 246–86.
- Meechan JG, Rood JP. Adverse effects of dental local anaesthesia. *Dent Update* 1997; 24(8):315–8.
- Haas DA. Localized complications from local anesthesia. *J Calif Dent Assoc* 1998; 26(9):677–82.
- Stacy GC, Hajjar G. Barbed needle and inexplicable paresthesia and trismus after dental regional anesthesia. *Oral Surg Oral Med Oral Pathol* 1994; 77(6):585–8.
- Flaitz CM, Felefi S. Complications of an unrecognized cheek biting habit following a dental visit. *Pediatr Dent* 2000; 22(6):511–2.
- Faura-Sole M, Sanchez-Garces MA, Berini-Ayres L, Gay-Escoda C. Broken anesthetic injection needles: report of 5 cases. *Quintessence Int* 1999; 30(7):461–5.
- Laskin DM. Diagnosis and treatment of complications associated with local anaesthesia. *Int Dent J* 1984; 34(4):232–7.
- Harn SD, Durham TM. Incidence of lingual nerve trauma and postinjection complications in conventional mandibular block anesthesia. *J Am Dent Assoc* 1990; 121(4):519–23.
- Pogrel MA, Thamby S. Permanent nerve involvement resulting from inferior alveolar nerve blocks. *J Am Dent Assoc* 2000; 131(7):901–7.
- Brodsky CD, Dower JS Jr. Middle ear problems after a Gow-Gates injection. *J Am Dent Assoc* 2001; 132(10):1420–4.
- Penarrocha-Diago M, Sanchis-Bielsa JM. Ophthalmologic complications after intraoral local anesthesia with articaine. *Oral Surg Oral Med Oral Pathol Oral Radiol Endod* 2000; 90(1):21–4.
- Cooley RL, Cottingham AJ Jr. Ocular complications from local anesthetic injections. *Gen Dent* 1979; 27(4):40–3.
- Webber B, Orlansky H, Lipton C, Stevens M. Complications of an intra-arterial injection from an inferior alveolar nerve block. *J Am Dent Assoc* 2001; 132(12):1702–4.
- Cooper JC. Deviation of eye and transient blurring of vision after mandibular nerve anesthesia: report of a case. *J Oral Surg Anesth Hosp Dent Serv* 1962; 20:151–2.
- Rood J. Ocular complication of inferior dental nerve block. A case report. *Br Dent J* 1972; 132(1):23–4.
- De Keyser K, Tassignon MJ. [Case report: acute unilateral loss of visual acuity after a visit to the dentist: an unusual complication after the use of an anesthetic combined with adrenaline.] Article in French. *Rev Belge Med Dent* 2004; 59:30–3.
- Rishiraj B, Epstein JB, Fine D, Nabi S, Wade NK. Permanent vision loss in one eye following administration of local anesthesia for a dental extraction. *Int J Oral Maxillofac Surg* 2005; 34(2):220–3.
- Tommazzoli-Gerosa L, Marchini G, Monaco A. Amaurosis and atrophy of the optic nerve: an unusual complication of mandibular-nerve anesthesia. *Ann Ophthalmol* 1988; 20(5):170–1.
- Leopard PJ. Diplopia following injection of a local anaesthetic. *Dent Pract Dent Rec* 1971; 22(3):92–4.

23. Goldenberg AS. Transient diplopia as a result of block injections. Mandibular and posterior superior alveolar. *N Y State Dent J* 1997; 63(5):29–31.
24. Goldenberg AS. Transient diplopia from a posterior alveolar injection. *J Endod* 1990; 16(11):550–1.
25. Goldenberg AS. Diplopia resulting from a mandibular injection. *J Endod* 1983; 9(6):261–2.
26. Marinho RO. Abducent nerve palsy following dental local analgesia. *Br Dent J* 1995; 179(2):69–70.
27. Koumoura F, Papageorgiou G. Diplopia as a complication of local anesthesia: a case report. *Quintessence Int* 2001; 32(3):232–4.
28. Kronman JH, Kabani S. The neuronal basis for diplopia following local anesthetic injections. *Oral Surg Oral Med Oral Pathol* 1984; 58(5):533–4.
29. Petrelli EA, Steller RE. Medial rectus muscle palsy after dental anesthesia. *Am J Ophthalmol* 1980; 90(3):422–4.
30. Hyams SW. Oculomotor palsy following dental anesthesia. *Arch Ophthalmol* 1976; 94(8):1281–2.
31. Ogunsalu CO. Anaphylactic reaction following administration of lignocaine hydrochloride infiltration. Case report. *Aust Dent J* 1998; 43(3):170–1.
32. Hidding J, Khoury F. [General complications in dental local anesthesia.] Article in German. *Dtsch Zahnartztlz* 1991; 46(12):834–6.
33. Roberts GJ, Rosenbaum NL. A colour atlas of dental analgesia and sedation. England: Wolfe Publishing; 1991. p. 67.
34. Pickering T, Howden R. Gray's anatomy, descriptive and surgical. 15th ed. London: Chancellor Press; 1985. p. 703–9, 805–30.
35. Snell RS. Clinical anatomy for medical students. 3rd ed. Boston: Little Brown & Co.; 1986. p. 825–7.
36. Blaxter P, Britten MJ. Transient amaurosis after mandibular nerve block. *Br Med J* 1967; 1(5541):681.
37. Pretterklieber ML, Skopakoff C, Mayr R. The human maxillary artery reinvestigated: I. Topographical relations in the infratemporal fossa. *Acta Anat (Basel)* 1991; 142(4):281–7.
38. Roda RS, Blanton PL. The anatomy of local anesthesia. *Quintessence Int* 1994; 25(1):27–38.
39. Singh S, Dass R. The central artery of the retina. I. Origin and course. *Br J Ophthalmol* 1960; 44:193–212.
40. Bandres A, Penarocha M, Sanchis JM. [Complicaciones de la anestesia dental.] *Anales Odontostomatol* 1997; 3:87–95.
41. Aldrete JA, Narang R, Sada T, Tan Liem S, Miller GP. **Reverse carotid flow** — a possible explanation for some reactions to local anesthetic. *J Am Dent Assoc* 1977; 94(6):1142–5.