

Clinical Applications of Cone-Beam Computed Tomography in Dental Practice

William C. Scarfe, BDS, FRACDS, MS; Allan G. Farman, BDS, PhD, DSc; Predag Sukovic, BS, MS, PhD

Contact Author

Dr. Scarfe
Email:
wscar01@louisville.edu



ABSTRACT

Cone-beam computed tomography (CBCT) systems have been designed for imaging hard tissues of the maxillofacial region. CBCT is capable of providing sub-millimetre resolution in images of high diagnostic quality, with short scanning times (10–70 seconds) and radiation dosages reportedly up to 15 times lower than those of conventional CT scans. Increasing availability of this technology provides the dental clinician with an imaging modality capable of providing a 3-dimensional representation of the maxillofacial skeleton with minimal distortion. This article provides an overview of currently available maxillofacial CBCT systems and reviews the specific application of various CBCT display modes to clinical dental practice.

MeSH Key Words: radiography, dental/instrumentation; tomography, x-ray computed/instrumentation; tomography, x-ray computed/methods

© J Can Dent Assoc 2006; 72(1):75–80
This article has been peer reviewed.

Radiology is important in the diagnostic assessment of the dental patient and guidelines for the selection of appropriate radiographic procedures for patients suspected of having dental and maxillofacial disease are available.¹ The American Academy of Oral and Maxillofacial Radiology (AAOMR) has established “parameters of care” providing rationales for image selection for diagnosis, treatment planning and follow-up of patients with conditions affecting the oral maxillofacial region, including temporomandibular joint (TMJ) dysfunction (Parameter 2), diseases of the jaws (Parameter 3) and dental implant planning (Parameter 4).² Although combinations of plain x-ray transmission projections and panoramic radiography can be adequate in a number of clinical situations, radiographic assessment may sometimes be facilitated by multiplanar images including computed tomographs.

For most dental practitioners, the use of advanced imaging has been limited because of cost, availability and radiation dose considerations; however, the introduction of cone-beam

computed tomography (CBCT) for the maxillofacial region provides opportunities for dental practitioners to request multiplanar imaging. Most dental practitioners are familiar with the thin-slice images produced in the axial plane by conventional helical fan-beam CT. CBCT allows the creation in “real time” of images not only in the axial plane but also 2-dimensional (2D) images in the coronal, sagittal and even oblique or curved image planes — a process referred to as multiplanar reformation (MPR). In addition, CBCT data are amenable to reformation in a volume, rather than a slice, providing 3-dimensional (3D) information. The purpose of this article is to provide an overview of the unique image display capabilities of maxillofacial CBCT systems and to illustrate specific applications in clinical practice.

Types of CT Scanners

Computed tomography can be divided into 2 categories based on acquisition x-ray beam geometry; namely: fan beam and cone beam (Fig. 1).

In fan-beam scanners, an x-ray source and solid-state detector are mounted on a rotating gantry (Fig. 1a). Data are acquired using a narrow fan-shaped x-ray beam transmitted through the patient. The patient is imaged slice-by-slice, usually in the axial plane, and interpretation of the images is achieved by stacking the slices to obtain multiple 2D representations. The linear array of detector elements used in conventional helical fan-beam CT scanners is actually a multi-detector array. This configuration allows multi-detector CT (MDCT) scanners to acquire up to 64 slices simultaneously, considerably reducing the scanning time compared with single-slice systems and allowing generation of 3D images at substantially lower doses of radiation than single detector fan-beam CT arrays.³

Cone-Beam CT Technology

CBCT scanners are based on volumetric tomography, using a 2D extended digital array providing an area detector. This is combined with a 3D x-ray beam (Fig. 1b). The cone-beam technique involves a single 360° scan in which the x-ray source and a reciprocating area detector synchronously move around the patient's head, which is stabilized with a head holder. At certain degree intervals, single projection images, known as "basis" images, are acquired. These are similar to lateral cephalometric radiographic images, each slightly offset from one another. This series of basis projection images is referred to as the projection data. Software programs incorporating sophisticated algorithms including back-filtered projection are applied to these image data to generate a 3D volumetric data set, which can be used to provide primary reconstruction images in 3 orthogonal planes (axial, sagittal and coronal).

Although the CBCT principle has been in use for almost 2 decades, only recently — with the development of inexpensive x-ray tubes, high-quality detector systems and powerful personal computers — have affordable systems become commercially available. Beginning with the NewTom QR DVT 9000 (Quantitative Radiology s.r.l., Verona, Italy)⁴ introduced in April 2001, other systems include CB MercuRay (Hitachi Medical Corp., Kashiwa-shi, Chiba-ken, Japan), 3D Accuitomo – XYZ Slice View Tomograph (J. Morita Mfg Corp., Kyoto, Japan) and i-CAT (Xoran Technologies, Ann Arbor, Mich., and Imaging Sciences International, Hatfield, PA).

These units can be categorized according to their x-ray detection system.^{5,6} Most CBCT units for maxillofacial applications use an image intensifier tube (IIT)–charge-coupled device. Recently a system employing a flat panel imager (FPI) was released (i-CAT).^{7,8} The FPI consists of a cesium iodide scintillator applied to a thin film transistor made of amorphous silicon. Images produced with an IIT generally result in more noise than images from an FPI and also need to be preprocessed to reduce geometric distortions inherent in the detector configuration.^{5,6}

Advantages of CBCT

CBCT is well suited for imaging the craniofacial area. It provides clear images of highly contrasted structures and is extremely useful for evaluating bone.^{8,9} Although limitations currently exist in the use of this technology for soft-tissue imaging, efforts are being directed toward the development of techniques and software algorithms to improve signal-to-noise ratio and increase contrast.

The use of CBCT technology in clinical practice provides a number of potential advantages for maxillofacial imaging compared with conventional CT:

- **X-ray beam limitation:** Reducing the size of the irradiated area by collimation of the primary x-ray beam to the area of interest minimizes the radiation dose. Most CBCT units can be adjusted to scan small regions for specific diagnostic tasks. Others are capable of scanning the entire craniofacial complex when necessary.
- **Image accuracy:** The volumetric data set comprises a 3D block of smaller cuboid structures, known as voxels, each representing a specific degree of x-ray absorption. The size of these voxels determines the resolution of the image. In conventional CT, the voxels are anisotropic — rectangular cubes where the longest dimension of the voxel is the axial slice thickness and is determined by slice pitch, a function of gantry motion. Although CT voxel surfaces can be as small as 0.625 mm square, their depth is usually in the order of 1–2 mm. All CBCT units provide voxel resolutions that are isotropic — equal in all 3 dimensions. This produces sub-millimetre resolution (often exceeding the highest grade multi-slice CT) ranging from 0.4 mm to as low as 0.125 mm (Accuitomo).
- **Rapid scan time:** Because CBCT acquires all basis images in a single rotation, scan time is rapid (10–70 seconds) and comparable with that of medical spiral MDCT systems. Although faster scanning time usually means fewer basis images from which to reconstruct the volumetric data set, motion artifacts due to subject movement are reduced.
- **Dose reduction:** Published reports indicate that the effective dose of radiation (average range 36.9–50.3 microsievert [μSv])^{10–14} is significantly reduced by up to 98% compared with "conventional" fan-beam CT systems (average range for mandible 1,320–3,324 μSv ; average range for maxilla 1,031–1,420 μSv).^{10,11,15–17} This reduces the effective patient dose to approximately that of a film-based periapical survey of the dentition (13–100 μSv)^{18–20} or 4–15 times that of a single panoramic radiograph (2.9–11 μSv).^{14,17–20}
- **Display modes unique to maxillofacial imaging:** Access and interaction with medical CT data are not possible as workstations are required. Although such data can be "converted" and imported into proprietary programs for use on personal computers (e.g., Sim/Plant, Materialise, Leuven, Belgium), this process is expensive and requires an

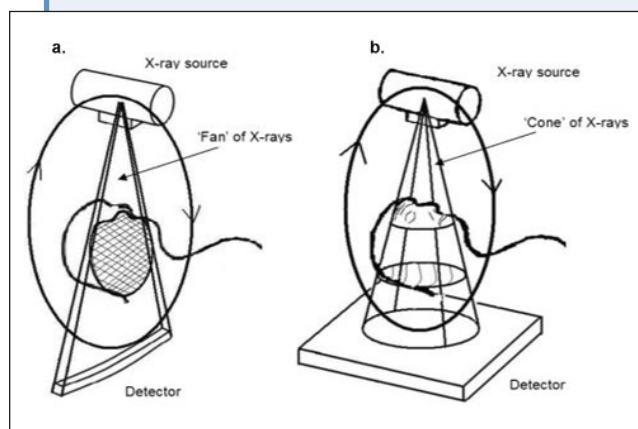


Figure 1: X-ray beam projection scheme comparing a single detector array fan-beam CT (a) and cone-beam CT (b) geometry.

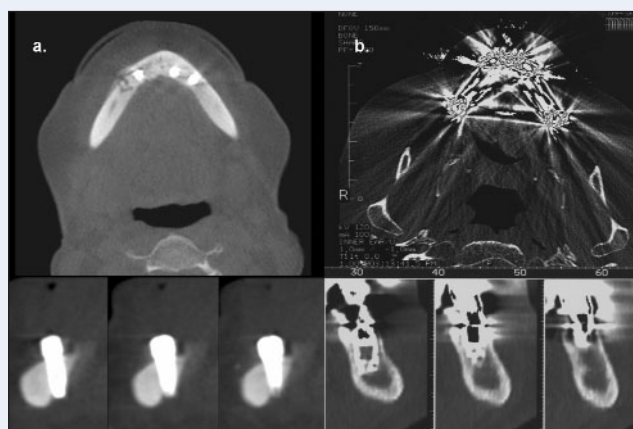


Figure 2: Relative image artifact reduction with CBCT (a) axial (top) and cross-sectional images (lower) of the mandibular arch with implants compared with conventional CT (b) axial (top) and cross-sectional (lower) images of maxillary arch with implants.

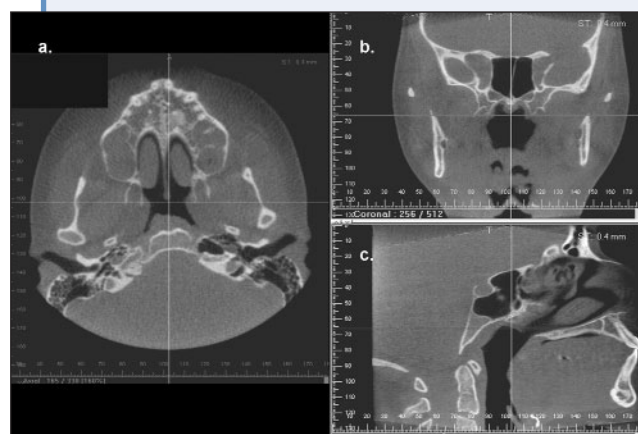


Figure 3: Representative standard CBCT monitor display (i-CAT) showing axial (a), coronal (b) and sagittal (c) thin-section slices.

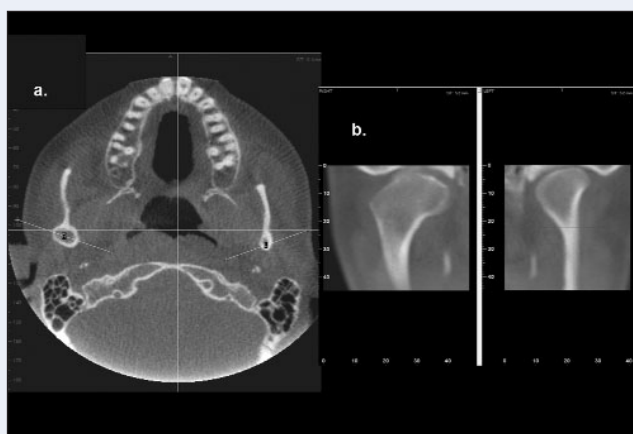


Figure 4: Bilateral linear oblique multiplanar reformation through lateral and medial poles of the mandibular condyle on the axial image (a) providing corrected coronal, limited field-of-view, thin-slice temporomandibular views (b) demonstrating right condylar hyperplasia.

intermediary stage that can extend the diagnostic phase. Reconstruction of CBCT data is performed natively by a personal computer. In addition, software can be made available to the user, not just the radiologist, either via direct purchase or innovative “per use” licence from various vendors (e.g., Imaging Sciences International). This provides the clinician with the opportunity to use chair-side image display, real-time analysis and MPR modes that are task specific. Because the CBCT volumetric data set is isotropic, the entire volume can be reoriented so that the patient’s anatomic features are realigned. In addition, cursor-driven measurement algorithms allow the clinician to do real-time dimensional assessment.

- **Reduced image artifact:** With manufacturers’ artifact suppression algorithms and increasing number of

projections, our clinical experience has shown that CBCT images can result in a low level of metal artifact, particularly in secondary reconstructions designed for viewing the teeth and jaws (Fig. 2).¹⁰

Application of CBCT Imaging to Clinical Dental Practice

Unlike conventional CT scanners, which are large and expensive to purchase and maintain, CBCT is suited for use in clinical dental practice where cost and dose considerations are important, space is often at a premium and scanning requirements are limited to the head.

All CBCT units initially provide correlated axial, coronal and sagittal perpendicular MPR images (Fig. 3). Basic enhancements include zoom or magnification and visual adjustments to narrow the range of displayed grey-scales

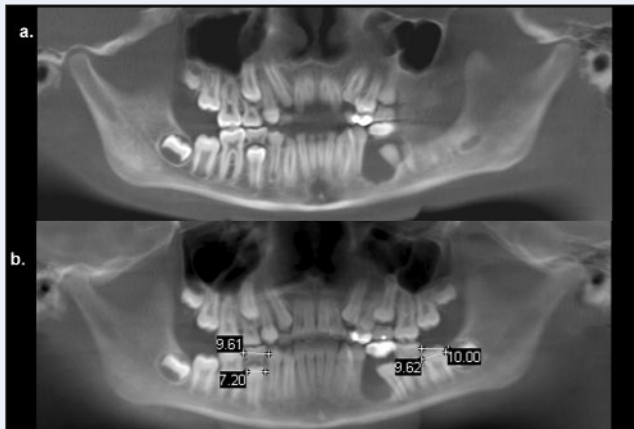


Figure 5: Narrow (5.3 mm) (a) and wide (25.6 mm) (b) slice simulated panoramic images providing anatomically accurate measurements.

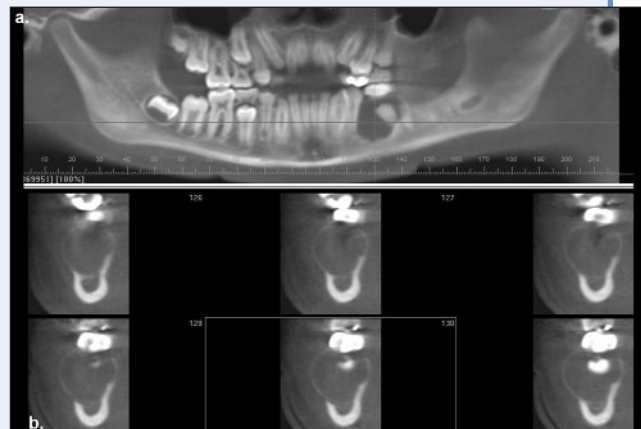


Figure 6: Reformatted panoramic image (a) providing reference for multiple narrow trans-axial thin cross-sectional slices (b) of radiolucent bony pathology in the left mandible, demonstrating bucco-lingual expansion and location of the inferior alveolar canal.

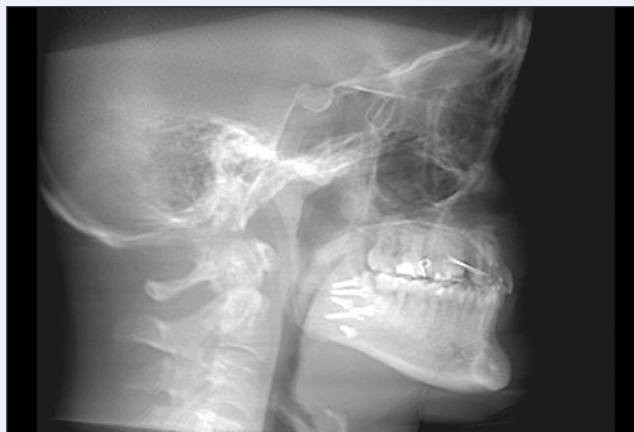

Figure 7: “Ray sum” simulated lateral cephalometric projection.

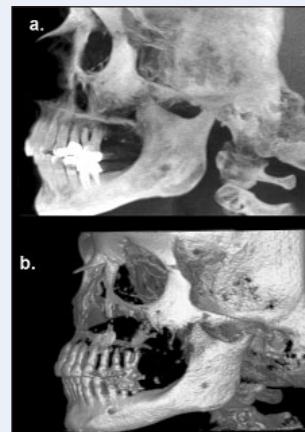


Figure 8: Right lateral maximum intensity projection (a) and shaded surface rendering of patient. (Courtesy: Arun Singh, Imaging Sciences International)

(window) and contrast level within this window, the capability to add annotation and cursor-driven measurement. The value of CBCT imaging in implant planning,^{21–23} surgical assessment of pathology, TMJ assessment^{24–26} and pre- and postoperative assessment of craniofacial fractures has been reported.^{8,9,12} In orthodontics, CBCT imaging is useful in the assessment of growth and development^{8,27–29} and such imaging is becoming commonplace in certain regions, especially on the west coast of the United States.

Perhaps the greatest practical advantage of CBCT in maxillofacial imaging is the ability it provides to interact with the data and generate images replicating those commonly used in clinical practice. All proprietary software is capable of various real-time advanced image display techniques, easily derived from the volumetric data set. These techniques and their specific clinical applications include:

- **Oblique planar reformation:** This technique creates nonaxial 2D images by transecting a set or “stack” of axial images. This mode is particularly useful for evaluating specific structures (e.g., TMJ, impacted third molars) as certain features may not be readily apparent on perpendicular MPR images (Fig. 4).
- **Curved planar reformation:** This is a type of MPR accomplished by aligning the long axis of the imaging plane with a specific anatomic structure. This mode is useful in displaying the dental arch, providing familiar panorama-like thin-slice images (Fig. 5a). Images are undistorted so that measurements and angulations made from them have minimal error.
- **Serial transplanar reformation:** This technique produces a series of stacked sequential cross-sectional images

orthogonal to the oblique or curved planar reformation. Images are usually thin slices (e.g., 1 mm thick) of known separation (e.g., 1 mm apart). Resultant images are useful in the assessment of specific morphologic features such as alveolar bone height and width for implant site assessment, the inferior alveolar canal in relation to impacted mandibular molars, condylar surface and shape in the symptomatic TMJ or evaluation of pathological conditions affecting the jaws (Fig. 6).

• **Multiplanar volume reformations:** Any multiplanar image can be “thickened” by increasing the number of adjacent voxels included in the slice. This creates an image that represents a specific volume of the patient. The simplest technique is adding the absorption values of adjacent voxels, to produce a “ray sum” image. This mode can be used to generate simulated panoramic images by increasing the slice thickness of curved planar reformatted images along the dental arch to 25–30 mm, comparable to the in-focus image layer of panoramic radiographs (Fig. 5b). Alternatively, plain projection images such as lateral cephalometric images (Fig. 7) can be created from full thickness (130–150 mm) perpendicular MPR images. In this case, such images can be exported and analyzed using third-party proprietary cephalometric software. Unlike conventional radiographs, these ray sum images are without magnification and are undistorted.

Another thickening technique is maximum intensity projection (MIP). MIP images are achieved by displaying only the highest voxel value within a particular thickness. This mode produces a “pseudo” 3D structure and is particularly useful in representing the surface morphology of the maxillofacial region (Fig. 8a). More complicated shaded surface displays and volume rendering algorithms can be applied to the entire thickness of the volumetric data set to provide 3D reconstruction and presentation of data that can be interactively enhanced (Fig. 8b).

Discussion

There is little doubt that cone-beam technology will become an important tool in dental and maxillofacial imaging over the next decade or 2. Clinical applications of CBCT are rapidly being applied to dental practice. However, although CBCT allows images to be displayed in a variety of formats, the interpretation of the volumetric data set, particularly when it comprises large areas, involves more than the generation of 3D representations or application of clinical protocols providing specific images. Interpretation demands an understanding of the spatial relations of bony anatomic elements and extended pathologic knowledge of various maxillofacial structures. Currently, any dental practitioner can purchase and operate a CBCT unit. There is mounting concern among oral and maxillofacial radiologists, based on issues of quality and patient safety, that interpretation of extended field of view diagnostic

imaging studies using CBCT should not be performed by dentists with inadequate training and experience. The AAOMR has indicated that, to use CT in implant imaging, the interpreting practitioner should either be a board-certified oral and maxillofacial radiologist or a dentist with adequate training and experience.² Perhaps, as has occurred in medical imaging where the use and costs of imaging have increased at double-digit rates, third-party payers and federal policymakers will also become involved in setting standards for providers who bill the government for obtaining and interpreting diagnostic images.³⁰ Non-radiologist dentists should not be excluded from performing CBCT imaging provided they have appropriate and documented training and experience. Given that a single CBCT scan uses ionizing radiation at levels exceeding any current dental imaging protocol series, it is timely to recommend the development of rigorous training standards in maxillofacial CBCT imaging in the interests of our patients who deserve to have imaging performed by competent clinicians.

Conclusions

The development and rapid commercialization of CBCT technology dedicated to imaging the maxillofacial region will undoubtedly increase dental practitioner access to 3D radiographic assessments in clinical dental practice. CBCT imaging provides clinicians with sub-millimetre spatial resolution images of high diagnostic quality with relatively short scanning times (10–70 seconds) and a reported radiation dose equivalent to that needed for 4 to 15 panoramic radiographs. ♦

THE AUTHORS



Dr. Scarfe is an associate professor in the division of radiology and imaging sciences, department of surgical/hospital dentistry, University of Louisville School of Dentistry, Louisville, Kentucky.



Dr. Farman is a professor in the division of radiology and imaging sciences, department of surgical/hospital dentistry, University of Louisville School of Dentistry, Louisville, Kentucky.



Dr. Sukovic is co-founder, president and CEO of Xoran Technologies, Ann Arbor, Michigan.

Correspondence to: Dr. William C. Scarfe, Department of Surgical/Hospital Dentistry, University of Louisville School of Dentistry, 501 South Preston St., Louisville KY 40292.

Dr. Farman was a consultant on the National Institutes of Health Small Business Funding Opportunity grants awarded to Xoran Corporation.

References

1. American Dental Association and U.S. Department of Health and Human Services. The selection of patients for dental radiographic examinations. Chicago: American Dental Association, 2004.

2. White SC, Heslop EW, Hollender LG, Mosier KM, Ruprecht A, Shroud MK; American Academy of Oral and Maxillofacial Radiology, ad hoc Committee on Parameters of Care. Parameters of radiologic care: an official report of the American Academy of Oral and Maxillofacial Radiology. *Oral Surg Oral Med Oral Pathol Oral Radiol Endod* 2001; 91(5):498–511.
3. Hu H, He HD, Foley WD, Fox SH. Four multidetector-row helical CT: image quality and volume coverage speed. *Radiology* 2000; 215(1):55–62.
4. Mozzo P, Procacci C, Tacconi A, Martini PT, Andreis IA. A new volumetric CT machine for dental imaging based on the cone-beam technique: preliminary results. *Eur Radiol* 1998; 8(9):1558–64.
5. Baba R, Konno Y, Ueda K, Ikeda S. Comparison of flat-panel detector and image-intensifier detector for cone-beam CT. *Comput Med Imaging Graph* 2002; 26(3):153–8.
6. Baba R, Ueda K, Okabe M. Using a flat-panel detector in high resolution cone beam CT for dental imaging. *Dentomaxillofac Radiol* 2004; 33(5):285–90.
7. Sukovic P, Brooks S, Perez L, Clinthorne NH. DentoCAT – a novel design of a cone beam CT scanner for dentomaxillofacial imaging: introduction and preliminary results. In: Lemke HU, Vannier MW, Inamura K, Farman AG, Doi K, editors. Computer assisted radiology and surgery. Amsterdam: Elsevier Science; 2001. p. 659–64.
8. Sukovic P. Cone beam computed tomography in craniofacial imaging. *Orthod Craniofac Res* 2003; 6(Suppl 1):31–6.
9. Ziegler CM, Woertche R, Brief J, Hassfeld S. Clinical indications for digital volume tomography in oral and maxillofacial surgery. *Dentomaxillofac Radiol* 2002; 31(2):126–30.
10. Cohnen M, Kemper J, Mobes O, Pawelzik J, Modder U. Radiation dose in dental radiology. *Eur Radiol* 2002; 12(3):634–7.
11. Schulze D, Heiland M, Thurmann H, Adam G. Radiation exposure during midfacial imaging using 4- and 16-slice computed tomography, cone beam computed tomography systems and conventional radiography. *Dentomaxillofac Radiol* 2004; 33(2):83–6.
12. Heiland M, Schulze D, Rother U, Schmelzle R. Postoperative imaging of zygomaticomaxillary complex fractures using digital volume tomography. *J Oral Maxillofac Surg* 2004; 62(11):1387–91.
13. Mah JK, Danforth RA, Bumann A, Hatcher D. Radiation absorbed in maxillofacial imaging with a new dental computed tomography device. *Oral Surg Oral Med Oral Pathol Oral Radiol Endod* 2003; 96(4):508–13.
14. Ludlow JB, Davies-Ludlow LE, Brooks SL. Dosimetry of two extraoral direct digital imaging devices: NewTom cone beam CT and Orthophos Plus DS panoramic unit. *Dentomaxillofac Radiol* 2003; 32(4):229–34.
15. Scaf G, Lurie AG, Mosier KM, Kantor ML, Ramsby GR, Freedman ML. Dosimetry and cost of imaging osseointegrated implants with film-based and computed tomography. *Oral Surg Oral Med Oral Pathol Oral Radiol Endod* 1997; 83(1):41–8.
16. Dula K, Mini R, van der Stelt PF, Lambrecht JT, Schneeberger P, Buser D. Hypothetical mortality risk associated with spiral computed tomography of the maxilla and mandible. *Eur J Oral Sci* 1996; 104(5-6):503–10.
17. Ngan DC, Kharbanda OP, Geenty JP, Darendeliler MA. Comparison of radiation levels from computed tomography and conventional dental radiographs. *Aust Orthod J* 2003; 19(2):67–75.
18. White SC. 1992 assessment of radiation risk from dental radiography. *Dentomaxillofac Radiol* 1992; 21(3):118–26.
19. Danforth RA, Clark DE. Effective dose from radiation absorbed during a panoramic examination with a new generation machine. *Oral Surg Oral Med Oral Pathol Oral Radiol Endod* 2000; 89(2):236–43.
20. Gibbs SJ. Effective dose equivalent and effective dose: comparison for common projections in oral and maxillofacial radiology. *Oral Surg Oral Med Oral Pathol Oral Radiol Endod* 2000; 90(4):538–45.
21. Sato S, Arai Y, Shinoda K, Ito K. Clinical application of a new cone-beam computerized tomography system to assess multiple two-dimensional images for the preoperative treatment planning of maxillary implants: case reports. *Quintessence Int* 2004; 35(7):525–8.
22. Kobayashi K, Shimoda S, Nakagawa Y, Yamamoto A. Accuracy in measurement of distance using limited cone-beam computerized tomography. *Int J Oral Maxillofac Implants* 2004; 19(2):228–31.
23. Hatcher DC, Dial C, Mayorga C. Cone beam CT for pre-surgical assessment of implant sites. *J Calif Dent Assoc* 2003; 31(11):825–33.
24. Honda K, Matumoto K, Kashima M, Takano Y, Kawashima S, Arai Y. Single air contrast arthrography for temporomandibular joint disorder using limited cone beam computed tomography for dental use. *Dentomaxillofac Radiol* 2004; 33(4):271–3.
25. Tsiklakis K, Syriopoulos K, Stamatakis HC. Radiographic examination of the temporomandibular joint using cone beam computed tomography. *Dentomaxillofac Radiol* 2004; 33(4):196–201.
26. Honda K, Arai Y, Kashima M, Takano Y, Sawada K, Ejima K, and other. Evaluation of the usefulness of the limited cone-beam CT (3DX) in the assessment of the thickness of the roof of the glenoid fossa of the temporomandibular joint. *Dentomaxillofac Radiol* 2004; 33(6):391–5.
27. Aboudara CA, Hatcher D, Nielsen IL, Miller A. A three-dimensional evaluation of the upper airway in adolescents. *Orthod Craniofac Res* 2003; 6(Suppl 1):173–5.
28. Baumrind S, Carlson S, Beers A, Curry S, Norris K, Boyd RL. Using three-dimensional imaging to assess treatment outcomes in orthodontics: a progress report from the University of the Pacific. *Orthod Craniofac Res* 2003; 6(Suppl 1):132–42.
29. Maki K, Inou N, Takanishi A, Miller AJ. Computer-assisted simulations in orthodontic diagnosis and the application of a new cone beam X-ray computed tomography. *Orthod Craniofac Res* 2003; 6(Suppl 1):95–101.
30. Miller ME. MedPAC recommendations on imaging services. March 17, 2005 Available from: URL: http://www.medpac.gov/publications/congressional_testimony/031705_TestimonyImaging-Hou.pdf (accessed December 2005).