

Blistering Mucocutaneous Diseases of the Oral Mucosa — A Review: Part 2. Pemphigus Vulgaris

Mark R. Darling, MSc (Dent), MSc (Med), MChD (Oral Path);
Tom Daley, DDS, MSc, FRCD(C)

Contact Author

Dr. Darling
Email:
mark.darling@schulich.uwo.ca



ABSTRACT

Oral mucous membranes may be affected by a variety of blistering mucocutaneous diseases. In this paper, we review the clinical manifestations, typical microscopic and immunofluorescence features, pathogenesis, biological behaviour and treatment of pemphigus vulgaris. Although pemphigus vulgaris is not a common disease of the oral cavity, its potential to cause severe or life-threatening disease is such that the general dentist must have an understanding of its pathophysiology, clinical presentation and management.

MeSH Key Words: mouth diseases; pemphigus/drug therapy; pemphigus/etiology

© J Can Dent Assoc 2006; 72(1):63–6
This article has been peer reviewed.

The most common blistering conditions of the oral and perioral soft tissues were briefly reviewed in part 1 of this paper (viral infections, immunopathogenic mucocutaneous blistering diseases, erythema multiforme and other contact or systemic allergic reactions).^{1–4} This paper (part 2) focuses on the second most common chronic immunopathogenic disease to cause chronic oral blistering: pemphigus vulgaris.

Pemphigus

Pemphigus is a group of diseases associated with intraepithelial blistering.⁵ Pemphigus vulgaris (variant: pemphigus vegetans) and pemphigus foliaceus (variant: pemphigus erythematous) are the classically recognized clinical variants, but others are now known, such as IgA pemphigus, paraneoplastic pemphigus and herpetiform pemphigus. Drug-induced pemphigus vulgaris-like lesions are known to be caused by D-penicillamine, but similar lesions have also been reported for

captopril, phenacetin, furosemide, penicillin, tiopronin and sulfones such as dapsone. Oral lesions are commonly seen with pemphigus vulgaris and paraneoplastic pemphigus.⁶

Normal Desmosomes

Adjacent epithelial cells share a number of connections including tight junctions, gap junctions and desmosomes. Desmosomes are specialized structures that can be thought of as spot welds between cells. The intermediate keratin filaments of each cell are linked to focal plaque-like electron dense thickenings on the inside of the cell membrane containing proteins called plakoglobins and desmoplakins. Some of these proteins are linked to glycoproteins, desmogleins and desmocollins, which extend through the cell plasma membrane to a widened zone between the 2 cells called the desmoglea. In this space, the desmogleins and desmocollins join by homophilic binding to link the 2 cell membranes together (Fig. 1). The expression of desmogleins varies between

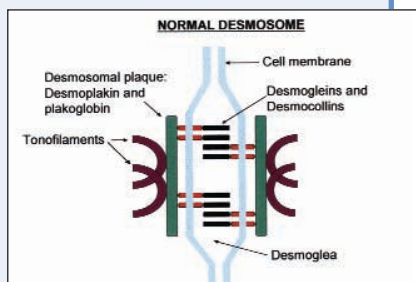


Figure 1: Schematic of a normal desmosome between 2 adjacent epithelial cells.

oral epithelium and skin: oral epithelium contains mostly desmoglein 3, whereas skin contains both desmoglein 3 and desmoglein 1.

Pemphigus Vulgaris

Pemphigus vulgaris is a blistering disease of skin and sometimes of the mucous membranes. It affects both men and women over a wide age range and is extremely variable in severity. Two immune variants are recognized: the mucous membrane predominant type (anti-desmoglein 3 only) and the mucocutaneous type (anti-desmoglein 1 and 3). In the mucocutaneous type, oral ulcerative lesions are often seen before the disease inevitably affects the skin. The condition is seen in a greater proportion in certain ethnic groups, such as those of Mediterranean origin and Ashkenazi Jews, suggesting a genetic predisposition. The disease is less common than mucous membrane pemphigoid (MMP), occurring in about 0.1–0.5 patients per 100,000 population a year.⁷

Patients complain of painful, persistent ulcers and sloughing (Fig. 2a), which may affect any part of the oral cavity but is commonly seen first in the buccal mucosa, palatal mucosa and lips⁷ (Fig. 2b). Occasionally blisters are seen, but these usually rupture quickly and are often unnoticed. The Nikolsky test is positive. The ulcerations may affect other mucous membranes, including the conjunctiva, nasal mucosa, pharynx, larynx, esophagus and genital mucosa, as well as the skin where intact blisters are more commonly seen.⁸

Microscopic Appearance

Biopsy of a blister shows an intraepithelial vesicle containing floating, rounded keratinocytes (Tzanck cells) that have become detached from surrounding cells (acantholysis). The basal layer cells are still firmly attached to the connective tissue, although they may show separation along their lateral plasma membranes. The roof of the blister is tenuous and of variable thickness, or may be absent. Long rete pegs lined by a single layer of basal cells are often present, and there is a mild to moderate chronic

inflammatory infiltrate in the adjacent connective tissue² (Figs. 2c and 2d).

Immunofluorescence Features

Direct immunofluorescence shows binding of IgG and C3 between epithelial cells, forming a “chicken wire” or “fish net” appearance. There is no staining in the basement membrane zone (BMZ). Indirect immunofluorescence is positive in the same pattern in almost all cases indicating the presence of circulating autoantibodies.²

Pathogenesis

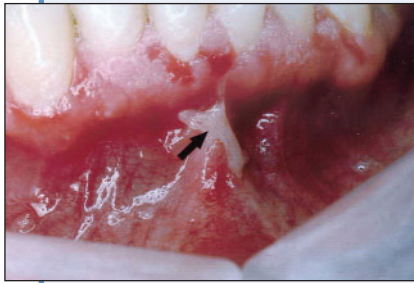
In mucous membrane pemphigus vulgaris, IgG autoantibodies against desmoglein 3 are produced and are hypothesized to hinder sterically the homophilic extracellular linkage of adjacent cells in the desmoglea of the desmosome⁶ (Fig. 2e). Consequently, cells do not adhere to each other and the epithelium falls apart. Hemidesmosomes at the basement membrane are not affected because they do not contain desmoglein 3, so basal cells remain attached to the basement membrane. In mucocutaneous pemphigus vulgaris, IgG autoantibodies to both desmoglein 1 and 3 are produced, causing lesions on both mucous membranes and skin.^{5–7} Circulating autoantibodies against desmoglein 3 or 1, or both, are usually found and the severity of disease is roughly proportional to the serum concentration. This fact allows the disease to be monitored by assessing changes in autoantibody serum concentration.

Clinical Course

Severe cases of pemphigus vulgaris affecting skin and mucous membranes are fatal if not treated. Localized lesions in the oral cavity are not life threatening but may be associated with considerable morbidity if untreated, and patients must be carefully monitored for spread of the condition to other mucous membranes and skin. Pemphigus vulgaris typically has a rapid onset, but progression is highly variable. Remission is common after an unpredictable time period, and apparent cure of the disease may be seen. About 75% of patients undergo remission after 10 years of therapy. Induction of remission depends on the initial severity of disease and response to therapy.⁷

Treatment

Corticosteroids are the primary drugs used in the treatment of pemphigus vulgaris.^{7–9} Mild localized lesions of oral mucous membrane pemphigus in patients with low titres of circulating autoantibodies may be controlled, at least temporarily, with topical corticosteroid rinses or creams, including agents such as clobetasol propionate.⁷ Intralesional triamcinolone may be used for resistant local lesions. However, patients with multifocal disease or severe localized disease require systemic corticosteroids, typically starting at 60–80 mg prednisone a day. If no con-



2a: This female patient with oral pemphigus vulgaris has typical ragged epithelial lesions of the gingiva. The arrow points to the superficial epithelial layers that have sloughed off. Blisters are rarely seen intraorally.

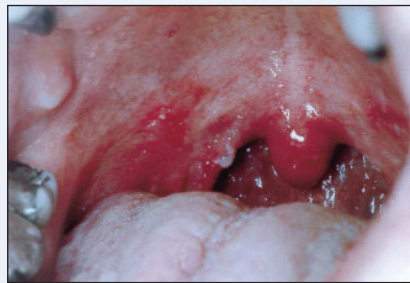

Figure 2b: Sloughing lesions of the soft palate are commonly seen, as in this female patient with pemphigus vulgaris.

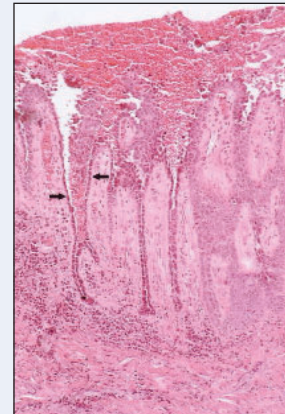


Figure 2c: Microscopically, a blister occurs within the epithelium as individual cells become detached and the epithelium separates. This lesion has lost the roof of the blister, which now contains hemorrhage, but the clinging basal layer is still present (arrow). (Hematoxylin and eosin staining, magnification $\times 100$)

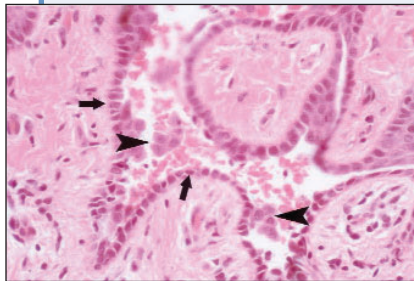


Figure 2d: Higher magnification shows the clinging basal layer (arrows) as well as detached (Tzank) cells (curved arrows) floating in the blister space. (Hematoxylin and eosin staining, magnification $\times 500$)

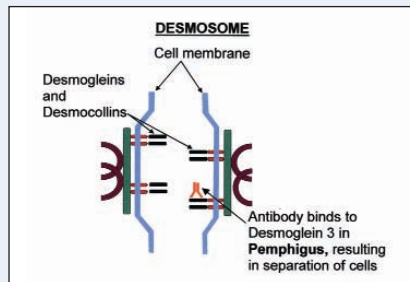


Figure 2e: Schematic diagram of the immunopathogenesis of oral pemphigus vulgaris.

trol is obtained in the first week, the dose is increased to 120 mg a day for a week, then up to 240 mg a day if necessary to prevent new blisters. Once control is achieved, the dose is reduced by half, to 120 mg a day for a week, then to 80 mg a day for a week until a level of 40 mg a day is reached. The dose is then decreased every 4 months.⁹ In most cases, low maintenance doses, usually every other day, are needed for years. High-dose pulses of corticosteroids may be delivered for relapsing or resistant cases, either orally or intravenously.⁹ Patients often become cushingoid, and deaths are now more often attributed to drug side effects than to the disease itself.⁸

Adjunctive therapy for resistant patients to reduce corticosteroid side effects includes azathioprine or cyclophosphamide or both. The dose varies depending on patient response. Other therapeutic agents now being tried include deflazacort,⁸ mycophenolate mofetyl, gold and human intravenous immunoglobulin (IVIG).^{7,9}

Paraneoplastic Pemphigus

Paraneoplastic pemphigus is a rare blistering and ulcerating disease of sudden onset of the skin and mucous membranes and always affects the oral mucosa. Oral lesions are very painful and consist of widespread, irregular shallow ulcers at multiple oral sites. Characteristically, they extend on the lip vermilion causing hemorrhagic, crusting blisters and erosions (Fig. 3a). The conjunctiva are typically severely affected with inflammation, ulceration and pain (Fig. 3b). Genital mucosa and even respiratory mucosa may be involved. Skin lesions, which may appear at any site including the palms and soles, may be blistering but often present as erythematous papular lesions resembling lichen planus.¹⁰ This condition is seen in elderly patients who usually have a malignancy, typically a lymphoma or chronic lymphocytic leukemia. Occasionally it precedes the discovery of the malignancy.

Autoantibodies are always produced against multiple antigens in the BMZ, desmoglea and intraepithelial

plaques, resulting in a severe disease with clinical, microscopic and immunofluorescence features of both pemphigus vulgaris and MMP superimposed on a lichenoid base.¹⁰ A variety of antigens have been described, including autoantibodies to desmoplakins, envoplakin, periplakin and bullous pemphigoid antigen 1 (BP230).

Paraneoplastic pemphigus indicates a poor prognosis for the patient, as its morbidity and mortality rates are high. It is treated by systemic corticosteroids, often combined with other immunosuppressive agents such as azathioprine, cyclophosphamide and methotrexate.¹⁰

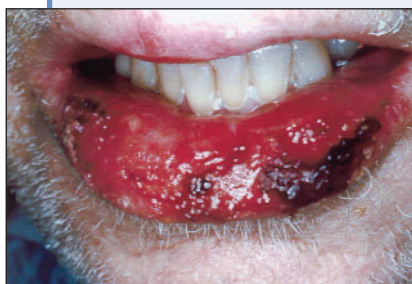

Figure 3a: Oral lesions of paraneoplastic pemphigus are ulcerative, widespread and painful. The lips typically exhibit bloody crusting ulcers as seen in this elderly male patient.

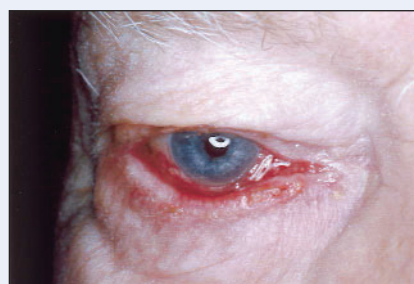

Figure 3b: Moderate to severe ocular lesions are typically seen (same patient as in Fig. 3a).

Desquamative Gingivitis

Desquamative gingivitis is a non-specific clinical term that describes persistent, extensive, chronic inflammation of the attached gingival and sometimes adjacent alveolar mucosa.² MMP (part 1)¹ and pemphigus vulgaris (Fig. 2a) are 2 of the possible entities that may be included under this heading. Others include gingival involvement by such entities as lichen planus and lupus erythematosus.

Conclusion

Although MMP and pemphigus vulgaris are comparatively uncommon conditions, the dental practitioner should have a high level of awareness of these diseases to recognize and manage them, or refer patients when appropriate. Whether and at what stage to refer will depend on the practitioner's own level of comfort and experience in dealing with these patients, whether the disease is recurrent or refractory, the extent of disease (e.g., disease which has spread beyond the confines of the oral cavity is probably best referred) and the availability of a specialist. ♦

References

1. Darling M, Daly T. Blistering mucocutaneous diseases of the oral mucosa — a review: Part 1. Mucous membrane pemphigoid. *J Can Dent Assoc* 2005; 71(11):851-4.
2. Sapp JP, Eversole LR, Wysocki GP. Contemporary oral and maxillofacial pathology. 2nd ed. St. Louis: Mosby; 2004. p. 209-13, 219-21, 262-74.
3. Edwards PC, Kelsch R. Oral lichen planus: clinical presentation and management. *J Can Dent Assoc* 2002; 68(8):494-9.
4. Elder D, Elenitsas R, Jaworsky C, Johnson B Jr. Lever's histopathology of the skin. 8th ed. Philadelphia: Lippincott-Raven; 1997. p. 209-52.
5. Challacombe SJ, Setterfield J, Shirlaw P, Harman K, Scully C, Black MM. Immunodiagnosis of pemphigus and mucous membrane pemphigoid. *Acta Odontol Scand* 2001; 59(4):226-34.
6. Hashimoto T. Recent advances in the study of the pathophysiology of pemphigus. *Arch Dermatol Res* 2003; 295:S2-11. Epub 2003 Jan 9.
7. Scully C, Challacombe SJ. Pemphigus vulgaris: update on etiopathogenesis, oral manifestations, and management. *Crit Rev Oral Biol Med* 2002; 13(5):397-408.
8. Mignogna MD, Lo Muzio LL, Mignogna RE, Carbone R, Ruoppo E, Bucci E. Oral pemphigus: long term behaviour and clinical response to treatment with deflazacort in sixteen cases. *J Oral Pathol Med* 2000; 29(4):145-52.
9. Toth GC, Jonkman MF. Therapy of pemphigus. *Clin Dermatol* 2001; 19(6):761-7.
10. Allen CM, Camisa C. Paraneoplastic pemphigus: a review of the literature. *Oral Dis* 2000; 6(4):208-14.

THE AUTHORS



Dr. Darling is an assistant professor in the department of pathology at the University of Western Ontario, London, Ontario.



Dr. Daley is a professor in the department of pathology at the University of Western Ontario, London, Ontario.

Correspondence to: Dr. Mark R. Darling, Division of Oral Pathology, Department of Pathology, University of Western Ontario, London, ON N6A 5C1.

The authors have no declared financial interests.