

# The Importance of Recognizing Pathology Associated with Retained Third Molars

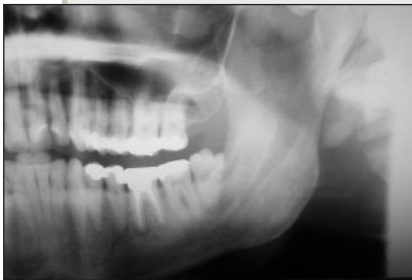Albert J. Haddad, DMD, MSc, FRCD(C), FADSA; Reena M. Talwar, DDS, PhD;  
Cameron M.L. Clokie, DDS, PhD, FRCD(C), FICD(C), FADI, Dip ABOMS

*“Clinical Showcase” is a series of pictorial essays that focus on the technical art of clinical dentistry. The section features step-by-step case demonstrations of clinical problems encountered in dental practice. If you would like to propose a case or recommend a clinician who could contribute to this section, contact editor-in-chief Dr. John O’Keefe at [jokeefe@cda-adc.ca](mailto:jokeefe@cda-adc.ca).*

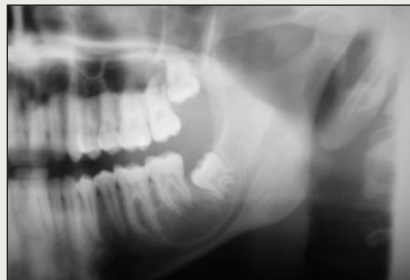The presence of either partially erupted or fully impacted third molars often prompts a visit to the dental office. Patients may experience symptoms ranging from pain to mild or moderate trismus or even acute infection with purulence at the site of the involved tooth. In such instances, immediate treatment is often necessary to alleviate or resolve the patients’ presenting complaint. In the situation of completely impacted third molars, the clinician must make the patient aware of the presence of the impacted wisdom teeth and the presence or absence of any associated pathology. The prophylactic removal of impacted wisdom teeth is often suggested to prevent problems such as infection, carious lesions, destruction of adjacent teeth, periodontal defects involving adjacent teeth, cysts or tumours.<sup>1</sup> Because a large number of wisdom teeth remain impacted or partially impacted (84%) rather than erupting completely (16%), it is important that retained wisdom teeth be carefully monitored for signs of pathology.<sup>2</sup> As a result, it is important that patients undergo panoramic radiography as part

of the initial evaluation when third molar symptoms are part of the chief complaint. Also, the need for proper referral if pathology is suspected, as well as appropriate radiographic follow-up, must be recognized.

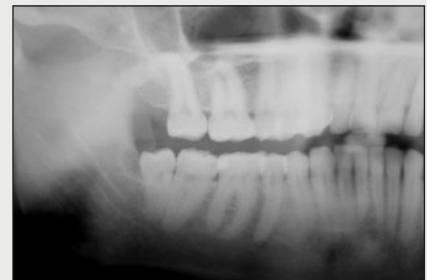Figures 1 to 3 illustrate lesions associated with partially erupted or impacted third molars that might be missed if periapical radiographs alone are used for routine dental evaluation. Further radiographic assessment of some lesions (Fig. 2), including computed tomography or cone beam scanning may be indicated before surgical intervention. If some lesions are not detected early, they can continue to grow. In Fig. 3, for example, because the lesion appears distal to the crown of the tooth, it might not have been detected with periapical radiography, which would have allowed further enlargement of the cyst and increased morbidity. The presence of large pathologies such as ameloblastoma or odontogenic keratocyst can lead to destruction of a large portion of the mandible, and resection and reconstruction of the affected bone may be required.



**Figure 1:** Panoramic radiograph shows a well-defined radiolucent lesion at the apex of tooth 38 which might have been missed on a periapical radiograph.



**Figure 2:** Panoramic radiograph showing a radiolucent lesion between teeth 38 and 37. Even with panoramic radiography, this lesion might be mistaken for a normal anatomic variation.



**Figure 3:** This radiograph demonstrates enlargement of the follicular space suggestive of a dentigerous cyst.

**Case Report**

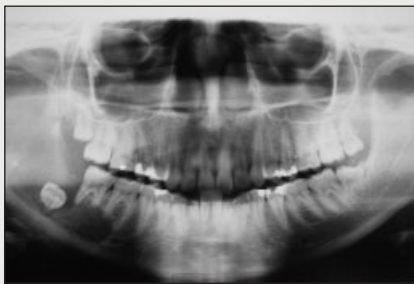Figures 4 to 24 illustrate a situation in which an abnormality associated with an impacted third molar tooth went undetected for several years because of a lack of appropriate radiographic assessment. As a result, the patient had to undergo significant surgical resection and reconstruction.

An otherwise healthy 17-year-old woman presented with a large radiolucent lesion of the right mandibular body and ramus, involving the coronoid process and sigmoid notch area. Radiographic examination revealed that tooth 48 was impacted within the lesion. There was also evidence of radicular resorption of teeth 46 and 47. Clinical examination revealed expansion of the mandibular body, which was palpable intraorally and along the inferior border of the mandible. The examination was supple-

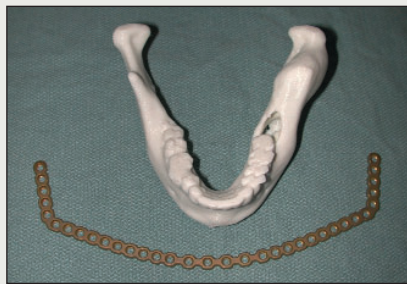mented by computed tomography, which helped to define the extent of the pathology.

Before a definitive treatment plan was established, incisional biopsy was performed, and a diagnosis of follicular-type ameloblastoma was confirmed. The treatment plan included resection of the mandibular ramus and body and immediate reconstruction of a microvascular fibular flap. To help minimize functional and esthetic deficits, a 3-D acrylic model was fabricated preoperatively to assist in the overall surgical plan.

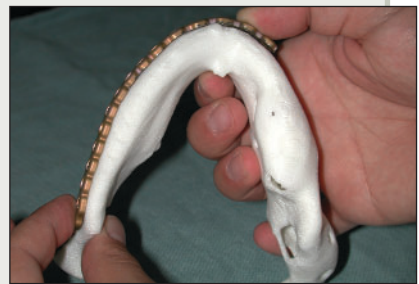The surgical treatment involved a multidisciplinary approach: a plastic surgical team harvested the fibular flap, and the mandible was resected by the oral and maxillofacial surgery team. Figures 7 to 22 illustrate the step-by-step removal of the lesion and reconstruction of the mandible.



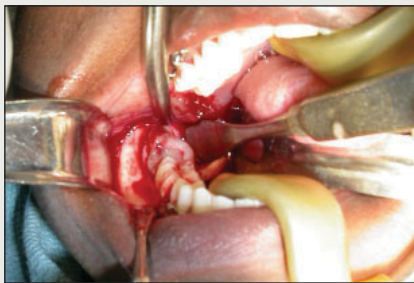
**Figure 4:** Impacted tooth 48 is apparent within a large radiolucent lesion of the right mandibular body and ramus. There is also evidence of radicular resorption of teeth 46 and 47.



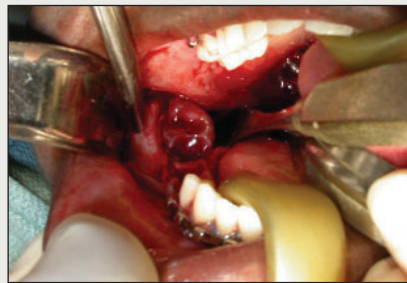
**Figure 5:** This mirror-image model allowed for prebending of the reconstruction plate, which was needed for fixation of the vascularized fibular flap to the native mandible.



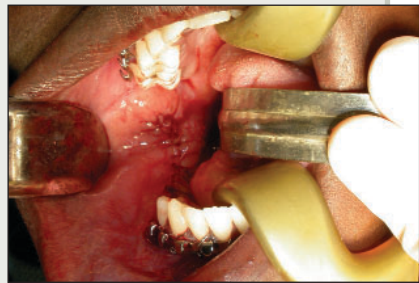
**Figure 6:** This photograph shows the reconstruction plate bent to reproduce an appropriate mandibular contour. The expansion of the mandibular body at the site of the abnormality can also be appreciated in this view.



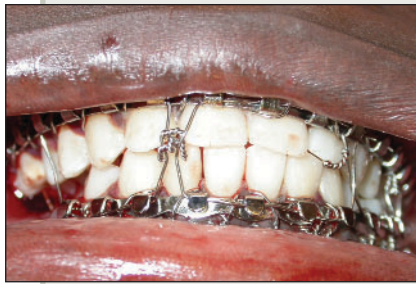**Figure 7:** An incision is made around the intraoral extension of the lesion where the biopsy was performed. Frozen sections were taken to confirm that the soft tissues were free of pathology.



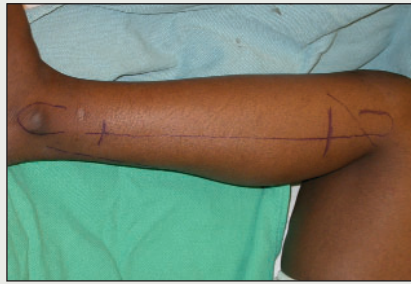**Figure 8:** The teeth anterior to the planned resection margin are removed, as is the soft-tissue portion of the lesion to allow for closure over the defect.



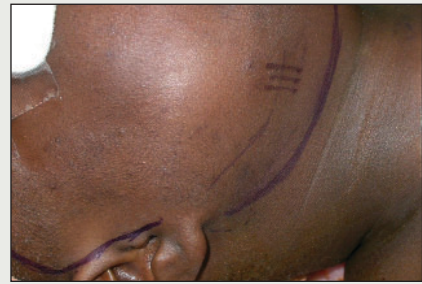**Figure 9:** The area is sutured to prevent communication between the intraoral and extraoral approaches to the mandible.



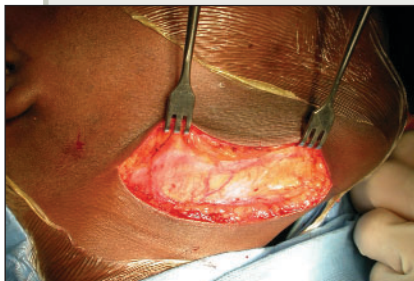
**Figure 10:** The mandible is placed into intermaxillary fixation to prevent postoperative malocclusion after the mandibular reconstruction.



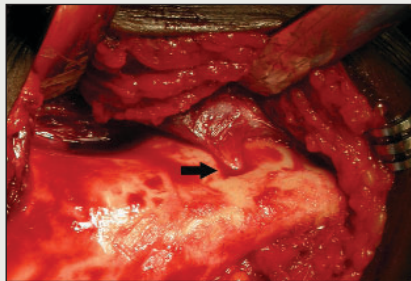
**Figure 11:** The fibula is harvested through a lateral approach while the mandible is being resected.



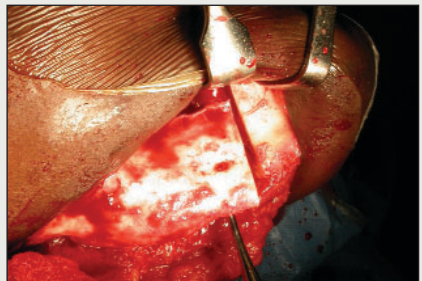
**Figure 12:** Landmarks are identified to protect structures such as the marginal mandibular branch and the temporal branch of the facial nerve.



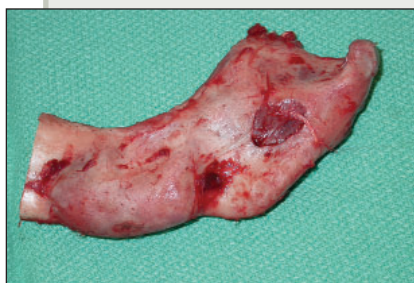**Figure 13:** The platysma muscle is exposed through the submandibular approach to the mandibular body. Careful dissection is necessary to protect the mandibular portion of the facial nerve as well as the facial artery and vein.



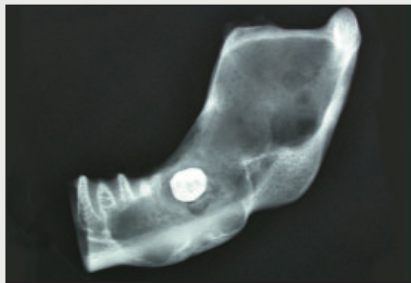**Figure 14:** The mandible is exposed and the mental nerve identified as it exits the mental foramina (arrow). The nerve will be sectioned and marked to allow for repair after the mandibular resection.



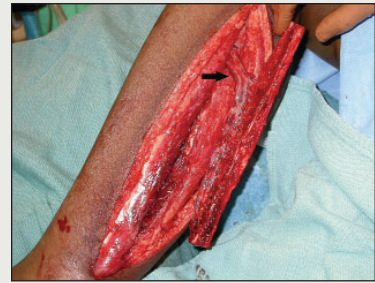**Figure 15:** An anterior resection osteotomy is created to allow removal of the affected ramus and body.



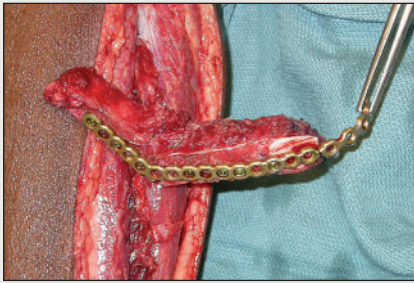**Figure 16:** A medial view of the resected specimen shows expansion of the mandibular body and obliteration of the coronoid process and sigmoid notch.



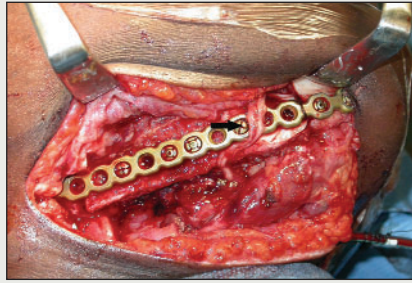
**Figure 17:** A digital radiograph of the specimen after its removal.



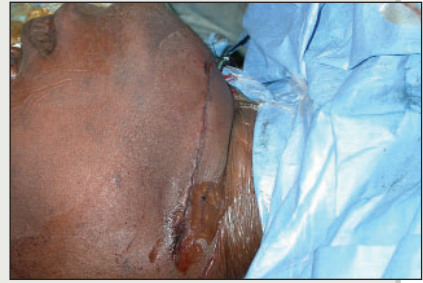**Figure 18:** The fibula is harvested with the vascular pedicle intact (arrow).



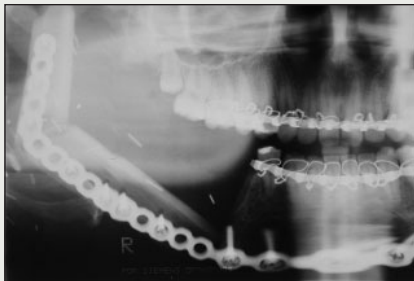
**Figure 19:** The fibula is shortened and an osteotomy created to reproduce the mandibular angle. The segments are fixed to the reconstruction plate while the vascular pedicle is kept intact to minimize ischemic time.



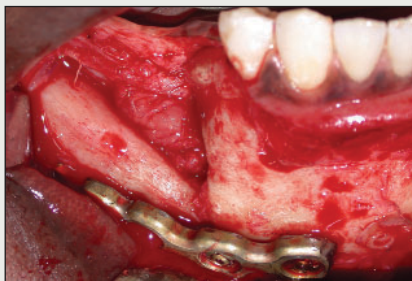
**Figure 20:** A sural nerve is harvested and used to repair the inferior alveolar nerve, which was removed with the tumour. The arrow highlights the distal portion of the nerve as it travels forward to the mental nerve.



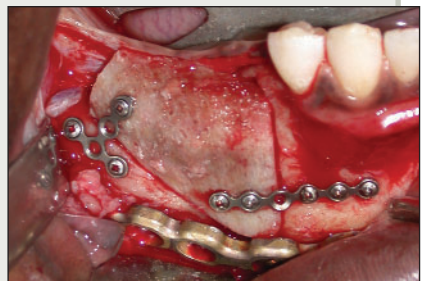**Figure 21:** Wound closure, in layers, is accomplished with subcuticular skin sutures to minimize scarring.



**Figure 22:** Immediate postoperative panoramic radiograph demonstrates the reconstruction of the mandible with a vascularized fibular flap and reconstruction plate.



**Figure 23:** Clinical image of the reconstruction site 30 months after surgery shows the triangular-shaped defect in the area of the proposed implant placement.



**Figure 24:** Bone was harvested from the iliac crest and shaped to reconstruct the defect so that the patient could eventually have an implant-supported restoration in the right posterior mandible.

## Discussion

Proper assessment of retained third molars, especially when local symptoms are present, should include a comprehensive clinical and radiographic evaluation. Obtaining a panoramic radiograph at the time of initial evaluation is highly recommended. The limitations of periapical radiography in assessing partially or fully impacted third molars include, but are not limited to, the inability to properly assess the relationship of the tooth to the inferior alveolar nerve canal, the limited ability to evaluate the morphology of the third molar root and the inability to detect abnor-

malities associated with the tooth or teeth in question.

It is the responsibility of the clinician to properly diagnose and manage any pathology associated third molars that are removed. In the case of local pericoronal or periapical lesions associated with impacted third molars, removal of the tooth and biopsy of the soft-tissue lesion should be performed simultaneously. If there is suspicion of a more aggressive pathologic process, appropriate referral should be considered. In this situation, the patient should be made aware of the clinical findings, the various treatment modalities available and the overall prognosis. ♦

## THE AUTHORS



*Dr. Haddad is in private practice in Toronto, Ontario. He is an associate in dentistry, discipline of oral and maxillofacial surgery, at the faculty of dentistry, University of Toronto, Toronto, Ontario.*



*Dr. Talwar is an assistant professor, discipline of oral and maxillofacial surgery, at the faculty of dentistry, University of Toronto, Toronto, Ontario.*



*Dr. Clokie is a professor and head of oral and maxillofacial surgery at the faculty of dentistry, University of Toronto, Toronto, Ontario.*

*Correspondence to: Dr. Cameron Clokie, Oral and Maxillofacial Surgery, Faculty of Dentistry, University of Toronto, 124 Edward St., Toronto, ON M5G 1G6. Email: [cameron.clokie@utoronto.ca](mailto:cameron.clokie@utoronto.ca).*

*The authors have no declared financial interests.*

*Dr. Clokie's full-day session at the ODA annual meeting, titled "Oral surgery for the general practitioner", will be presented on Friday, April 7.*

## References

1. Knutsson K, Brehmer B, Lysell L, Rohlin M. Pathoses associated with mandibular third molars subjected to removal. *Oral Surg Oral Med Oral Pathol Oral Radiol Endod* 1996; 82(1):10-7.
2. Venta I, Murtomaa H, Ylipaavalniemi P. A device to predict lower third molar eruption. *Oral Surg Oral Med Oral Pathol Oral Radiol Endod* 1997; 84(6):598-603.