

The "Point of Care" section answers everyday clinical questions by providing practical information that aims to be useful at the point of patient care. The responses reflect the opinions of the contributors and do not purport to set forth standards of care or clinical practice guidelines. Readers are encouraged to do more reading on the topics covered. This month's responses are provided by the Canadian Academy of Restorative Dentistry and Prosthodontics (CARDP). If you would like to submit or answer a question, contact editor-in-chief Dr. John O'Keefe at [jokeefe@cda-adc.ca](mailto:jokeefe@cda-adc.ca).



## QUESTION 1

### How do I remove, modify and reuse functional indirect restorations in the event of a complication?

In clinical practice, a frustrating and often challenging dilemma arises when complications occur in teeth with fixed restorations, a situation that is particularly trying in cases of recently completed treatment. A recent study<sup>1</sup> found that 2 of the most common complications associated with conventional crowns (cast gold and porcelain-fused-to-metal) were the need for endodontic treatment (3%) and the occurrence of porcelain fracture (3%). For conventional fixed prostheses, endodontic treatment on abutments was needed in 11% of cases, and porcelain fracture occurred in 2% of cases.<sup>1</sup>

During endodontic therapy, the restoration must be modified (i.e., perforated) to allow access to the root canal system and in many cases, significant coronal tooth or core structure must be removed to complete the endodontic treatment. To repair the endodontic access opening in a cast gold or porcelain-fused-to-metal crown, an indirect cast inlay best re-establishes the occlusal integrity of the original restoration. Use of amalgam for direct repair in a gold restoration causes considerable corrosion and produces noticeable changes in both the amalgam and the gold (non-gamma-2 amalgam corrodes slightly less than other amalgams). Large composite resin repairs do not provide a satisfactory long-lasting solution to the problem, although they can be resurfaced.

Complications related to porcelain fracture can be repaired directly with composite resin or by bonding new porcelain to the existing restoration. These techniques, although routinely used in clinical practice, can provide a less-than-desirable result.

Hence, it is legitimate to ask whether the restoration can be modified, removed, repaired and cemented and still remain functional.

One example would be a case in which nonsurgical endodontic therapy is required on a tooth restored

with a gold crown or porcelain-bonded-to-metal restoration. First, I inform the patient that this procedure involves creating an access hole in the crown, completing the necessary treatment and then repairing the access opening as described above. I also explain that it might be possible to remove the restoration, repair it in the laboratory and replace it so that it functions as it did before the complication. However, I also point out the possible complications of this procedure and tell the patient that not all crowns and bridges can be removed.

#### Remove

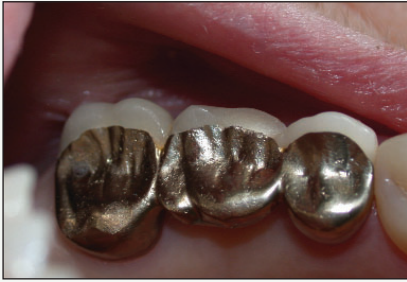Figure 1 illustrates a case of porcelain fracture in a functional 26-year-old fixed prosthesis; in addition, the porcelain no longer matches the remaining natural teeth. This was judged to be a suitable case for removal and repair of the prosthesis.

In my experience, the Metalift Crown and Bridge Removal System (Classical Practice Resources, Baton Rouge, La.) is suitable for gently removing single crowns (cast gold and porcelain-fused-to-metal) and fixed prostheses. An outline of the procedure follows:

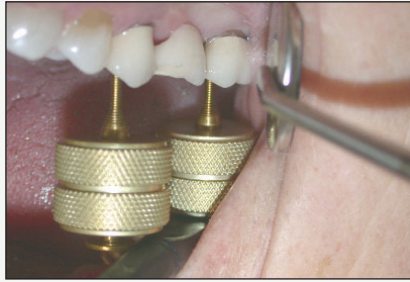- Make a pilot hole with a #1 high-speed bur.
- Establish a precision channel, into which a self-taping instrument threads the metal in the restoration (Fig. 2).
- After engaging the metal, the instrument pushes against the tooth or core material, breaks the cement layer and lifts the restoration.

#### Repair

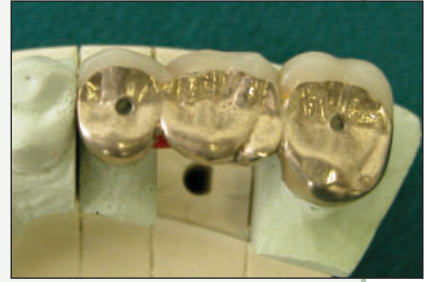Once the prosthesis has been positioned on a model (Fig. 3), occlusal perforations in metal can be repaired expeditiously in the laboratory with a laser welder (Figs. 4 and 5). If the perforation is large, a sprue of the same metal is placed in the perforation and is laser-welded to the restoration. For smaller perforations, wire of the same metal is used. Special care



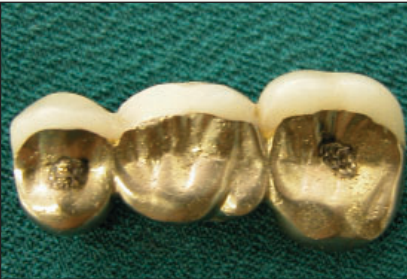**Figure 1:** A functional 26-year-old fixed prosthesis in which the porcelain was fractured and no longer matched the remaining natural teeth.



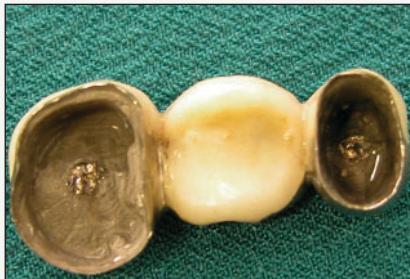**Figure 2:** Two self-taping instruments threaded into abutments.



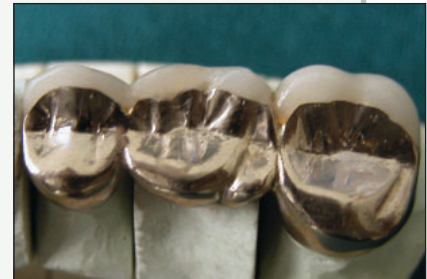**Figure 3:** Prosthesis on model ready for repair.



**Figure 4:** Occlusal view of laser-welded repair.



**Figure 5:** Internal view of laser-welded repair.



**Figure 6:** Repaired restoration ready for cementation.

and attention must be exercised to avoid overheating a porcelain-fused-to-metal restoration during laser-welding (the porcelain might pop off if overheated). The restoration is welded both internally and externally. The weld on the internal aspect of the restoration is then adjusted to fit the original die, if available. The occlusal aspect is also refined as necessary.

For an occlusal perforation in porcelain or repair of fractured porcelain, contaminants and moisture must first be removed by soaking the restoration in a “porcelain wash” for at least 4 hours (preferably overnight) or by overnight heat soaking at 200°C to 260°C. Platinum foil is then adapted to the internal aspect of the crown, and opaquer, porcelain and stain are applied. To avoid compromising the repaired porcelain, occlusion adjustment is best performed on the opposing tooth. Should there be difficulty in seating the restoration, the preparation may be relieved (**Fig. 6**).

### Rejoice

I have successfully used this technique not only for restorations with cast metal occlusal surfaces but also for porcelain-fused-to-metal restorations with a porcelain occlusal surface. However, the method does

not work for all ceramic restorations. Reuse of a functional restoration in cases of complication is of obvious advantage to the patient and enhances goodwill between the patient and the clinician. ♦

### THE AUTHOR

**Acknowledgement:** The author gratefully acknowledges the assistance of Art Maister, of Crosstown Dental Laboratory, for technical information and expertise about the laboratory techniques of modification for porcelain and metal perforations.



**Dr. Terry Koltek** maintains a private practice in Winnipeg, Manitoba. He is a member of the CARDP. E-mail: [wtkoltek@gmail.com](mailto:wtkoltek@gmail.com).

The author has no declared financial interests in any company manufacturing the types of products mentioned in this article.

### Reference

1. Goodacre CJ, Bernal G, Rungcharassaeng K, Kan JY. Clinical complications in fixed prosthodontics. *J Prosthet Dent* 2003; 90(1):31–41.

### Further Reading

- Barzilay I. Point of Care — How can I remove fixed prostheses effectively? *J Can Dent Assoc* 2004; 70(6):409–10.
- Westerman R.D. Metalift. Video and slide show of the Metalift technique available from: URL: [www.metalift.com](http://www.metalift.com).

## QUESTION 2

## How can we restore abfraction lesions in a predictable and esthetically pleasing manner?

### Background

Over the past 20 years, restorative procedures have become more elaborate and are now driven to a greater extent by esthetic considerations.<sup>1</sup> In addition, patients are keeping their teeth longer and desire more esthetically pleasing outcomes, even as they present with more complex lesions, such as abfraction lesions (Fig. 1) in the

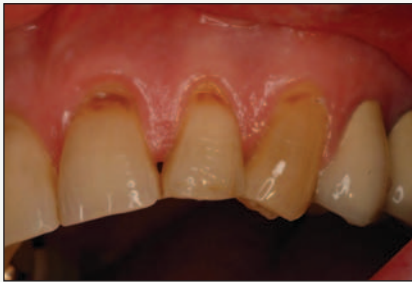maxillary anterior and premolar region. Abfraction lesions are angular, wedge-shaped defects found in the cervical regions of the teeth. They are thought to be caused by mechanical overloading initiated by cuspal flexure and failure of the dentin and enamel.<sup>2</sup> They typically present on the labial aspect of the tooth.

Abfraction lesions present with an array of sequelae, including sensitivity to cold and mechanical stimulation because of exposure of the dentin, root caries because of inadequate removal of plaque from within the defect and gingival hyperplasia because of improper root architecture and emersion profile.<sup>3,4</sup> These secondary signs and symptoms do not necessarily appear simultaneously.

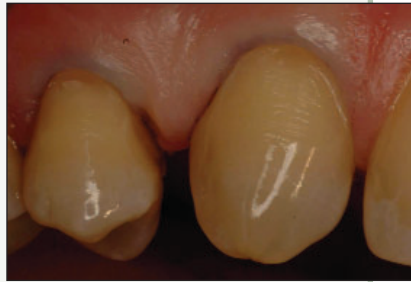Along with offering a predictable and esthetic restorative technique, the clinician needs to educate (and motivate) the patient, as well as providing a means to prevent additional lesions. Patients must understand the causes of abfraction (bruxism, clenching and toothbrush abrasion) and usually require the assistance of a well-fitted acrylic splint that is set up with mutually protected occlusion.<sup>5,6</sup>

### Clinical Protocol for Treating Abfraction Lesions

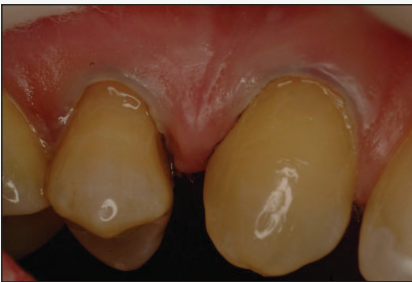1. Administer topical and local anesthetic as for a routine restorative procedure.
2. Select the shade of the restoration before beginning any restorative procedure and before desiccation of the teeth.
3. Place a braided gingival retraction cord along the entire facial surface and into the col areas; use either size #0 or #00 cord (UltraPak, Ultradent Products, Inc., South Jordan, Utah), depending on the depth of the lesion. In areas where the lesion extends beyond 1 mm, perform gingivectomy using a microsmooth pass with a radiosurgical instrument (no. 113F,



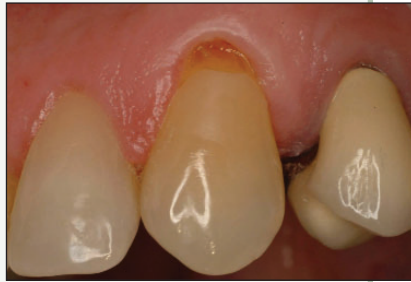**Figure 1:** Abfraction lesions and the development of root caries.



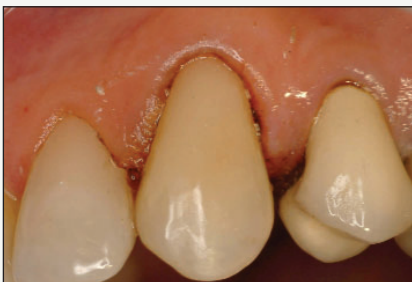**Figure 2:** Preparation of the lesion with gingival retraction, chamfer gingival margin and long coronal level.



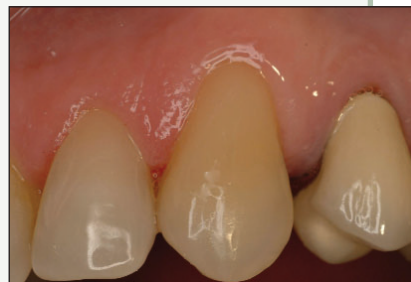**Figure 3:** Glossy appearance of the preparation before the application of bond resin.



**Figure 4a:** Appearance of an abfraction lesion before preparation for restoration. Root caries and rolled gingival contour are evident.



**Figure 4b:** Completed restoration after removal of the retraction cord and finishing of the proximal margins.



**Figure 4c:** Improvement of the marginal tissue response and restorative camouflaging 2 weeks after the procedure.



Ellman International, Inc., Hewlett, N.Y.). A rubber dam can be placed as an alternative to the retraction cord; however, a dam becomes more cumbersome in cases of multiple abfraction lesions and can actually impede access during preparation and finishing.

4. Perform the initial preparation with a pencil diamond (model 2856-016, Brasseler, Savannah, Ga.) along the long axis of the tooth, placing a 0.7-mm chamfer margin at the gingival crest, such that it extends beyond the facio-proximal line angle into the embrasure area (Fig. 2). The coronal margin consists of a long bevel (1.5–2.0 mm) and typically extends to the middle third of the facial surface or at least 2 mm coronal to the lesion (depending on desired esthetics). Caries and softened dentin are removed using a #6 round bur (Premier, King of Prussia, Pa.) operated at slow speed.
5. The restorative phase consists of good isolation (cotton rolls, low-volume suction, etc.) and application of a self-etching primer system (Kuraray, Kurashiki, Okayama, Japan). As retention is a key factor in success, it is important to recognize that self-etching systems are capable of performing at the level of a total etch and prime system with regards to tensile bond strength.<sup>7,8</sup> Prime the dentin until it appears as a glossy surface on drying (Fig. 3). Apply a thin layer of bond resin (Bisco, Itasca, Ill.), and light-cure for 20 seconds. Depending on the depth of the lesion, apply a flowable composite (Bisco) into the deeper areas of the preparation. Then, sculpt and shape a microhybrid composite (Kerr, Orange, Calif.) with a fine plastic instrument (IPC-A, Hu-Friedy, Chicago, Ill.) such that only minimal finishing is needed; light-cure for only 10 seconds to minimize shrinkage and reassess contours and margins.
6. Perform precise finishing at high speeds using both a pointed and a round-ended carbide finishing bur (ET6, 7653-012, Brasseler, Savannah, Ga.), followed by a composite polishing cup (Enhance, Caulk Dentsply, Milford, Del.) and finally a rubber cup or lens (Ivoclar Vivadent, Mississauga, Ont.). Before final finishing of the gingival and interproximal regions, remove the retraction cord. Lastly, pass floss between the adjacent contacts, followed by medium and fine metal sandpaper strips (Premier) to contour

and finish the proximal margins. The restoration is completed with a final cure of 40 seconds.

This abfraction technique allows for increased bond surface area and strength, a hygienic periodontal response, increased resistance form, improved hard-tissue esthetics (Figs. 4a to 4c) and, in particular, reduced postoperative sensitivity, all of which will assist the clinician in the delivery of this type of restorative procedure and lead to greater patient satisfaction. ♦

## THE AUTHOR



*Dr. Peter Taylor maintains a private practice in Oakville, Ontario, with a focus on restorative dentistry. He is a staff dentist at Oakville Trafalgar Memorial Hospital and a part-time clinical instructor and lecturer at the University of Western Ontario in London. He is a member of the CARDP. E-mail: [taydent@aol.com](mailto:taydent@aol.com).*

*The author has no declared financial interests in any company manufacturing the types of products mentioned in this article.*

## References

1. Allen EP, Bayne SC, Brodine AH, Cronin RJ Jr, Donovan TE, Kois JC, and other. Annual review of selected dental literature: report of the Committee on Scientific Investigation of the American Academy of Restorative Dentistry. *J Prosthet Dent* 2002; 88(1):60–88.
2. Litonjua LA, Andreana S, Patra AK, Cohen RE. Assessment of stress analyses in the theory of abfraction. *Biomed Mater Eng* 2004; 14(3):311–21.
3. Rees JS, Jagger DC. Abfraction lesions: myth or reality? *J Esthet Restor Dent* 2003; 15(5):263–71.
4. Piotrowski BT, Gillette WB, Hancock EB. Examining the prevalence and characteristics of abfractionlike cervical lesions in a population of U.S. veterans. *J Am Dent Assoc* 2001; 132(12):1694–701.
5. McCubbin J. Abfraction. *J Am Dent Assoc* 2002; 133(6):694,696.
6. Rees JS, Hammadeh M, Jagger DC. Abfraction lesion formation in maxillary incisors, canines and premolars: a finite element study. *Eur J Oral Sci* 2003; 111(2):149–54.
7. Kubo S, Konishi Y, Yokota H, Hayashi Y. Effect of one-bottle self-etching primer on microleakage of cervical restorations. *J Dent Res* 1999; 78(Spec Iss):2965.
8. Santini A, Ivanovic V, Ibbetson R, Milia E. Influence of marginal bevels on microleakage around Class V cavities bonded with seven self-etching agents. *Am J Dent* 2004; 17(4):257–61.

## QUESTION 3

## What are the critical success factors for anterior single-tooth immediate-load implants?

### Background

The use of dental implants to support a prosthesis is a well-established, successful, predictable treatment. Early research supported a 2-stage

approach to implant placement, with delayed loading of the implant. This approach helped to prevent micro-movements that could interfere with osseointegration and also helped to avoid epithelial down-growth during healing, which might lead to subsequent implant failure.

The placement of dental implants has now evolved to allow immediate implant loading with placement of a provisional restoration. Recent studies have shown that success rates for immediate-load treatment can be comparable to those with the traditional approach. However, careful patient evaluation and treatment planning are necessary to optimize results.

The most important factors to consider when deciding if a particular patient is a candidate for immediate implant loading when restoring an anterior edentulous space are related to the surgery, the host, the implant and the patient's occlusion.

### Criteria for Treatment Success

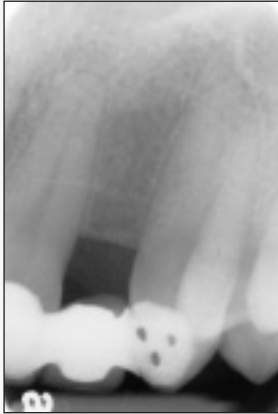#### *Surgery-Related Criteria*

The dental practitioner must ensure stability of the implant once it has been placed, to allow osseointegration to take place. Therefore, an implant must not be placed in soft spongy bone, and the operator must be experienced and have excellent surgical technique.

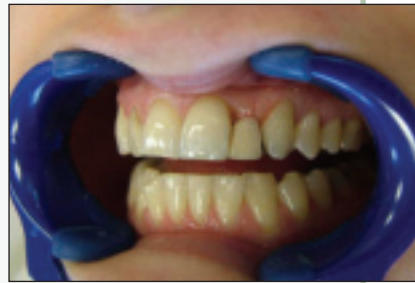#### *Host-Related Criteria*

The quality and quantity of bone available to receive the implant are also crucial. Radiography must show good bone density, the future site of the implant must be clear of anatomic interference (such as sinuses or adjacent teeth) and free of infection, and bony defects must be absent. Intraorally there must be adequate buccal-lingual width as well as preservation of the cortical plate. If any of these factors is inadequate, a traditional 2-stage implant is recommended, as there may be a requirement for bone augmentation and additional healing time.

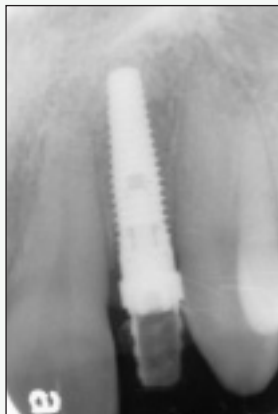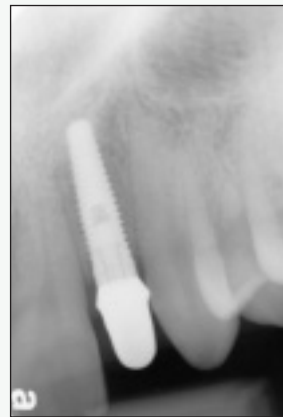Metabolic diseases or other conditions could compromise healing. Therefore, systemic health concerns such as diabetes or a recent history of radiation therapy would contraindicate immediate loading. Current smokers and patients with poor oral hygiene are not candidates for this treatment strategy.



**Figure 1:** A patient requested improvement of a problematic Maryland bridge. Radiography showed a lack of development of inter-radicular bone and a flat bony contour.

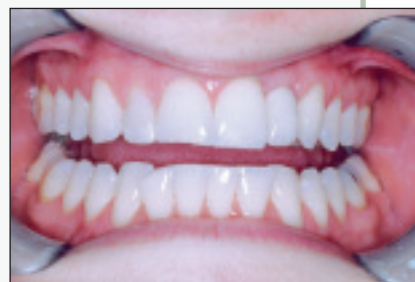

**Figure 2:** This photograph of the patient shows a lack of harmony in the soft tissue.



**Figure 4:** Radiograph of the completed implant with ceramic abutment. Note the length and positioning of the implant.

**Figure 3:** Radiograph of the temporary abutment after immediate-load placement of the implant.



**Figure 5:** Photograph of the completed implant showing the development of soft tissue and papilla, which was aided by immediate provisionalization and soft-tissue manipulation.

### Implant-Related Criteria

Successful immediate-load implants have a screw type design with a roughened surface and should be a minimum of 10 mm in length.

### Occlusion-Related Criteria

It is important that the provisional crown of an immediate-load implant not have any centric or excursive occlusal loading during the healing phase after implant placement. As well, parafunctional habits such as bruxism may be a strong contraindication to immediate loading.

### Conclusions

There are no clear disadvantages to immediate-load implants except that the treatment cannot be delivered in all areas of the mouth. The advantages include shorter duration of treatment, ease of determining the ideal implant position (immediately after extraction), minimal invasiveness and tissue trauma, optimization of bone height and preservation of soft tissue, simplified prosthetic phase and, most important, increased patient comfort and psychological well-being. Immediate-load implants provide immediate improvement in appearance and immediate results. Therefore, before extraction or implant placement, the practitioner should consider whether an immediate-load implant will be suitable for the patient.

Immediate provisionalization of dental implants is a highly rewarding approach to treatment when cases are carefully selected, proper technique is applied, and hard- and soft-tissue considerations are methodically evaluated. **Figures 1 to 5** are pre- and post-treatment images and radiographs of an immediate-load implant recently completed by the author. ♦

### THE AUTHOR



*Dr. Brian Friesen maintains a private dental practice in Winnipeg, Manitoba, with a focus on implant and cosmetic dentistry. He is a past president of the CARDP. E-mail: brianfriesen@mts.net.*

*The author has no declared financial interests in any company manufacturing the types of products mentioned in this article.*

### Further Reading

- Gapski R, Wang HL, Mascarenhas P, Lang NP. Critical review of immediate implant loading. *Clin Oral Impl Res* 2003; 14(5):515-27.
- Kan JY, Rungcharassaeng K. Immediate placement and provisionalization of maxillary anterior single implants: a surgical and prosthodontic rationale. *Pract Periodontics Aesthet Dent* 2000; 12(9):817-24.
- Misch CE, Hahn J, Judy KW, Lemons JE, Linkow LI, Lozada JL, and others. Workshop guidelines on immediate loading in implant dentistry. November 7, 2003. *J Oral Implantol* 2004; 30(5):283-8.
- Morton D, Jaffin R, Weber HP. Immediate restoration and loading of dental implants: clinical considerations and protocols. *Int J Oral Maxillofac Implants* 2004; 19(Suppl):103-8.

## THE CANADIAN ACADEMY OF RESTORATIVE DENTISTRY AND PROSTHODONTICS



**The objectives of the CARDP are:** To promote the improvement of the health of the Canadian public through the advancement of the art and science of restorative and prosthetic dentistry; to promote the highest standard of professional ethics among its members and amongst the members of the dental profession; to encourage the quality and the quantity of teaching of restorative and prosthetic dentistry in Canadian university dental schools; to provide continuing education in restorative and prosthetic dentistry for its members and for members of the dental profession in Canada.

**The annual meetings of the CARDP** take place in different regions of the country. **In 2006, the Annual Meeting will take place at the Casino Nova Scotia Hotel in Halifax, Nova Scotia, from September 28 to October 1.** This facility, at the centre of a cosmopolitan city with old-world character and modern style, is a wonderful venue for the 2006 CARDP meeting!

**For more information,** contact convention chair Dr. Maureen Andrea at [chesterclinicdental@aliantzinc.ca](mailto:chesterclinicdental@aliantzinc.ca).

## QUESTION 4

When restoring the teeth of partially edentulous patients with removable partial dentures, do you consider placing implants to enhance the retention and stability of the prosthesis?

In general, removable partial dentures (RPDs) are retained by clasps, adhesive attachments, intracoronal or extracoronal attachments, telescope crowns or root caps. Selection of the appropriate retentive element depends on the remaining tooth substance (i.e., intact clinical crown, decayed tooth in need of a crown restoration, or with only the root being salvageable), the intramaxillary and intermaxillary relations and the patient's esthetic prefer-

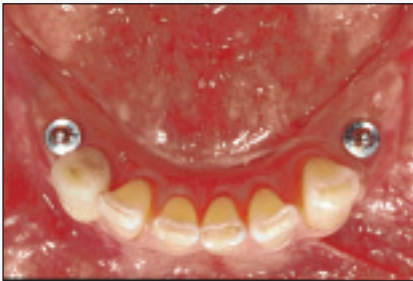ences. For an intact, caries-free tooth intended as a retentive abutment, the best option is a clasp or an adhesive attachment, whereas a filled or decayed vital tooth is better restored with a crown or a telescope crown. For a nonvital tooth with a destroyed clinical crown, the root cap is the most appropriate solution because it offers greatest latitude with regard to the position of the clinical crown, which must be determined in advance with a diagnostic set-up.

Common complaints associated with RPDs, especially in bilateral free-end situations (Kennedy Class I), are lack of stability, poor retention and unesthetic clasping. The use of implants as retainers in partially edentulous patients has been mentioned only rarely in the literature<sup>1-3</sup> but is a helpful adjunct in 2 situations:

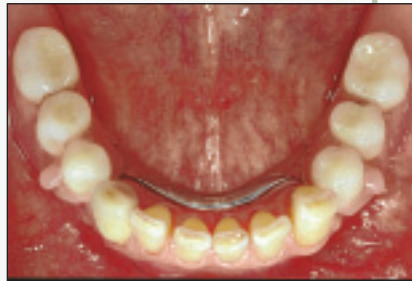1. when implants are indicated in addition to the natural teeth to improve retention, stability and support of the RPD; to allow simpler prosthesis design; and to enhance the patient's comfort
2. when implants are inserted as an alternative to the natural teeth to facilitate retention of an RPD that is detached from the residual dentition and to replace a potential post when its prognosis is questionable.

Placement of an implant for an RPD restoration is appropriate when only a few teeth suitable for use as retainers are present and/or when the position of these abutments is unfavourable, e.g., grouped in one region instead of spread over the entire arch. In the latter situation, the supportive area is increased and the soft-tissue load reduced by placement of additional implants. When the RPD rests more on the teeth and implants than on the mucosal tissues, the extension of the prosthesis base can be reduced and the patient's comfort enhanced.

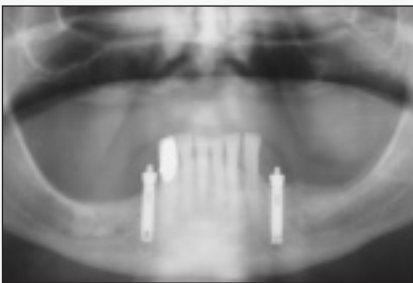
In cases with residual anterior dentition (bilateral free end), either



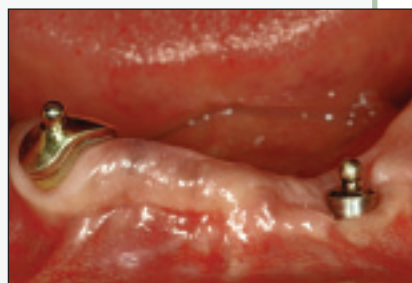**Figure 1a:** Kennedy Class I situation, with bilateral free end.



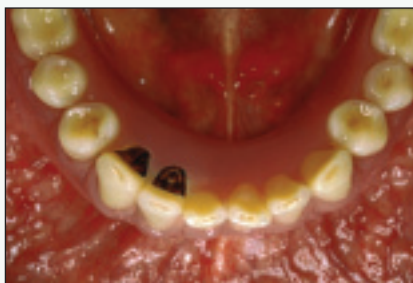**Figure 1b:** The removable partial denture is retained by the implants in the first premolar region.



**Figure 1c:** Radiograph shows that tooth 33 is free of caries and tooth 43 was previously restored with a crown.



**Figure 2a:** Tooth 33 has been replaced by an implant that incorporates a ball abutment.

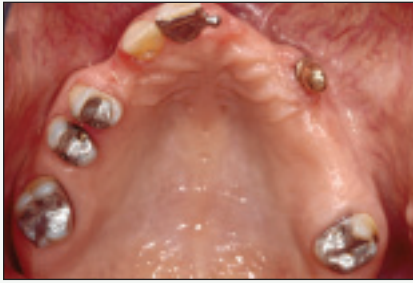

**Figure 2b:** Overdenture prosthesis with a backing in the area of the root cap (teeth 42 and 43).

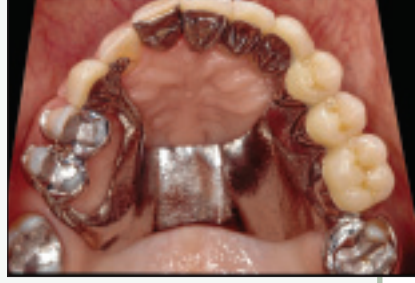

**Figure 2c:** Radiograph showing the root cap (tooth 43) and the implant (region 33).

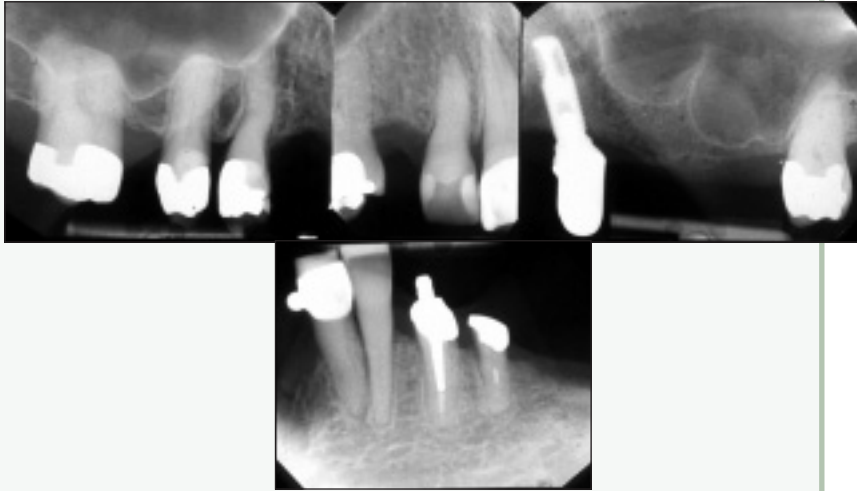



**Figure 3a:** An implant with telescope crown in region 23 provides additional retention.



**Figure 3b:** Removable partial denture is retained by an adhesive attachment (tooth 11), an implant and posterior clasps.



**Figure 3c:** Periapical radiographs showing the residual dentition in the upper and lower jaws, with adhesive attachments (teeth 11 and 42), implant (region 23) and a root cap (tooth 34).

caries-free or sufficiently restored (**Fig. 1a**), clasps are generally indicated but are frequently not acceptable to the patient because of esthetic concerns. With implants placed distal to the posterior teeth on each side, sufficient retention can be achieved and the need for clasps eliminated; the residual dentition then becomes detached from the restoration (**Figs. 1b** and **1c**).

Implants are also indicated when the prognosis for an abutment is questionable or poor and the risk of failure must be minimized. In this situation, the clinician must decide upon

the ideal implant position, which determines whether tooth extraction and immediate implant placement are required or whether an adjacent edentulous region is more suitable for implant insertion (**Figs. 2a, 2b** and **2c**).

Single implants placed as additional support for an RPD are easily augmented by prefabricated attachments, such as ball abutments or locators. Because these attachments are positioned in line with the implant axis and the matrix abutment systems allow only limited divergence, the orientation of the implant must coincide with the path of insertion for the prosthesis. Otherwise, individual abutments such as telescope crowns are fabricated by the laboratory technician in a more complex procedure (**Figs. 3a, 3b** and **3c**). These aspects must be considered during treatment planning and necessitate a thorough diagnosis at the outset to avoid mechanical complications and loss of retention capability because of component wear. ♦

## References

1. Ganz SD. Combination natural tooth and implant-borne removable partial denture: a clinical report. *J Prosthet Dent* 1991; 66(1):1-5.
2. Keltjens HM, Kayser AF, Hertel R, Battistuzzi PG. Distal extension removable partial dentures supported by implants and residual teeth: considerations and case reports. *Int J Oral Maxillofac Implants* 1993; 8(2):208-13.
3. Mitrani R, Brudvik JS, Phillips KM. Posterior implants for distal extension removable prostheses: a retrospective study. *Int J Periodontics Restorative Dent* 2003; 23(4):353-9.

## THE AUTHOR



**Dr. Nicola Zitzmann** is an assistant professor at the University of Basel, Switzerland, and specialist for reconstructive dentistry. Dr. Zitzmann was a guest speaker at the annual CARDP meeting held in September in Quebec City. E-mail: [N.Zitzmann@unibas.ch](mailto:N.Zitzmann@unibas.ch).

The author has no declared financial interests in any company manufacturing the types of products mentioned in this article.