

# Clinical Showcase

*Clinical Showcase is a series of pictorial essays that focus on the technical art of clinical dentistry. The section features step-by-step case demonstrations of clinical problems encountered in dental practice. If you would like to propose a case or recommend a clinician who could contribute to Clinical Showcase, contact editor-in-chief Dr. John O'Keefe at [jokeefe@cda-adc.ca](mailto:jokeefe@cda-adc.ca).*

---

## Use of Lasers for Nonsurgical Treatment of Mandibular Bicuspid with Sinus Tract

Ronald N. Porth, DMD

---

Determining the efficacy of dental lasers in the various disciplines of dentistry has been a long, slow process. As with any new technology, years of clinical use have been required to evaluate useful fundamental qualities. One area where the neodymium:yttrium–aluminum–garnet (Nd:YAG) laser has demonstrated such qualities is in endodontics. Basic endodontic research and clinical studies began in Europe in 1990 with the work of Dr. Norbert Gutknecht at the RWTH Aachen University in Germany. A standardized technique was developed that combines chemical disinfection during the mechanical stage of canal preparation with multiple appointments for laser disinfection applied in canals dried with paper points. Conventional gutta-percha techniques for obturation are used to seal the canals.

In 1995 I modified the standardized technique by eliminating all chemical disinfectants and limiting the use of laser to the final appointment immediately before obturation. With the modified method, the only irrigant is water, which is used during the mechanical stage and during lasing of the canals. Water irrigation during lasing was added to decrease the potential for adverse temperature effects in the periradicular area. This article illustrates 2 qualities of Nd:YAG laser use in endodontics: potential as a disinfecting agent and potential to stimulate the onset of healing.

### Case Report

The patient presented with a localized gingival swelling on the labial mucosa in the area of tooth 44, revealing the presence of a sinus tract (Fig. 1).

A radiograph of the tooth (Fig. 2) revealed 2 periradicular radiolucent areas, one located periapically and the other located on the mesiolateral aspect of the midroot region. The presence of a lateral canal was not obvious radiographically.

Chronic suppurative periradicular periodontitis was diagnosed, and the patient was told that future laser or surgical treatment might be required should the sinus tract not heal after routine endodontic treatment. Endodontic treatment was initiated, a working length was determined

(Fig. 3), and the canal was enlarged to a #30 size file. The canal was then flared with Gates Glidden drills #2 and #3, followed by a #30 Canal Finder reciprocating file (Endo Technic, San Diego, Calif.) to taper the walls of the canal. The only irrigant used was water.

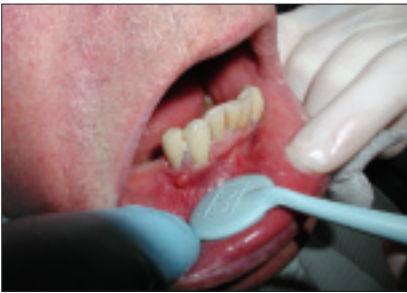The canal was then disinfected with an Nd:YAG laser set to pulse at 15 Hz with a heat setting of 0.75 W. The 200- $\mu$  laser fibre was placed in the canal to the working length minus 1 mm (Fig. 4), and the canal was continuously irradiated for 40 seconds with a tapping motion 1 to 3 mm from the apex. Water irrigation was applied during lasing (Fig. 5). Because of the lateral area of infection, a second period of irradiation was initiated at the approximate level of the lateral radiolucency. In this treatment the laser fibre was moved in a circular manner, again with water irrigation and again for 40 seconds. The entire area of the root was irradiated. The fibre was moved up from the apical area to the coronal area then back down with continuous circular lasing.

Obturation was completed using a Quickfill (J.S. Dental, Ridgefield, Conn.) gutta-percha #20 carrier, which uses friction to soften the gutta-percha (Fig. 6). Spreaders were then used to compact the gutta-percha, and an accessory gutta-percha point was placed in the canal.

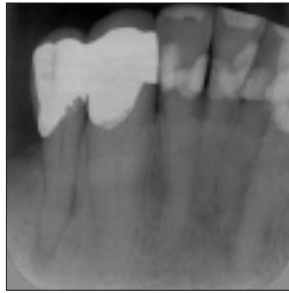The postoperative radiograph indicated that the primary canal was adequately filled to the working length. In addition it showed a previously undetected accessory canal leading at a right angle from the main canal, in the region of the lateral radiolucency (Fig. 7).

Twenty-four hours after the procedure, the patient had not experienced any postoperative discomfort and had not required analgesics. The lesion had not changed in appearance.

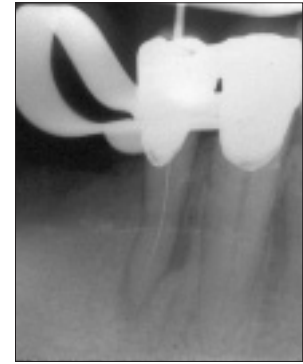
At the 1-week follow-up visit, the gingival enlargement exhibited a 50% decrease in size (Fig. 8). The 1-month postoperative photograph (Fig. 9) indicated shrinkage of the lesion to a small residual bump 2 mm in diameter. An attempt to probe the sinus tract was not successful (Fig. 10). The 3-month radiograph of tooth 45 indicated healing of the lateral radiolucency (Fig. 11). The periapical area also appeared to be resolving. At that time, several



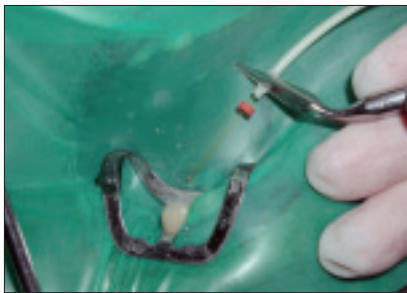
**Figure 1:** Preoperative appearance of localized gingival swelling on the labial mucosa.



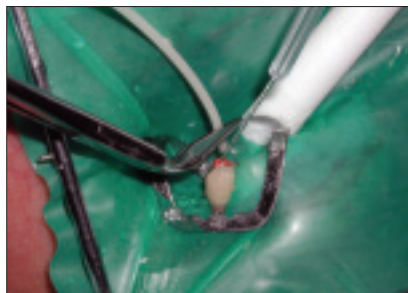
**Figure 2:** Preoperative radiograph revealing 2 periradicular radiolucencies.



**Figure 3:** Radiograph of working-length file.



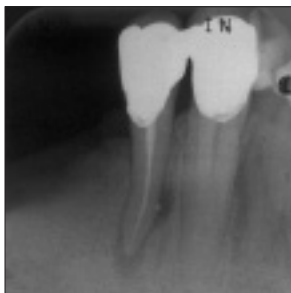**Figure 4:** Laser fibre ready to be inserted into canal.



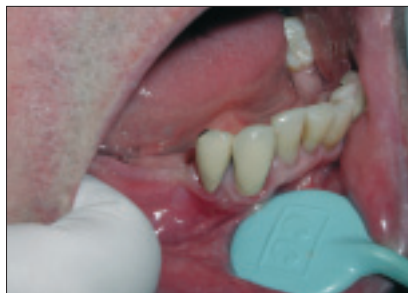**Figure 5:** Laser irradiation of canal with water irrigation.



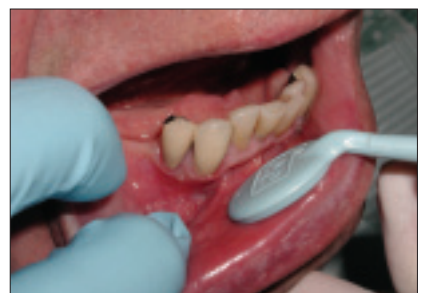**Figure 6:** Quickfill gutta-percha point.



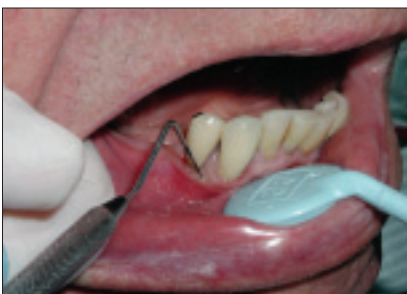**Figure 7:** Postobturation radiograph revealing presence of lateral canal.



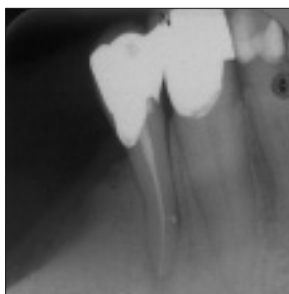**Figure 8:** Appearance of lesion 1 week after procedure.



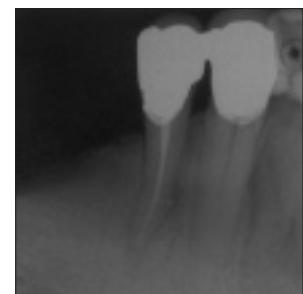
**Figure 9:** Appearance of lesion 1 month after procedure.



**Figure 10:** Photograph illustrating that the sinus tract has been closed off; no surface opening could be located.



**Figure 11:** Three-month postoperative radiograph.



**Figure 12:** Six-month postoperative radiograph indicating continued healing of both periradicular areas.

radiographs were taken from different angles to be certain of the results to date. **Figure 12**, a radiograph obtained 6 months after the procedure, showed continued healing of both periradicular areas.

### Conclusion

This case illustrates the potential use of the Nd:YAG laser as a disinfection agent in endodontic treatment. In addition, this softened gutta-percha technique permitted obturation of lateral canals that could not be prepared mechanically. It appears that the combination of these 2 techniques provided the necessary conditions to allow for periradicular healing, as demonstrated both clinically and radiographically. ✦



*Dr. Ronald N. Porth maintains a private practice in Abbotsford, B.C.*

*Correspondence to: Dr. Ronald N. Porth, 204-2001 McCallum Rd., Abbotsford, BC V2S 3N6. E-mail: [ronaldporth@hotmail.com](mailto:ronaldporth@hotmail.com).*

*The author has no declared financial interests in any company manufacturing the types of products mentioned in this article.*

## GET YOUR NAME IN PRINT

**We're always looking for contributors to make our national flagship journal a better publication. Here's how you can help:**

- ✦ If you're a clinician who loves to share knowledge, you could write a clinical review article on a topic that is new or developing in your area of interest. Or why not contribute to the *Clinical Abstracts* section by suggesting 6 references of recent, good-quality clinical research articles and writing a short commentary, indicating why these articles are important?
- ✦ If you're a clinician who would like to share practical tips about everyday techniques or procedures, and you have great photos to illustrate your case, then perhaps the *Point of Care* or *Clinical Showcase* sections are for you.
- ✦ If you're a clinician who has strong opinions on topics related to clinical dentistry and the environment in which dentistry is practised, write a letter to the editor.
- ✦ If you're a clinician with an artistic bent, send us a photo of your artwork and we will consider it for our cover. If you're poetically inclined, a submission to *Poet's Pen* would be welcome. Or if you have a flair for storytelling, perhaps you'd like to share a funny anecdote for the *On the Lighter Side* column.

For more information on how you can contribute to our flagship journal, contact *JCDA* editor-in-chief Dr. John O'Keefe at [jokeefe@cda-adc.ca](mailto:jokeefe@cda-adc.ca), tel.: (613) 523-1770 or 1-800-267-6354, ext. 2297.