

# Clinical and Radiologic Behaviour of Ameloblastoma in 4 Cases

• Sinem Gümğüm, DDS, PhD •  
• Başak Hoşgören, MD •

## A b s t r a c t

*Ameloblastoma is a benign but locally aggressive epithelial odontogenic neoplasm. It represents 1% of all tumours of the jaw bone. In 80% of cases, it is localized in the mandibular molar and ascending ramus area, mostly associated with an unerupted tooth. It occurs over a wide range of ages (mean age is in the 20s or 30s) and with equal frequency in men and women. Ameloblastoma may be discovered during a routine radiographic examination or as a clinically observed developing mass. It has a characteristic, but not diagnostic, radiographic appearance. It can be treated by enucleation, bone curettage or wide resection. The rate of local recurrence is high when it is treated inadequately. We describe the clinical and radiologic behaviour of ameloblastoma and discuss treatment protocols and the possibility of conservative management of this tumour. Our results suggest the importance of long-term follow-up with various radiographic techniques.*

**MeSH Key Words:** ameloblastoma; mandibular neoplasms; odontogenic tumors

© J Can Dent Assoc 2005; 71(7):481-4  
This article has been peer reviewed.

**A**meloblastoma is a benign odontogenic tumour usually located in the jaw bone.<sup>1-3</sup> The tumour is thought to originate from sources that include residual epithelium from tooth germ; epithelium of odontogenic cysts; stratified squamous epithelium; and epithelium of the enamel organ.<sup>4</sup> It represents approximately 1% of oral tumours; 80% of ameloblastomas occur in the mandible and the remaining 20% in the upper jaw.<sup>1,2,5</sup> The area of the mandible that is most affected is the third molar region.<sup>1</sup> Reported cases of ameloblastoma occur over a wide range of ages, with the mean age in the 20s or 30s, and with equal frequency in men and women.<sup>2</sup>

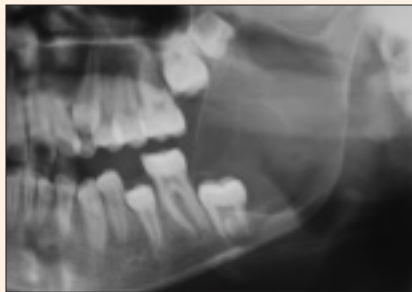Clinically, ameloblastoma appears as an aggressive odontogenic tumour, often asymptomatic and slow growing, with no evidence of swelling. It can sometimes cause symptoms such as swelling, dental malocclusion, pain and paresthesia of the affected area.<sup>1</sup> It spreads by forming pseudopods in marrow spaces without concomitant resorption of the trabecular bone. As a result, the margins of the tumour are not clearly seen on radiographs or during surgery and the tumour frequently recurs after inadequate surgical removal.<sup>2,6</sup> The appearance of septae on the radiograph usually represents differential resorption of the

cortical plate by the tumour and not actual separation of tumour portions.<sup>7</sup> Because of its slow growth, recurrences of ameloblastoma generally present many years and even decades after primary surgery.<sup>6</sup> When treated inadequately, malignant development is a possibility.<sup>1</sup>

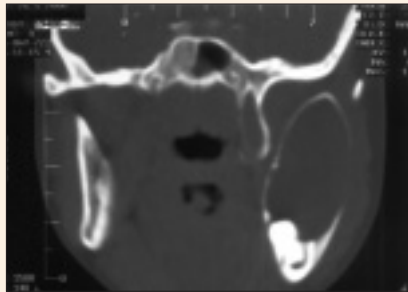
In most cases ameloblastoma has a characteristic but not diagnostic radiographic appearance.<sup>2</sup> The neoplasm usually appears as a unilocular radiolucent area or a multilocular radiolucent area with a honeycomb appearance.<sup>1,2</sup> Resorption of the adjacent tooth roots is not uncommon.<sup>2</sup> In many cases an unerupted tooth, most often a mandibular third molar, is associated with the tumour.<sup>4</sup>

Ameloblastoma is divided into 3 clinicoradiologic groups: solid or multicystic, unicystic and peripheral. The solid ameloblastoma is the most common form of the lesion (86%). It has a tendency to be more aggressive than the other types and has a higher incidence of recurrence.<sup>4</sup> Unicystic ameloblastoma has a large cystic cavity with luminal, intraluminal or mural proliferation of ameloblastic cells. It is a less aggressive variant and it has a low rate of recurrence,<sup>4,8,9</sup> although lesions showing mural invasion are an exception and should be treated more aggressively.<sup>9</sup> Histologically, the peripheral ameloblastoma appears

## Case 1

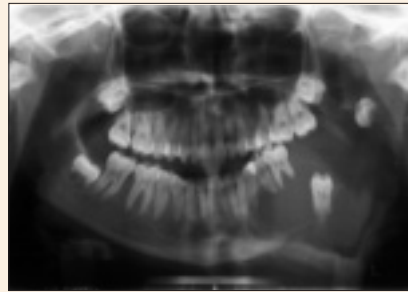

**Figure 1a:** Large, expansile lesion in the left mandible.



**Figure 1b:** Coronal computed tomography (CT) scan showing a large expansile lesion, cortical thinning and minimal destruction.

## Case 2



**Figure 2:** Plain radiograph showing an expansile lesion with impacted teeth.

similar to the solid ameloblastoma. It is uncommon, usually presenting as a painless, non-ulcerated sessile or pedunculated gingival lesion on the alveolar ridge.<sup>4</sup> Several histopathologic types of ameloblastoma are described in the literature, including those with plexiform, follicular, unicystic, basal cell, granular cell, clear cell, acanthomatous and desmoplastic patterns.<sup>2</sup>

Treatment of mandibular ameloblastoma continues to be controversial. It can change with clinicoradiologic variant, anatomic location and clinical behaviour of the tumour.<sup>5</sup> Also, the age and the general state of health of the patient are important factors. Treatment consists of wide resection, curettage and enucleation.<sup>6,10</sup> Rates of recurrence may be as high as 15% to 25% after radical treatment and 75% to 90% after conservative treatment.<sup>10</sup> The aim of this article is to describe conservative treatment of ameloblastoma by enucleation and bone curettage in cases where the lower border of the mandible is not affected by the tumour.

## Case Reports

### Clinical Findings

All 4 patients were referred to the department of oral and maxillofacial surgery at Gazi University with a painless swelling in the mandible. Their ages ranged from 12 to 28 years and all were female. The lesions were located in the mandible: 2 on the right side and 2 on the left. In all patients, clinical examination revealed a large, expansile mass in the molar region of the mandible. The swellings were hard, painless to palpation and covered by normal mucosa. No anesthesia was reported. In 3 patients extraoral swelling was observed.

### Radiologic Findings

In case 1, plain radiography showed a large multilocular expansile lytic lesion occupying the left mandible from the first molar to the coronoid process including the impacted second molar. The lesion was 50 by 65 mm. The cortical bone was very thin and no periosteal reaction was observed. Neither caries nor root resorption was observed in the

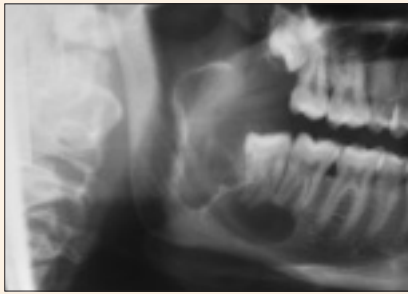second molar. There was a slight change in the direction of the mandibular canal. Condylar and coronoid processes were intact, and no fracture was observed (**Fig. 1a**). Coronal computed tomography (CT) showed a large expansile lesion with cortical thinning and minimal destruction of cortical bone (**Fig. 1b**).

In case 2, panoramic radiography showed a large (about 60 by 90 mm), expansile mass occupying the left mandible from the condyle to the left lateral incisor tooth. The second molar and a developing third molar were impacted. The margins of tumour were not clear. Expansion of the lesion had caused displacement of the adjacent premolars and first molar. Root resorption was observed in the first molar. The direction of the mandibular canal could not be observed. Lingual and buccal bone cortex was resorbed and a periosteal reaction was observed (**Fig. 2**). The radiolucent area was multilocular and the base of the mandible was damaged and thinned.

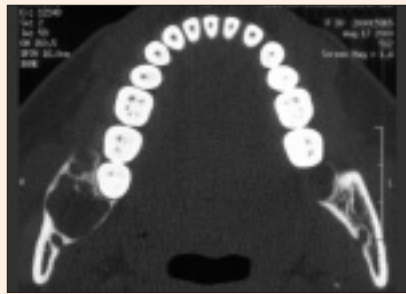
In case 3, plain radiography revealed a mixed radiopaque and radiolucent area, about 20 by 50 mm, extending from the right second molar to the right coronoid process including the right ascending ramus area. Under the right third molar, the lesion divided into 2 fragments. No root resorption or caries was observed on the third molar, but some root resorption had occurred in the second molar. The periodontal ligament space of the second and third molar was connected to the cystic radiolucent area (**Fig. 3a**). Axial CT showed an expansile lesion, erosion, cortical destruction and thinning (**Figs. 3b and 3c**). Three years after surgery, no tumour recurrence was observed on plain radiography or CT scan (**Fig. 3d**).

In case 4, panoramic radiography showed a loculated lesion extending from the mesial root of the right first molar to the right third molar. The lesion was about 25 by 45 mm and had caused root resorption in the first and second molars. The direction of the mandibular canal was slightly changed. The base of the mandible was not destroyed and the borders of the lesion were well defined.

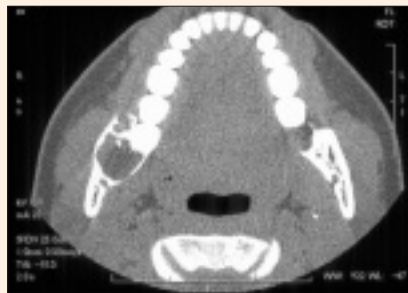**Case 3**



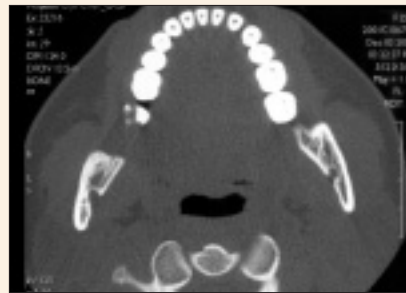**Figure 3a:** Plain radiograph showing a loculated lesion in the right mandible.



**Figure 3b:** Preoperative CT scan showing the soft tissue component of the lesion.

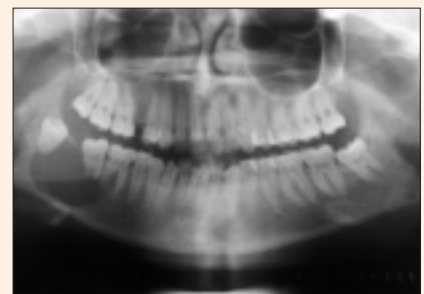

**Figure 3c:** An expansile lesion with erosive changes, cortical destruction and thinning.



**Figure 3d:** Three years after treatment.

**Case 4**



**Figure 4:** Plain radiograph showing a radiolucent lesion that caused resorption in the root of the adjacent tooth.

reveal unilocular ameloblastomas, resembling dentigerous cysts or odontogenic keratocysts.<sup>11</sup> The radiographic appearance of ameloblastoma can vary according to the type of tumour. CT is usually helpful in determining the contours of the lesion, its contents and its extension into soft tissues.<sup>11</sup>

In a patient with a swelling in the jaw, the first step in diagnosis is panoramic radiography. However, if the swelling is hard and fixed to adjacent

tissues, CT is preferred. Although the radiation dose is much higher in CT, the necessity of identifying the contours of the lesion, its contents and its extension into the soft tissues, makes it preferable for diagnosis. Plain radiographs do not show interfaces between tumour and normal soft tissue; only interfaces between tumour and normal bone can be seen. The axial view in contrast-enhanced CT images and the coronal and axial views in magnetic resonance imaging (MRI) clearly show both types of interface.<sup>12</sup> Although there are no appreciable differences between MRI and CT for detecting the cystic component of the tumour, for visualizing papillary projections into the cystic cavity, MRI is slightly superior. MRI is essential for establishing the exact extent of an advanced maxillary ameloblastoma and thus determining the prognosis for surgery.<sup>13,14</sup>

Ameloblastomas are treated by curettage, enucleation plus curettage, or by radical surgery.<sup>8,10</sup> Comparing long-term results for 78 ameloblastomas, Nakamura and others<sup>10</sup> reported that the rate of recurrence is 7.1% after radical surgery and 33.3% after conservative treatment. They recommended wide resection of the jaw as the best treatment for ameloblastoma. In their series of 26 ameloblastomas, Sampson and Pogrel<sup>5</sup> showed that nearly 31% of tumours recurred after conservative surgery. In our study, we treated 3 patients with enucleation and bone curettage and 1 patient with hemimandibular resection. In 3 years follow-up, there has been no recurrence of the tumours.

The lesion had caused displacement of the third molar (Fig. 4).

**Treatment**

After clinical and radiologic examination, an incisional biopsy was performed in all cases and the lesions were diagnosed as ameloblastoma. Cases 1, 3 and 4 were treated with enucleation and bone curettage under local anesthesia. Case 2 was treated by hemimandibulectomy as the inferior border of the mandible was resorbed and the margins of tumour were not clearly visible. After wide resection, the mandible was reconstructed using the fibular free flap under general anesthesia. We preferred enucleation and bone curettage in 3 patients because their lesions were well defined and the patients were young. We are monitoring these patients for recurrence of ameloblastoma, which will be treated by resection. In the 3 years since their surgery, no recurrence has been observed by radiography or CT.

**Discussion**

Ameloblastoma is a tumour with a well-known propensity for recurrence.<sup>8</sup> Several factors may influence the rate of recurrence: the clinicoradiologic appearance of the tumour, the anatomic site and the adequacy of the initial surgery.<sup>1,2,6</sup>

Radiologically, the lesions are expansile, with thinning of the cortex in the buccal–lingual plane. The lesions are classically multilocular cystic with a “soap bubble” or “honeycomb” appearance. On occasion, conventional radiographs

## Conclusion

In this article, we show that when the lower border of the mandible is not affected, ameloblastoma can be treated by a combination of enucleation and bone curettage. However, when the tumour has resorbed the inferior border of the mandible, radical treatment including wide resection is required. We preferred conservative surgery in the treatment of 3 cases because of the well-defined margins. However, in the fourth case, we used wide resection with 1 cm clear margins. In all cases, long-term follow-up with radiography, and especially CT, is important. We are still monitoring our patients annually using radiography and CT. ♦



*Dr. Gümgüm is a research assistant, department of oral and maxillofacial surgery, School of Dentistry, Gazi University, Ankara, Turkey.*



*Dr. Hoşgören is a radiologist, department of radiology, Dr. Muhtetin Ulker Emergency Care and Traumatology Hospital, Ankara, Turkey.*

*Correspondence to: Dr. Sinem Gümgüm, 46. sokak 23/1 06510 Bahçelievler/Ankara –Turkey. E-mail: [sgumgum@gazi.edu.tr](mailto:sgumgum@gazi.edu.tr).*

*The authors have no declared financial interests.*

## References

1. Becelli R, Carboni A, Cerulli G, Perugini M, Iannetti G. Mandibular ameloblastoma: analysis of surgical treatment carried out in 60 patients between 1977 and 1998. *J Craniofac Surg* 2002; 13(3):395–400.
2. Iordanidis S, Makos C, Dimitrakopoulos J, Kariki H. Ameloblastoma of the maxilla — case report. *Aust Dent J* 1999; 44(1):51–5.
3. Nakamura N, Mitsuyasu T, Higuchi Y, Sandra F, Ohishi M. Growth characteristics of ameloblastoma involving the inferior alveolar nerve: a clinical and histopathologic study. *Oral Surg Oral Med Oral Pathol Oral Radiol Endod* 2001; 91(5):557–62.
4. Hollows P, Fasanmade A, Hayter JP. Ameloblastoma – a diagnostic problem. *Br Dent J* 2000; 188(5):243–4.
5. Sampson DE, Pogrel MA. Management of mandibular ameloblastoma: the clinical basis for a treatment algorithm. *J Oral Maxillofac Surg* 1999; 57(9):1074–7.
6. Ferretti C, Polakow R, Coleman H. Recurrent ameloblastoma: report of 2 cases. *J Oral Maxillofac Surg* 2000; 58(7):800–4.
7. Asseal LA. Surgical management of odontogenic cysts and tumors. In: Peterson LJ, editor. *Principals of oral and maxillofacial surgery*. Vol 2. Philadelphia: Lippincott-Raven; 1997. p. 694–8.
8. Kim SG, Jang HS. Ameloblastoma: a clinical, radiographic and histopathologic analysis of 71 cases. *Oral Surg Oral Med Oral Pathol Oral Radiol Endod* 2001; 91(6):649–53.
9. Rosenstein T, Pogrel MA, Smith RA, Regezi JA. Cystic ameloblastoma — behaviour and treatment of 21 cases. *J Oral Maxillofac Surg* 2001; 59(11):1311–6.
10. Nakamura N, Higuchi Y, Mitsuyasu T, Sandra F, Ohishi M. Comparison of long-term results between different approaches to ameloblastoma. *Oral Surg Oral Med Oral Pathol Oral Radiol Endod* 2002; 93(1):13–20.
11. Rampton P. Teeth and jaws. In: Sutton D, editor. *Textbook of radiology and imaging*. Philadelphia: Churchill-Livingstone; 1998. p. 1388–9.
12. Cihangiroglu M, Akfirat M, Yildirim H. CT and MRI findings of ameloblastoma in two cases. *Neuroradiology* 2002; 44(5):434–7.
13. Kawai T, Murakami S, Kishino M, Matsuya T, Sakuda M, Fuchihata H. Diagnostic imaging in two cases of recurrent maxillary ameloblastoma: comparative evaluation of plain radiographs, CT and MR images. *Br J Oral Maxillofac Surg* 1998; 36(4):304–10.
14. Ziegler CM, Woertche R, Brief J, Hassfeld S. Clinical indications for digital volume tomography in oral and maxillofacial surgery. *Dentomaxillofac Radiol* 2002; 31(2):126–30.

**Come Enjoy  
the Experience!**

**2006**

**Canadian Dental Association  
Annual Convention with the  
Newfoundland and Labrador  
Dental Association**

**St. John's, Newfoundland  
August 24-26, 2006**

Watch the CDA Web site and *JCDA* issues  
this fall for updates on the  
scientific sessions and social events.

