

Point of Care

The Point of Care section answers everyday clinical questions by providing practical information that aims to be useful at the point of patient care. The responses reflect the opinions of the contributors and do not purport to set forth standards of care or clinical practice guidelines. This month's responses were provided by speakers at the FDI World Dental Congress, which will be held August 24 to 27 in Montreal, Quebec (pre-Congress courses will take place August 22 and 23). For more information on the Congress, visit www.fdiworldental.org.



Question 1 How can I treat patients who are anxious about dental treatment without disrupting my practice or increasing my own occupational stress?

Background

Dentists often say that they dislike treating dentally anxious patients. Such patients are perceived as difficult and disruptive, causing the practice to run late, angering other patients, and increasing occupational stress for the dentist.

The first step in treating an anxious patient is to recognize that not all anxious patients have a dental phobia and that patients with a dental phobia may have other sources of anxiety. Nonetheless, patients who are fearful of some aspect of dental treatment and those with a true phobia typically present with the same symptoms — the affects of anxiety. To the dentist, all anxious patients appear simply fearful, but each patient has a different subjective experience of anxiety. The intensity of anxiety differs between fearful and phobic patients, which leads to variable degrees of disruptive behaviour. The difference in intensity of anxiety is related to the underlying cause of the fear. A fearful patient may report a frightening dental experience, whereas a patient with a dental phobia may be unable to recall any

specific experience giving rise to the anxiety. Thus, there is a continuum of dental anxiety, ranging from little or no fear to an anxiety so intense that those affected avoid dental treatment. Adopting this perspective of a continuum¹ allows classification of dental anxiety and development of a schema to differentiate dentally anxious patients from those with a dental phobia (Fig. 1).

Epidemiologic evidence supports these different categories of dental anxiety. Oral health surveys have shown that the proportion of people “frightened of some forms of dental treatment” has fallen over the past 20 years, but the proportion of people refusing to attend for treatment because of dental anxiety has remained static at 10% of the population (worldwide). Dental anxiety may be falling because of better understanding of behaviour management and treatment experiences in childhood; conversely, dental phobia may be static because it is an expression of wider psychological problems.

It is essential to differentiate dentally anxious patients, who can be easily treated in general practice, from patients

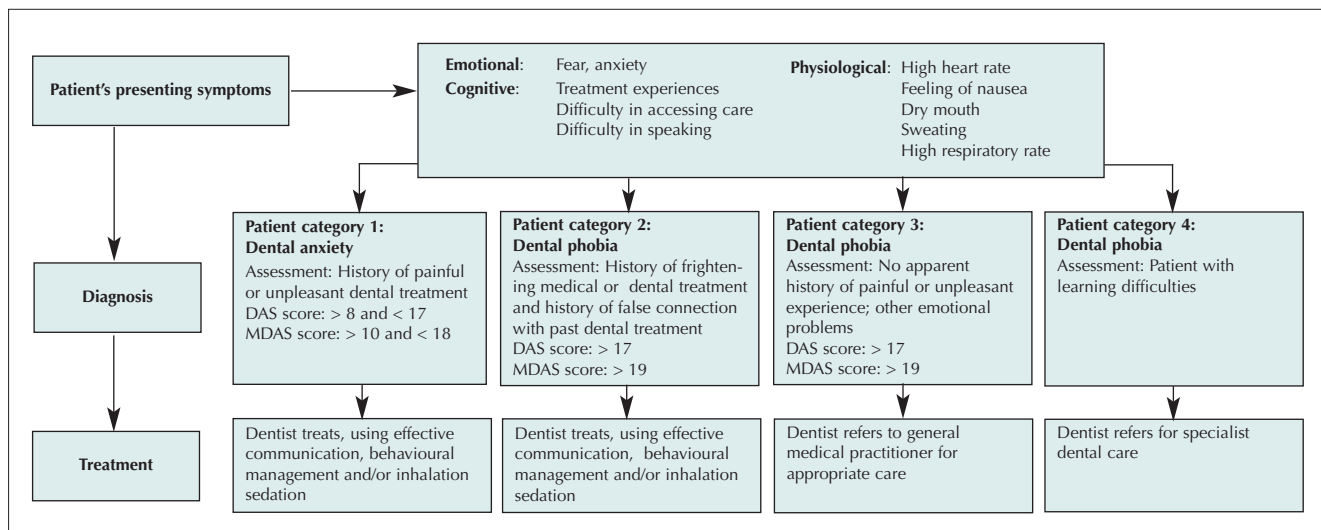


Figure 1: A classification of dental anxiety with regard to dental phobia. DAS = Dental Anxiety Scale, MDAS = Modified Dental Anxiety Scale.

with dental phobia, who require secondary referral. In particular, identifying the latter group may help in avoiding disruption of practice routines and increases in occupational stress.

Specific Management Advice

The following steps¹ should be taken in assessing any patient who presents with dental anxiety:

- For any patient who presents symptoms of dental anxiety, the dentist should set aside time during the first visit, before embarking on treatment, to interview the patient in a setting other than the dental surgery.
- The dentist should take a detailed patient history, including family and social histories, as well as medical and dental histories. An exploration of the patient's dental history will allow previous frightening dental experiences to emerge and will allow the patient to express any fears of dental treatment (see Fig. 1, patient category 1). For dentally phobic patients in category 2, who confuse or make a 'false connection' between past medical and dental experiences, the interview allows an exploration of medical and dental experiences and provides an opportunity for understanding the source of anxiety. For some patients with a dental phobia (Fig. 1, patient category 3), items from the family or social history may provide evidence of a wider psychological problem for which referral is required. Patients with a learning disability (Fig. 1, patient category 4) may be unable to understand what and why dental treatment is necessary; it is this lack of understanding that may cause their dental phobia.

- The Dental Anxiety Scale or Modified Dental Anxiety Scale² may be used to confirm the diagnosis of dental anxiety or dental phobia (the MDAS is available at <http://biologybk.st-and.ac.uk/staffDB/supplemental/humphrisForm.pdf>). These questionnaires, available for both adults and children, are reliable tools for assessing dental anxiety. They are easy to use and offer a means of confirming the diagnosis and gaining rapport with the patient.
- With all of this information, the dentist is in a position to make the diagnosis and then to use communication techniques such as motivational interviewing to negotiate treatment goals with dentally anxious patients and referral goals for those with dental phobia. ♦



Dr. Ruth Freeman is professor, dental public health and behavioural sciences, School of Dentistry, Queen's University, Belfast, Northern Ireland. E-mail: r.freeman@qub.ac.uk.

Dr. Freeman's session at the FDI meeting, titled "Differentiating dental phobia from dental anxiety: strategies for dental practice," will be presented on Friday, August 26.

References

1. Burke FT, Freeman R. Preparing for dental practice. Oxford. Oxford University Press. 2004.
2. Humphris GM, Freeman R, Campbell J, Tuutti H, D'Souza V. Further evidence for the reliability and validity of the Modified Dental Anxiety Scale. *Int Dent J* 2000; 50(6):367-70.

Question 2 Is it true that dentists can identify interproximal caries with contemporary panoramic machines?

Background

The answer to this question is an emphatic "yes"! Because of the projection geometry of the classic mechanical panoramic machine, the horizontal angulation of the beam passes through the interproximal spaces in such a way as to cause overlap of the interproximal surfaces of the posterior teeth, especially the premolars, in the resulting images (Fig. 1).¹ However, several investigators found that coincidentally open panoramic interproximal contacts were not statistically different from bitewing radiographs for detection of interproximal caries.² In one study panoramic images had higher positive predictive values (PPVs) for the detection of interproximal caries than did the corresponding bitewing radiographs when each modality was viewed independently.³ PPVs were defined as the probability that a patient with a positive radiographic finding actually had the disease. When

the 2 types of images were viewed together, the PPVs of the panoramic images decreased. These studies demonstrated that interproximal caries can be accurately diagnosed with panoramic images. However, the mindset of the dental profession is to rely more on bitewing radiographs, undoubtedly because most practitioners believe that the fuzzy panoramic images, with a resolution of 2-4 line pairs per millimeter (lp/mm), simply could not be as good as intraoral images, which have a resolution of 10-12 lp/mm.

Now that robotics and programmable stepper motors are used to control the moving parts, contemporary panoramic machines can be programmed to allow the horizontal angulation of the beam to be directed through the interproximal contacts of the teeth, which eliminates interproximal overlap in the posterior regions (Figs. 2a and 2b). The appropriate angles to accomplish this have been published (Fig. 3).⁴

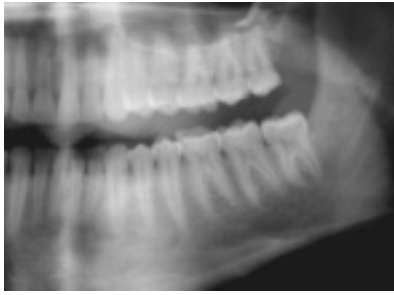


Figure 1: Image obtained with a digital panoramic machine operating in normal mode. Note the interproximal overlap.

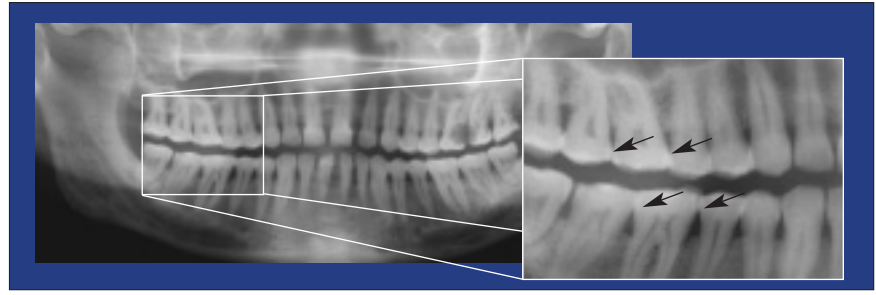


Figure 2a: Image obtained with a digital robotic panoramic machine operating in the normal mode; overlap of the interproximal contacts is evident.

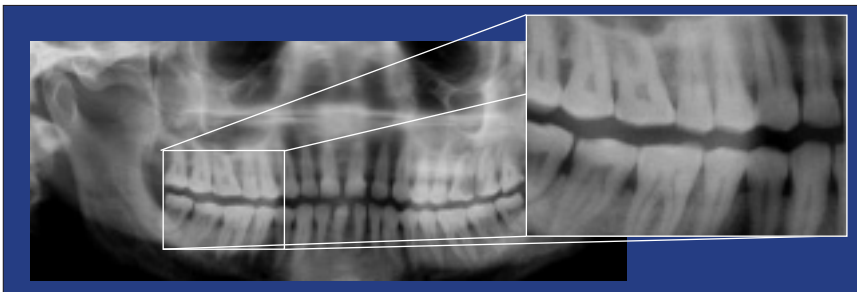


Figure 2b: Image obtained with digital robotic panoramic machine operating in the interproximal mode; open interproximal contacts are evident. Note the sharpness and detail in the images of a phantom.

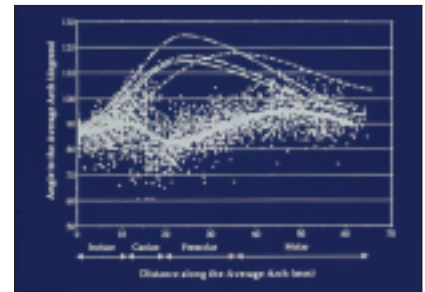


Figure 3: The dotted lines indicate the horizontal projection angle on 3 traditional panoramic machines, which results in maximal interproximal overlap of the premolar contacts. The solid line represents the horizontal angulation of the beam at the interproximal contacts of newer programmable robotic panoramic machines, which open all of the interproximal contacts.

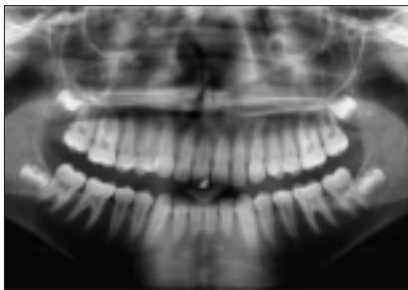


Figure 4: Image of a patient obtained with digital panoramic machine operating in the interproximal mode. Note the open interproximal contacts.

In addition, a resolution of 6 lp/mm can be improved by digital processing software to the extent that the resolution of an image viewed on the computer screen resembles the calculated theoretical resolution based on pixel number and size (approaching 9 lp/mm) (Fig. 4). Research is currently underway at the University of Texas Health Science Center at San Antonio to determine the effectiveness of digital interproximal panoramic images relative to that of F speed or Insight speed (Kodak Co., Rochester, N.Y.) bitewing radiographs for the detection of interproximal caries.

The new U.S. radiation protection guidelines, as published in the National Council on Radiation Protection and Measurements report 145, state that a lead apron is no longer required, that D speed film is not permissible and that rectangular collimation must be

used for all intraoral radiography except for bitewing radiography.⁵

Advantages of Panoramic Imaging

Panoramic radiography has several advantages over bitewing radiography:

- Approximately one-quarter the radiation exposure for 4 bitewing images obtained with F speed film and the long round cone.⁶
- Approximately half the radiation exposure for digital intraoral bitewing images.
- With digital panoramic imaging, approximately one-eighth the radiation exposure for 4 bitewing images obtained with F speed film and the long round cone.
- With the new “fast” digital panoramic cycle, approximately 1/16 the radiation exposure for 4 bitewing images obtained with F speed film and the long round cone.
- With the “fast” digital panoramic cycle and collimation of the beam to cover only the teeth, approximately 1/32 the radiation exposure for 4 bitewing images obtained with F speed film and the long round cone.
- Virtually no sources of infection except the bite block sleeve.

- Diagnostic accuracy similar to or greater than film-based bitewing images.
- Image acquisition simpler and faster than for intraoral bitewing images.

Conclusion

The new panoramic machines are far superior to the older mechanical devices. They can perform many new functions such as better assessment of alveolar bone height for periodontal disease, simple and complex motion tomography and cone beam computed tomography; digital subtraction should be available soon. These are exciting times for the practitioner! ♦



Dr. Robert Langlais is professor and director, graduate oral and maxillofacial radiology program, the University of Texas Health Science Center at San Antonio, Texas. E-mail: Langlais@uthscsa.edu.

Dr. Langlais' session at the FDI meeting, titled "Contemporary radiology in dentistry," will be presented on Tuesday, August 23, as part of the pre-congress courses.

References

1. McDavid WD, Tronje G, Welander U, Morris CR, Nummikoski P. Imaging characteristics of seven panoramic x-ray units: the imaging layer. *Dentomaxillofac Radiol* 1985; 8(suppl):21-8.
2. Terezhalmay GT, Otis LL, Schiff TG, Langlais RP. A comparison of intraoral bitewing with panoramic radiographs for the detection of interproximal caries. *Dentomaxillofac Radiol* 1985; 7(suppl):Abstr 32.
3. Valachovic RW, Douglass CW, Reiskin AB, Chauncey HH, McNeil BJ. The use of panoramic radiology in the evaluation of asymptomatic adult dental patients. *Oral Surg Oral Med Oral Pathol* 1986; 61(3):289-96.
4. Scarfe WC, Nummikoski P, McDavid WD, Wehlander U, Tronje G. Radiographic interproximal angulations: implications for rotational panoramic radiology. *Oral Surg Oral Med Oral Pathol* 1993; 76(5):664-72.
5. National Council on Radiation Protection and Measurements. Report No. 145 — Radiation protection in dentistry; 2003.
6. Underhill TE, Chilvarquer I, Kimura K, Langlais RP, McDavid WD, Preece JW, and other. Radiobiologic risk estimation from dental radiology. Part I. Absorbed doses to critical organs. *Oral Surg Oral Med Oral Pathol* 1988; 66(1):111-20.

Question 3

How can I establish and maintain apical patency while cleaning and shaping the root canal system?

Background

The principal objective of nonsurgical endodontic therapy is total debridement of the root canal system, followed by 3-dimensional obturation of the entire root canal space and its portals of exit with an inert core filling material and a sealer^{1,2} (Figs. 1 and 2).

During the cleaning and shaping procedure, the operator frequently encounters problems such as blocking out the terminus of the root canal, creating a false path or perforating the canal. These mechanical misadventures may lead to outright failure of the clinical endodontic treatment (Figs. 3 and 4).

Clinical Management

The problems encountered in cleaning and shaping the root canal system, as listed above, are due primarily to coronal calcification and to apical tortuosities and ramifications.

Pulp Calcification

Most pulp calcification in the chamber and the canal is caused by irritation and insult to the crown, such as caries, restorations, attrition, abrasion and aging. Calcification occurs mainly by nucleation of calcium deposits at foci in the pulp. The calcifications or pulp stones are usually suspended by collagen fibres in the pulp chamber and the coronal part of the canal, and only seldom block the canal completely.

To negotiate these calcific barriers and reach the apical foramen or foramina, the operator must initially use a very fine file (#8 or #10), with a sharp, pointed tip (not the butt-end type) to dissect the collagen fibres (Fig. 5). The instrument must be precurved, to increase tactile sensitivity. With minimal apically directed pressure, the file is manoeuvred to slip and slide between the microscopic pulp stones, and with a carving backward action, the debris and the calcified aberrations can be removed.

Apical Tortuosities and Ramifications

In the apical area, the main canal has a tendency to ramify. Here, the apical pulp tissues are more fibrous, and more collagen fibres are present histologically. The natural canal foramen is always patent, with an average size of approximately 0.20 mm diameter, but is easily blocked out by the operator (Fig. 3). To maintain apical patency, a small, fine file (e.g., #10), precurved at the tip (Fig. 5), must be used. Frequently, it is impossible to reach the radiographic terminus of the apex because the instrument is not precurved enough, and the file cannot follow the original sharp, short turns of the canal. Nonetheless, with some patience and careful, gentle probing, the pointed tip of the instrument can be slipped into the tortuous canal and sometimes even the accessory canal (Fig. 6).

Once the file has reached the radiographic terminus, a gentle small-amplitude (0.25 to 1 mm) up-and-down

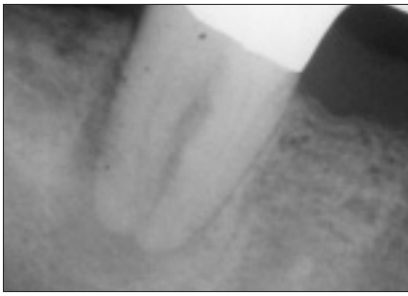


Figure 1: Tooth 47 is a bridge abutment. Coronal calcification is due to many years of heavy restorations and aging (this patient is 72 years old). Canals disappear at the apical third. A radiolucency is present around the roots, indicating that the irritants are egressing from the root canal system through the multiple portals of exit.

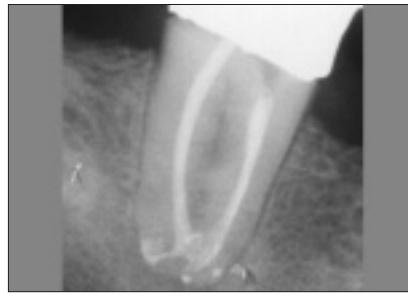

Figure 2: Radiograph taken 6 months after treatment shows total osseous fill-in. The apical complexities are completely sealed as indicated by the stable sealer puff.

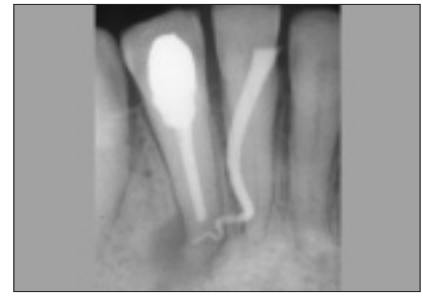


Figure 3: Nonsurgical endodontic treatment was performed on tooth 42. The apical radiolucency is traced with a fine-medium gutta-percha cone. The apical root is tortuous and there is a high possibility of apical canal ramifications and perhaps previous procedural blockage. There is no apical calcification.

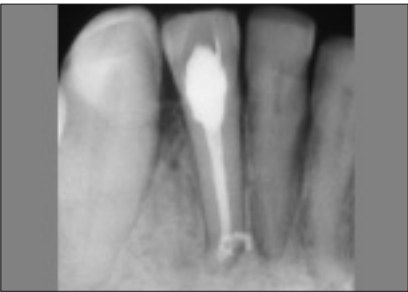


Figure 4: Radiograph taken 7 months after treatment shows improvement of the apical bone. The apical accessory canals and their portals of exit are filled. A previous radiograph showed that the main apical canal had been blocked.

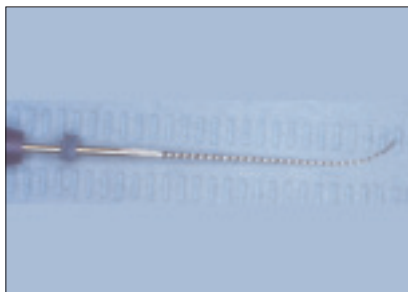

Figure 5: The sharp, pointed #10 file, precurved at a 60-degree angle (or more), is used to dissect the coronal collagen fibres, slip and slide between the suspended microscopic pulp stones in the coronal third of canals, and manoeuvre the apical canal tortuosities and accessory canals.

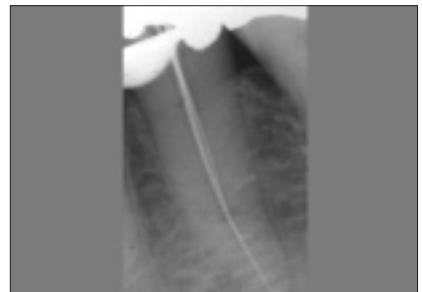


Figure 6: A precurved #10 file is slipped into the apical accessory canal after the main canal has been cleaned and shaped. The #20 file is in the main canal.

motion is used until the #10 file feels very loose in the canal space. The next larger size of instrument is then introduced. If the apical opening of the canal is extremely small and the final apical canal very tortuous, the #10 file can “peek” through the root surface delicately to maintain apical patency.

During the cleaning and shaping procedure, copious irrigation (at least 30 mL per canal) is needed. The irrigant (preferably sodium hypochlorite 2.5%) should be constantly replenished, and the fine file helps to bring it into the apical ramification. The sodium hypochlorite digests and dissolves the necrotic pulp tissues, and also disperses the dentin mud into a loose suspension. A chelating agent should not be used, because it could soften and decalcify the dentinal wall; in this situation, a false path is easily created, particularly if the operator digs into the canal wall tangentially where the main path is blocked and compacted with dentin mud.

The cleaned, well-shaped, smooth, patent canals can easily be fitted with gutta-percha and hermetically packed 3-dimensionally with a sealer. ♦



Dr. Donald Yu is a clinical professor and director of endodontics, department of Dentistry, University of Alberta, Edmonton, Alberta. E-mail: donaldyu@ualberta.ca.

Dr. Yu's pre-congress hands-on lecture at the FDI meeting, titled “Predictably successful endodontics: how to feel, fill & thrill accessory canals,” will be presented on Monday, August 22.

References

1. Yu DC. The significance of obturating the accessory canals in the healing of the lesions of endodontic origin. *Hong Kong Dental Association Newsletter* March 1998; 7–10.
2. Schilder H. Filling root canals in three dimensions. *Dent Clin North Am* 1967; Nov:723–44.

Further Reading

- Schilder H. Cleaning and shaping the root canal. *Dent Clin North Am* 1974; 18(2):269–96.
- Yu DC, Schilder H. Cleaning and shaping the apical third of a root canal system. *Gen Dent* 2001; 49(3):266–70.

Question 4 What steps should be taken to ensure compliance with infection control measures in a dental practice?

Background

The development and general acceptance of effective practices and protocols have substantially reduced the risks of infection for health care professionals and patients alike.¹⁻³ Yet despite the substantial evidence reinforcing the protective benefits of routine precautions, lack of compliance continues to be a problem for some dental and medical health care workers. The following discussion outlines appropriate actions following needle-stick injury during treatment and the importance of advance planning to manage such incidents. Although not specifically discussed here, similar incidents may occur during handling of other types of sharp, contaminated instruments, such as non-hollow-bore instruments (e.g., scalers, probes, burs and wires), contaminated instruments being cleaned for reuse, or materials sent from dental offices for processing in a dental laboratory.

Hypothetical Incident

Consider the following hypothetical scenario. A dentist who graduated from dental school in the late 1970s has kept abreast of developments in infection control and takes pride in the precautions taken by his clinical staff. The dental practice is located in a suburban community, and only a few patients have noted HIV/AIDS or viral hepatitis in their history. Two of the dental hygienists and assistants are hesitant to treat these patients unless extra barrier precautions are used and contaminated instruments are processed separately in the ultrasonic unit, followed by a routine heat sterilization cycle. Discussions concerning accidental exposure to sharps have been infrequent during office meetings for 2 main reasons: the additional precautions noted above are used during treatment of any patient with a high-risk type of infection and no accidental sharps exposures have been recorded for several years. As a result, personnel who provide patient care feel comfortable that their infection control routine is working smoothly.

During one of the practice's busier Friday afternoons, a long-standing adult patient requires a second injection of anesthetic during a crown preparation. In a hurried attempt to complete this routine procedure, the dental assistant is accidentally stuck with the needle while recapping the syringe passed to her by the dentist (Fig. 1). Unsure of what to say, she does not inform the dentist until the treatment has been completed.

How the dentist and the assistant deal with this situation will be important both in terms of potential spread of infectious disease and from a psychological perspective (in terms of the occurrence of a traumatic incident). Their responses

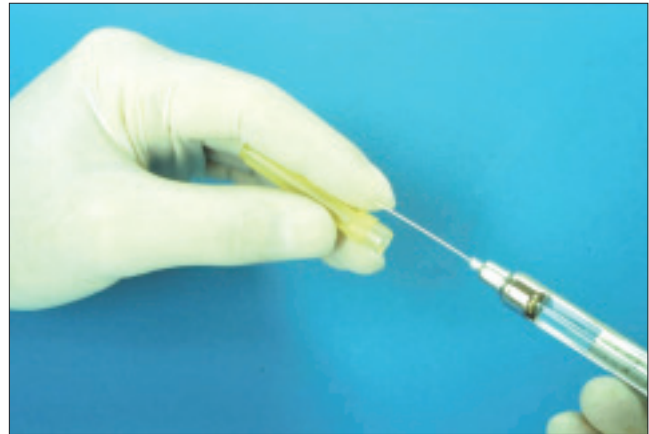

Figure 1: Two-handed needle recapping: an accident waiting to happen.

will also affect how others in the practice deal with and report future incidents of this nature.

What Should Be Done

Accidental exposures to blood or other body fluids should be treated as medical emergencies and addressed immediately after they occur. A comprehensive, written postexposure management protocol allows personnel to be prepared in advance, rather than simply reacting to what could easily become an emotional situation. Advance preparation and appropriate action after an incident can minimize potential problems (see Fig. 2, Flow chart for management of occupational exposures to bloodborne pathogens at <http://www.cda-adc.ca/jcda/vol-71/issue-5/341.html>).⁴ When an accidental exposure occurs, the following steps should be taken:

1. Perform basic first aid to clean the wounded area. Washing the hands with soap and water is satisfactory for cleaning affected skin sites, whereas injured mucous membrane tissues may be flushed with water.
2. Report the injury to the employer or the infection control coordinator, providing as much information as possible. A written exposure report can greatly assist the trained health professionals who will be evaluating the exposure and recommending follow-up.
3. Follow instructions for appropriate medical evaluation and follow-up care.

Several factors should be considered when evaluating an exposure incident⁵ (Fig. 2):

- where the incident occurred (the physical space within the facility)
- the circumstances under which the exposure occurred

- engineering controls and work practices in place at the time of the exposure, including use of a safety device
- policies in place at the time of the incident
- type of exposure and severity of the injury
- any available information about the source patient
- presence or absence of visible blood on the device.

In the hypothetical scenario described above, the existence of a postexposure management plan would allow both the dentist and the injured assistant to provide pertinent information to medical evaluators. Such information would be useful for determining whether there is a risk of transmission of a bloodborne infection (e.g., hepatitis B virus, hepatitis C virus or HIV) and hence the need for postexposure prophylaxis, as well as the serological testing and counselling that should be provided for the injured health care worker. Conversely, the absence of a plan can cause a ripple effect, simply because routine tasks may not be performed in the recommended fashion. As a result, a door may be unknowingly opened to an increased risk of microbial infection. ♦



Dr. John A. Molinari is professor and chair, department of biomedical sciences, University of Detroit Mercy School of Dentistry, Detroit, Michigan. E-mail: [molinja@udmercy.edu](mailto:molinaja@udmercy.edu).

Dr. Molinari's session at the FDI meeting, titled "Emerging infection — challenges and recommendations," will be presented on Tuesday, August 23, as part of the pre-congress courses.

References

1. Molinari JA. Dental infection control at the year 2000: accomplishment recognized. *J Am Dent Assoc* 1999; 130(9):1291–8.
2. Siew C, Chang SB, Gruninger SE, Verrusio AC, Neidle EA. Self-reported percutaneous injuries in dentists: implications for HBV, HIV transmission risk. *J Am Dent Assoc* 1992; 123(7):36–44.
3. Cleveland JL, Lockwood SA, Gooch BF, Mendelson MH, Chamberland ME, Valauri DV, and others. Percutaneous injuries in dentistry: an observational study. *J Am Dent Assoc* 1995; 126(6):745–51.
4. Organization for Safety and Asepsis Procedures (OSAP). From policy to practice: OSAP's guide to the guidelines. OSAP: Annapolis; 2004.
5. Bednarsh H, Eklund KJ, Molinari JA, Bond WW. Infection control and hazard control. In: Sonis ST, editor. *Dental secrets*. 3rd ed. Philadelphia: Hanley & Belfus; 2003.

Figure 2 Flow chart for management of occupational exposures to bloodborne pathogens (reprinted with permission from the Organization for Safety and Asepsis Procedures).⁴

