

# Clinical Showcase

*Clinical Showcase is a series of pictorial essays that focus on the technical art of clinical dentistry. The section features step-by-step case demonstrations of clinical problems encountered in dental practice. This month's article is by Dr. Robert David, a speaker at the FDI World Dental Congress, which will be held August 24 to 27 in Montreal, Quebec (pre-Congress courses will take place August 22 and 23). For more information on the Congress, visit [www.fdiworldental.org](http://www.fdiworldental.org).*



## Retro Fabrication of a Cast Post and Core to an Existing Crown

Robert David, DDS

Fabrication of a post and core beneath an existing crown is often necessary to re-establish resistance and retention after breakdown of the underlying abutment tooth. Several options are available, including a prefabricated post with an added core or a custom-made one-piece cast post and core. In some cases, the abutment tooth may not be suitable for a prefabricated post and core because the ovoid canal is very large or because the remaining dentin is inadequate to securely bond or retain the core material. These cases are best treated with a one-piece cast post and core. If the existing crown does not provide adequate ferrule to brace the remaining tooth structure in order to minimize the risk of root fracture, the crown and the bridgework should be remade.

### Techniques for Retrofitting Cast Post and Core

The following methods can be used to fabricate a cast post and core beneath an existing restoration:

- Indirect technique on a model in the laboratory; requires that the patient go without the restoration while the post is being fabricated.
- Direct intraoral technique using self-curing acrylic; separating the set acrylic pattern from the crown is challenging, and an occlusal opening is often required to push the post and core out of the crown, which may compromise the crown.

The author's preferred procedure for retrofitting a cast post and core is a modified intraoral method with self-curing acrylic. The coefficient of thermal expansion and contraction of the acrylic exceeds that of the crown materials, which allows for easy separation of the precisely fitting acrylic post and core pattern from the crown without damaging the existing crown with an occlusal opening.

### Clinical Report

A 50-year-old patient presented with a 3-unit fixed bridge that had been placed by her dentist 4 years before. Full crowns were present on teeth 43 and 44, and a cantilever pontic replaced tooth 45. A hairline fracture was evident in the porcelain on the crown of tooth 44 (Fig. 1). Upon examination, it was noted that the crown on tooth 43 was loose; however, the bridge was comfortable and stable. Endodontic therapy had been performed on tooth 43 before bridge cementation and

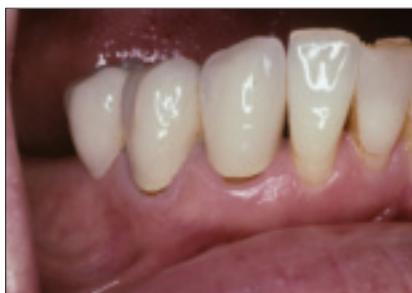on tooth 44 (through an occlusal opening in the crown) after bridge cementation (Fig. 2).

The bridge was removed using a Higa bridge remover (Higa Manufacturing Limited, West Vancouver, B.C.) (Fig. 3). The coronal two-thirds of tooth 43 had fractured, causing loss of retention and eventual loosening of the crown (Fig. 4). The fractured fragment of tooth 43, which was rigidly attached to the crown, was removed, and the internal aspect of the crown was smoothed. Tooth 43 had a periapical radiolucency and required endodontic retreatment before fabrication of the post (Fig. 5).

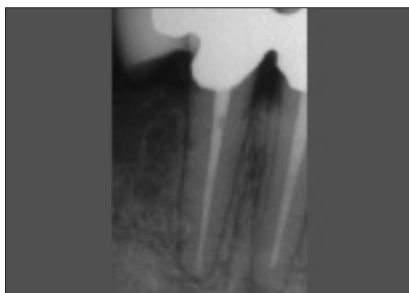The full crown on tooth 43 had a 2-mm ferrule bracing the root; however, the coronal dentin was inadequate to securely retain core material, which precluded use of a preformed post. Therefore, a retrofitted cast post and core was fabricated intraorally.

A post space was created by removing the endodontic gutta-percha to within 8 mm from the apex by means of a non-end-cutting Peeso reamer (Endotec Inc, Mani Instruments, Halifax, N.S.) which had been marked with a rubber stopper (Fig. 6). The post space was lubricated with Microfilm (Kerr Manufacturing, Orange, Calif.) applied with a disposable Ultrabrush (Microbrush Corporation, Grafton, Wisc.) (Fig. 7). A powder and liquid brush technique was used to fill the post space with red Duralay self-curing acrylic (Reliance Dental Manufacturing, Worth, Ill.) (Figs. 8a and 8b), and a periodontal probe was used to pump the soft acrylic apically to the base of the post preparation (Fig. 9). A small Spee-Dee preformed acrylic tapered pin (Pulpdent Corporation of America, Watertown, Mass.), wetted with acrylic monomer, was inserted into the apical end of the unset acrylic (Fig. 10). A small acrylic core was then built up around the pin. With the acrylic partially set, yet still flexible, the acrylic post was withdrawn approximately 1–2 mm and then fully reseated several times to prevent it from sticking in the post space. After the acrylic had set completely, the post pattern was removed from the tooth and verified for accuracy (Fig. 11). The acrylic pattern was then replaced into the post space, and the pin and core were reduced (Fig. 12), which made them much smaller than the former tooth preparation; this allowed for complete seating of the bridge. Complete, unimpeded seating of the bridge over the acrylic pattern was verified, and the margins and occlusion were checked for accuracy (Fig. 13).

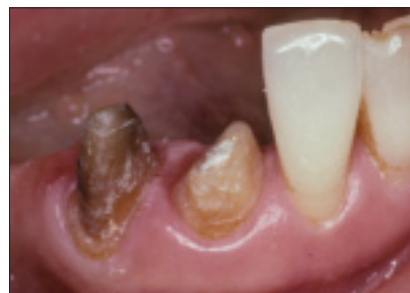## Clinical Showcase



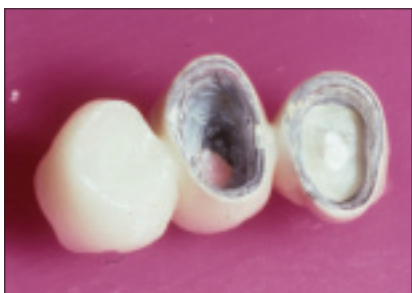**Figure 1:** Cantilever bridge with a loose crown on tooth 43. A porcelain fracture is evident on the distal buccal surface of crown 44.



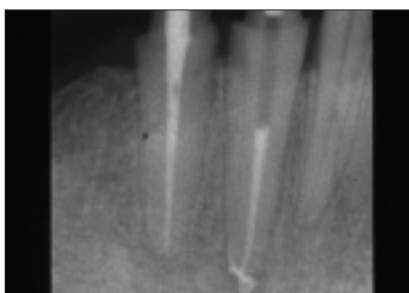
**Figure 2:** Endodontic therapy was performed on tooth 43 before bridge cementation and on tooth 44 after bridge cementation (through an occlusal access opening). Tooth 43 exhibits an apical radiolucency.



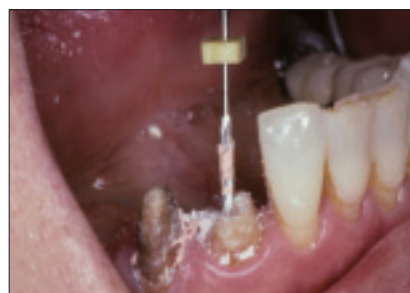**Figure 3:** Bridge has been removed.



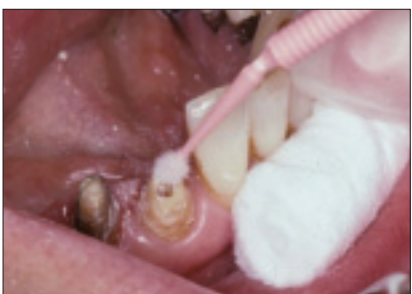**Figure 4:** Occlusal half of the abutment tooth 43 is fractured, which has caused the crown to lose its retention and loosen.



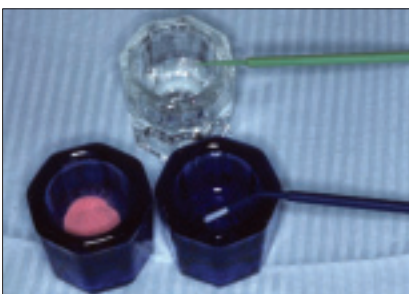
**Figure 5:** Endodontic retreatment on tooth 43 before fabrication of the post.



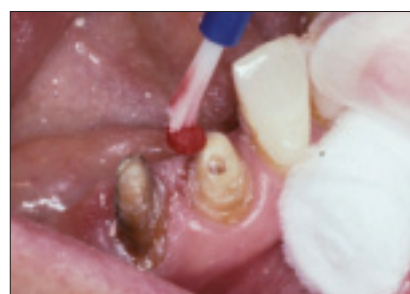
**Figure 6:** Post space is prepared with a non-end cutting Peeso reamer.



**Figure 7:** The post space is lubricated with Microfilm.



**Figure 8a:** Red Duralay self-curing acrylic will be used to fill the prepared post space.



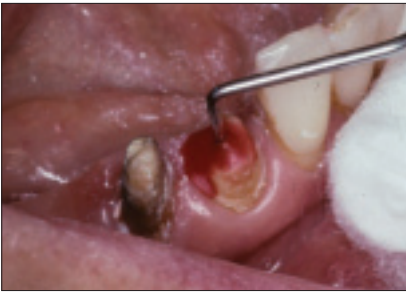
**Figure 8b:** A powder and liquid brush technique is used to apply the Duralay.

The dentin and the undersurface of crown 43 were lightly lubricated with Microfilm (Fig. 14a), and a brush technique was used to fill the crown with Duralay acrylic (Fig. 14b). The bridge, with unset acrylic, was then placed over the teeth with the acrylic post pattern seated in the post preparation. Full seating of the bridge was verified before polymerization. The teeth were held firmly in centric occlusion until the acrylic had set completely (Fig. 15). The bridge, with the set acrylic post and core, was removed from the teeth. The post and core were firmly attached to the undersurface of crown 43 and had to be separated from the crown without damaging the crown or the post (Fig. 16).

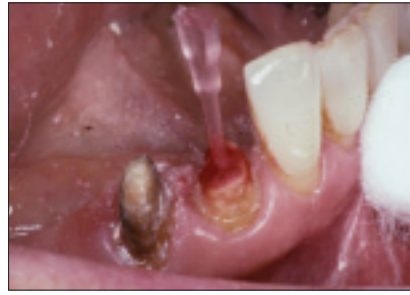The coefficient of thermal expansion and contraction of the acrylic post is greater than that of the crown materials.

This physical property was used to permit easy separation of the acrylic post and core pattern from the crown without endangering the acrylic pattern or the crown.

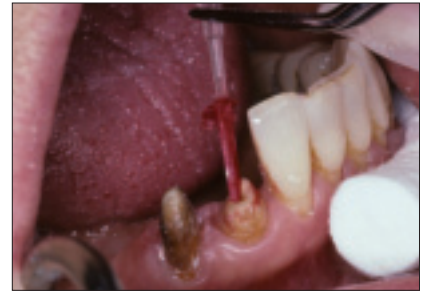
A rubber bowl was filled with cold water and ice cubes, and 2 tablespoons (30 mL) of salt were added to lower the water temperature below the freezing point (Fig. 17). The bridge and the attached post and core were placed into the cold water and left for 20 minutes. The contraction of the acrylic post and core was greater than that of the bridge structure; as a result, the post and core were easily withdrawn from the crown (Fig. 18). The acrylic pattern and the bridge were reverified on the teeth, after which the pattern was sprued to a flat surface of the core and cast in gold. During the laboratory phase of this procedure the bridge was temporarily recemented.



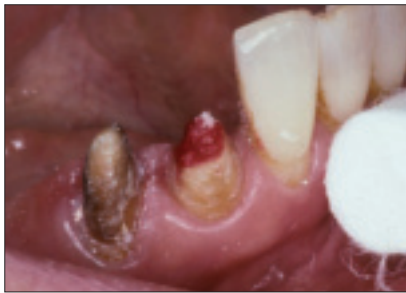**Figure 9:** A periodontal probe is used to pump the unset acrylic into the post preparation.



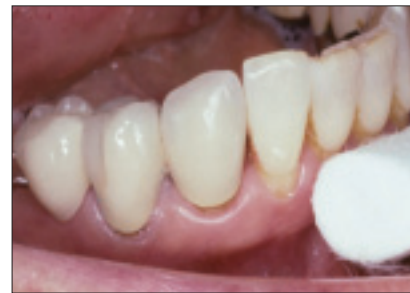**Figure 10:** A Spee-Dee acrylic tapered pin wetted with monomer is inserted into the apical end of the post preparation.



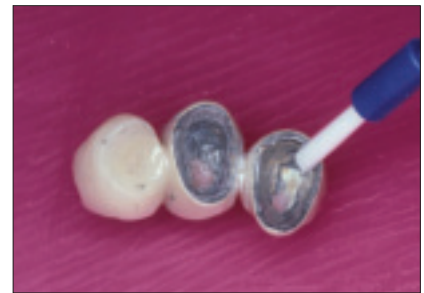**Figure 11:** The set acrylic post with a small core is removed from the preparation.



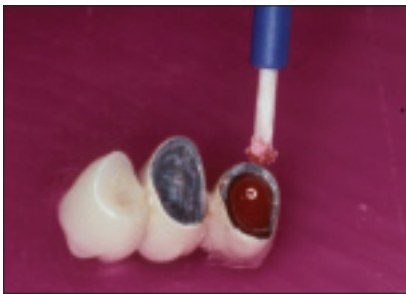
**Figure 12:** The set acrylic post and core are reduced and adjusted to allow complete seating of the bridge.



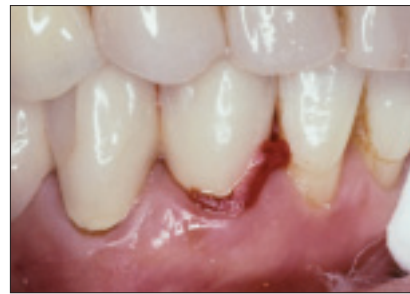**Figure 13:** Full seating of the bridge is verified.



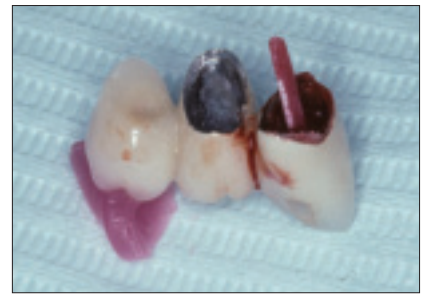**Figure 14a:** The crown is lubricated with Microfilm.



**Figure 14b:** The crown is then filled with red Duralay acrylic using a powder and liquid brush technique.



**Figure 15:** With the set post and small core seated into the post preparation, the bridge, with unset acrylic, is fully seated onto the teeth and allowed to set with the teeth in occlusion.



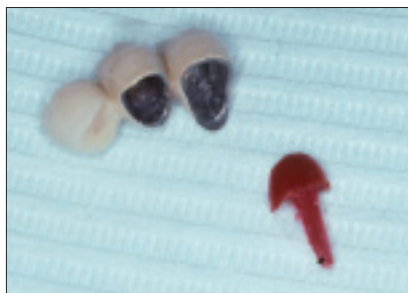**Figure 16:** The set acrylic post and core pattern are firmly attached to the crown of tooth 43.

The cast gold post and core were verified under magnification for irregularities, and excess gold in the sprued area was removed. Most adjustments to an uncemented gold post and core should be made off the tooth, to avoid vibration and heat generation, which could endanger the fragile root. If adjustments are made to the post and core intraorally, copious irrigation should be used to prevent heating and expansion of the gold. Expansion of the precisely fitting gold post could induce micro-fractures in the root. After complete verification and adjustments, the post was placed into the post preparation with gentle finger pressure and verified for complete seating (Fig. 19). The bridge was then inserted and verified.

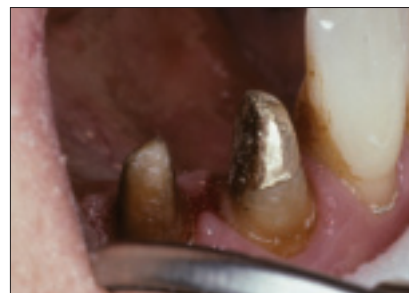Before cementation, the post preparation in the root, the post portion of the casting and the undersurface of the crown were sandblasted, and the core portion of the casting was polished (Fig. 20). The post preparation was then irrigated with 0.12% chlorhexidine and dried with paper points. The cast post and core and the bridge were then cemented simultaneously with a glass ionomer cement and verified (Fig. 21). One year after the retro fabrication of the cast post and core, a radiograph indicates that the 5-year-old bridge has regained its retention and resistance and is now stable and functional (Fig. 22).



**Figure 17:** The bridge and attached post and core are placed into a water, ice and salt bath for 20 minutes.



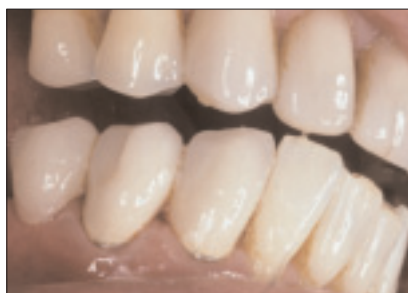**Figure 18:** Cooling of the acrylic post and core has caused its shrinkage and easy separation from the crown.



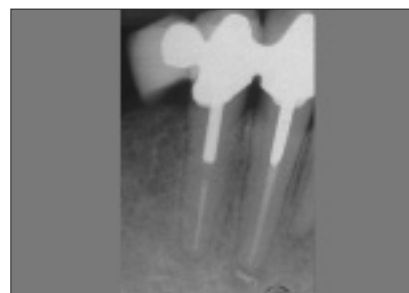**Figure 19:** The adjusted gold post and core is gently seated into the tooth and verified.



**Figure 20:** The post is sandblasted and the core is polished.



**Figure 21:** The post and bridge are cemented simultaneously.



**Figure 22:** One year after treatment, the radiograph indicates that the retrofitted post and core on tooth 43 provides retention and resistance for the 5-year-old bridge.

## Conclusions

Precise retrofitting of a cast post and core was performed without altering or endangering the existing bridge by using basic principles of physics. This same effect may be achieved by using a freezer rather than water, ice and salt. ❖



*Dr. David is an associate professor at McGill University. He practices restorative and implant dentistry in Montreal, Quebec. He has no declared financial interests in any company manufacturing the types of products mentioned in this article.*

**Correspondence to:** Dr. Robert David, 1414 Drummond Street, Suite #626, Montreal QC H3G 1W1. E-mail: [bobbydavid@sympatico.ca](mailto:bobbydavid@sympatico.ca).

*Dr. David and Dr. Frederic Muroff will be presenting all an-day course at the FDI meeting. Titled "A team approach to periodontal, implant and restorative procedures for anterior esthetics," the course will be offered on Thursday, August 25.*

## Further Reading

- Cristecu RC, Naicu IV. A radiographic study regarding the negative effects of posts. *Oral Health* 2005; 95(3):87–96.
- Goodacre CJ, Spolnick KJ. The prosthodontic management of endodontically treated teeth; a literature review. Part I. Success and failure data, treatment concepts. *J Prosthodont* 1994; 3(4):243–50.
- Hunter AJ, Feiglin B, Williams JF. The effects of post placement on endodontically treated teeth. *J Prosthet Dent* 1989; 62(2):166–72.
- Hudis SI, Goldstein GR. Restoration of endodontically treated teeth: a review of the literature. *J Prosthet Dent* 1986; 55(1):33–8
- Johnson ME, Stewart GP, Nielsen CJ, Hatton JF. Evaluation of root reinforcement of endodontically treated teeth. *Oral Surg Oral Med Oral Pathol Oral Radiol Endod* 2000; 90(3):360–4.