

Forced Orthodontic Eruption of Fractured Teeth before Implant Placement: Case Report

• Leandro Chambrone, DDS •
• Luiz A. Chambrone, PhD, MSD, DDS •

A b s t r a c t

The treatment of esthetic areas with single-tooth implants represents a new challenge for the clinician. Placement of a single-unit implant is indicated for fractured or periodontally compromised teeth. In 1993, a modification of the forced eruption technique, called "orthodontic extrusive remodelling," was proposed as a way to augment both soft- and hard-tissue profiles at potential implant sites. This case report describes augmentation of the coronal soft and hard tissues around a fractured tooth, which was achieved by forced orthodontic extrusion before implant placement. This technique may be used to improve primary anchorage of a dental implant, fill the alveolar socket with bone, preserve interdental bone height and increase the amount of attached gingiva.

MeSH Key Words: alveolar bone loss; dental implantation, endosseous/methods; tooth movement/methods

© J Can Dent Assoc 2005; 71(4):257-61
This article has been peer reviewed.

The treatment of esthetic areas with single-tooth implants represents a new challenge for the clinician. The primary goals of such restorations include successful osseointegration of the dental implant, harmony between the final restoration and the adjacent teeth, and the health of the surrounding soft and hard tissues.¹

To evaluate an implant site in an esthetic area, 4 factors should be considered: smile line, soft-tissue morphology, tooth morphology and osseous architecture.² A single-tooth site can present as great an esthetic challenge as an extensive alveolar ridge defect, especially in anterior areas.³

Placement of a single-unit implant is indicated for fractured or periodontally compromised teeth. However, these sites can be deficient in gingiva and alveolar bone in the horizontal or vertical planes (or both).

Various surgical procedures have been developed to preserve or reconstruct the alveolar ridge, such as distraction osteogenesis,⁴ guided tissue regeneration⁵ and graft procedures.⁶ These techniques are available to treat the ridge defect either at the time of extraction or at a later date.

Another approach to soft- and hard-tissue augmentation is forced orthodontic eruption (FOE). As first described by Heithersay⁷ and Ingber,⁸ this technique is based on osteo-physiologic and orthodontic principles.⁹ It has been used

frequently because of its demonstrated advantages, including correction of isolated infrabony defects, repositioning of the gingival margin and clinical lengthening of the crown.⁷⁻¹²

Moreover, this technique can be used to change the root position, providing space and anchorage for an implant. In 1993, Salama and Salama¹³ proposed a modification of the forced eruption technique. This new approach, termed "orthodontic extrusive remodelling," was used to augment both soft- and hard-tissue profiles of potential implant sites, by forced orthodontic extrusion of "hopeless" teeth and their periodontal apparatus.¹³

Periodontally compromised teeth without endodontic periapical lesions can be orthodontically extruded to develop the gingiva and bone in a coronal direction before implant placement.¹³⁻¹⁷ Such vertical augmentation, especially for the buccal bone plate and crest, allows better implant placement in relation to the cemento-enamel junction of the adjacent dentition (within 1 to 3 mm apically, depending on implant type).¹⁶ This additional bone and gingiva enhances the site for a more esthetically pleasing final restoration.¹⁷

This case report describes coronal soft- and hard-tissue augmentation around a fractured tooth, which was achieved by FOE before implant placement.

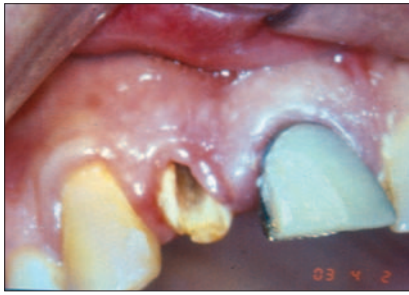

Figure 1: Pretreatment frontal view of the vertical fracture on the root of the maxillary right lateral incisor.

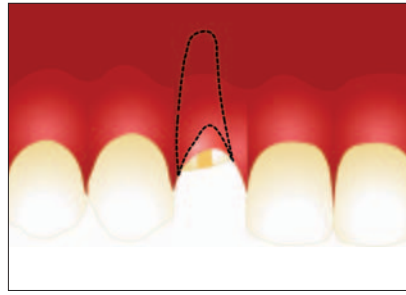


Figure 2: Diagrammatic representation of pretreatment frontal view.

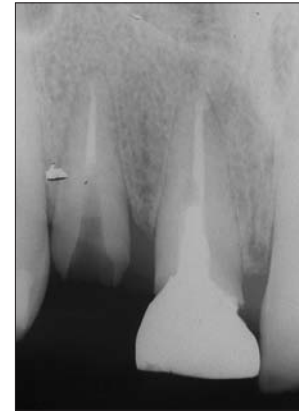

Figure 3: Radiograph of maxillary right lateral incisor before treatment.

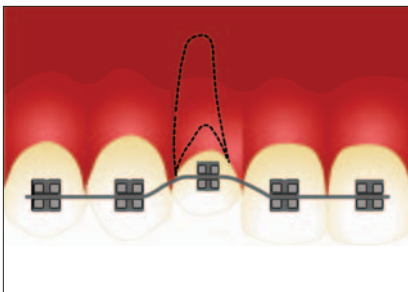


Figure 4: Diagrammatic representation of 0.016-inch nickel-titanium arch wire (first arch).

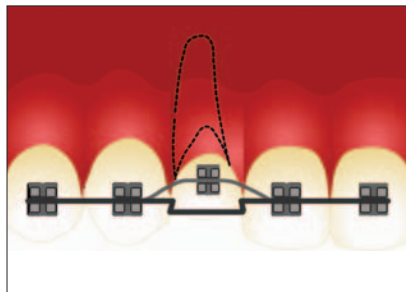


Figure 5: Diagrammatic representation of 0.019 x 0.025 inch stainless steel auxiliary arch (second arch).

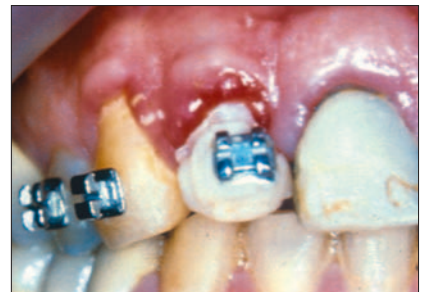

Figure 6: Frontal view during stabilization phase.

Case Report

A healthy 48-year-old man (a nonsmoker) was referred to the authors' private dental office with symptoms of tooth fracture on the maxillary right lateral incisor. His dental history included a cast-gold core and post with a metal-ceramic crown on this tooth. Clinical examination revealed a vertical fracture on the buccal root portion (Figs. 1 and 2). Vertical probing depth in the area was 4 mm. Radiographic examination revealed the extension of the root fracture and the level of the alveolar crest (Fig. 3). Crown-lengthening procedures were contraindicated because of the impossibility of obtaining an adequate crown-to-root ratio, and it was decided that the remaining root should be replaced by a dental implant.

To prevent ridge resorption and to increase the amount of soft tissue and bone before implant placement, the tooth was orthodontically extruded by FOE as described by Salama and Salama.¹³ Orthodontic treatment was initiated in the upper arch with passive bonding (in the same horizontal plane) of 0.022-inch edgewise brackets from the first right bicuspid to the left central incisor, and a 0.016-inch nickel-titanium arch wire was placed (Fig. 4). A metallic post was placed inside the fractured root, and the tooth was provisionally

restored. The brackets on the right lateral incisor were positioned more apically, at the location of the cemento-enamel junction, to provide an extrusive component (approximately 50 g of force). To avoid intrusion of the anchorage teeth, a 0.019 inch x 0.025 inch stainless steel auxiliary arch was used to stabilize the segmented wire (Fig. 5).

The patient was seen every 2 weeks, for reduction of the incisal surface of the extruded tooth and repositioning of the lateral incisor bracket more apically along the root surface. After 10 weeks, the segmented arch had stabilized. This eruptive phase was followed by 10 weeks of stabilization (Figs. 6 and 7).

Before extraction of the maxillary right lateral incisor, it was observed that the remaining root was no longer located inside the alveolus. Radiographic assessment revealed improvement in the vertical bone of this area (Fig. 8). The implant was placed at the time of tooth extraction (3.75 mm x 11 mm implant, Osseotite, 3i, Palm Beach Gardens, Fla.) and remained unloaded for 6 months (Fig. 9). The final restorations for the implant and the maxillary central incisor, which received a new metal-ceramic crown, were placed (Figs. 10 to 12). The FOE therapy yielded an increase in the zone of attached gingiva

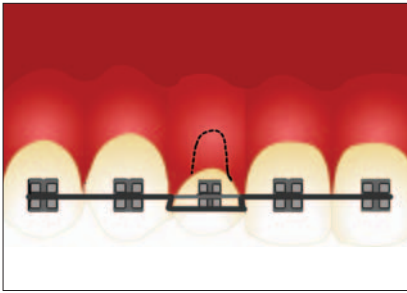


Figure 7: Diagrammatic representation of stabilization phase.

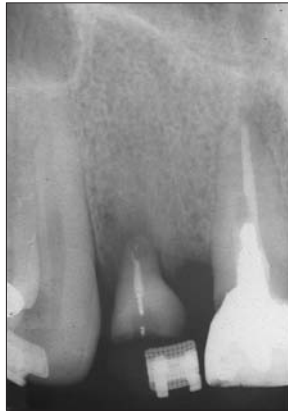

Figure 8: Improvement in the vertical bone before implant placement.

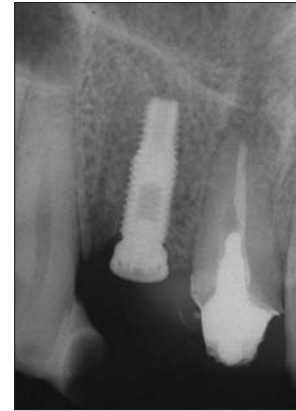

Figure 9: Radiographic assessment 6 months after implant placement.

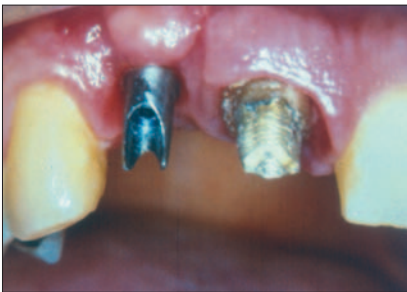

Figure 10: Clinical aspect of gingival tissues.

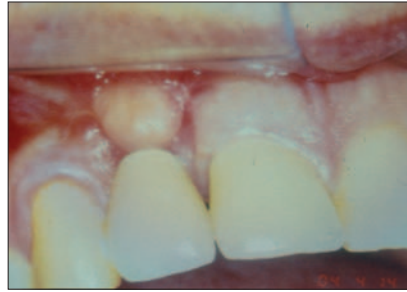


Figure 11: Finished restorations with a satisfactory esthetic result.

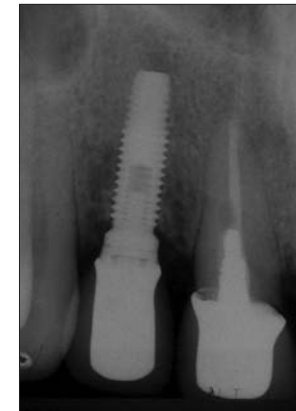

Figure 12: Radiograph after placement of final restorations.

and a satisfactory emergence profile for the dental implant. The patient experienced esthetic benefit from this approach.

Discussion

Usually, the placement of dental implants in esthetic areas is linked to the smile line, hard- and soft-tissue anatomy, and tooth morphology.² In this case, a multidisciplinary approach was used to treat a fractured tooth. FOE was performed first, to preserve the esthetic appearance of the area, to avoid ridge collapse after extraction and to improve the 3-dimensional topography of the recipient site (soft-tissue morphology and osseous architecture), followed by tooth extraction and implant placement. After the initial FOE therapy, the osseous alveolar crest and the gingival margin were located in normal relation to the tissues of the contiguous teeth.

This technique was first described for periodontally compromised teeth as a means of enhancing the soft- and hard-tissue dimensions of potential implant sites.¹³ Mantzikos and Shamus¹⁵ termed this procedure “orthodontic extraction,” whereas Salama and Salama¹³ called it “ortho-

dontic extrusive remodelling.” The authors of the present report prefer the term “forced orthodontic extrusion.”

Tooth extractions in the anterior maxillary areas generally cause simultaneous deficiencies of the alveolar ridge.^{18,19} In isolated sites before implant placement, this procedure can create a greater volume of alveolar bone and soft tissue in the vertical and horizontal planes, without surgical intervention.^{2,13–16,20} By stretching the gingival and periodontal ligament fibres during FOE, tension is imparted to the entire alveolar socket, stimulating osseous apposition at the alveolar crest.² The orthodontic extraction increases the width of the attached gingiva, and the mucogingival junction remains stable when the gingival margin migrates coronally.^{2,13–16,20}

With FOE the diameter of the remaining alveolus is smaller, and an endosseous dental implant can usually be placed to fill the remaining alveolus at the time of root extraction.¹⁷ The most important benefit is the creation of a greater volume of bone to engage the implant at the time of extraction.¹³ In addition, the creation of more intimate contact between the implant surface and the adjacent alveolar bone can result in greater initial implant stability and possibly earlier osseointegration over a large

surface area.¹³ Furthermore, this technique allows placement of the implant head 3 mm apical to the level of the cemento-enamel junction of the adjacent natural tooth and hence allows an adequate emergence profile.³

For teeth that have been fractured below the level of the crestal bone, FOE often yields results that could not be obtained by surgical crown-lengthening procedures, guided tissue regeneration or bone graft procedures, especially when there is not enough soft tissue to allow the use of membranes or osseous grafts. Mantzikos and Shamus¹⁴ demonstrated that when a periodontally compromised tooth is erupted, some changes can be observed in the surrounding gingiva. First, teeth that are extruded in the presence of periodontal pockets seem to move coronally before the gingival margin follows. Consequently, pocket depth is reduced, and an immature tissue (the "red patch") appears coronal to the original gingival margin. This sulcular epithelium appears to be induced to peel away from the tooth, through inversion of the pocket lining. After 28 days, keratinization of the everted epithelium occurs.¹⁴

FOE before implant placement is a further procedure to cope with isolated nonrestorable teeth in esthetic sites. It contributes to the emergence profile of the dental implant and the final restoration by increasing tissue depth (as measured from the alveolar bone crest to the seating surface of the implant), improving implant angulation and torque placement in relation to adjacent natural teeth, and improving the interarch distance.²¹

However, the relationships between tooth, gingival unit, attachment apparatus, applied force and consequent stress must be considered when forced eruption is used.⁹ During the FOE procedure, the root may be moved laterally, which could affect the position of teeth in the arch.²² This movement may compromise prosthodontic treatment, or it may be used to esthetically enhance such treatment.²² In the case reported here, a secondary arch was placed to avoid intrusion of the contiguous teeth. (The secondary arch can also be used to avoid intrusion of the contiguous teeth in cases of deep overbites.) This technique also enabled proper implant placement in a situation where the bone was compromised.^{13-16,20}

This type of orthodontic treatment is a form of adjunctive tooth movement.²³ Adjunctive tooth movement can be used to achieve better distribution of teeth before restorative procedures, to allow for proper tooth preparation and parallel abutments, to create pontic spaces, to correct mucogingival and osseous defects, to improve the crown-to-root ratio, to close open contacts, to upright severely tipped teeth and to re-establish adequate occlusion.²³ Manipulation of the attachment apparatus through tooth movement offers the potential to improve the implant site and, consequently, to optimize the treatment and the final result.¹³

Combined with guided tissue regeneration and bone graft procedures, this technique may result in more predictable implant placement in sites with buccal osseous dehiscence.^{13-16,20}

Teeth with root fractures or advanced caries cannot offer sound root structure on which to place a restoration. In such situations, this technique may be used to improve the primary anchorage of a dental implant, fill the alveolar socket with bone, preserve the interdental bone heights and increase the amount of attached gingiva.

In the case reported here, the fractured root was extruded over the course of 10 weeks, and 10 weeks of stabilization followed. Other authors have proposed different protocols.^{13-16,20} In conclusion, the combination of FOE and single-implant placement in the treatment of fractured teeth seems advantageous, especially in maxillary esthetic areas. ♦



Dr. L. Chambrone is volunteer assistant professor, discipline of periodontics, faculty of dentistry, Methodist University of São Paulo (UMESP), São Bernardo do Campo, Brazil, and is in private practice in orthodontics and periodontics. He is a specialist in orthodontics and dentofacial orthopedics.



Dr. L. A. Chambrone is professor and chair, discipline of periodontics, faculty of dentistry, Methodist University of São Paulo (UMESP), São Bernardo do Campo, Brazil.

Correspondence to: Dr. Leandro Chambrone, Rua Cristianópolis, 220 São Paulo SP, 03128-030 Brasil. E-mail: chambras@bol.com.br.

The authors have no declared financial interests in any company manufacturing the types of products mentioned in this article.

References

- Phillips K, Kois JC. Aesthetic peri-implant site development. The restorative connection. *Dent Clin North Am* 1998; 42(1):57-70.
- Schincaglia GP, Nowzari H. Surgical treatment planning for the single-unit implant in aesthetic areas. *Periodontol 2000* 2001; 27:162-82.
- Palmer RM, Palmer PJ, Newton JT. Dealing with esthetic demands in the anterior maxilla. *Periodontol 2000* 2003; 33:105-18.
- Chin M, Toth B. Distraction osteogenesis in maxillofacial surgery using internal devices: report of five cases. *J Oral maxillofac Surg* 1996; 54(1):45-53.
- Hämmerle CH, Jung RE. Bone augmentation by means of barrier membranes. *Periodontol 2000* 2003; 33:36-53.
- van Seenberghe D, Naert I, Bossuyt M, De Mars G, Calberson L, Ghyselen J, and other. The rehabilitation of the severely resorbed maxilla by simultaneous placement of autogenous bone grafts and implants: a 10-year evaluation. *Clin Oral Invest* 1997; 1(3):102-8.
- Heithersay GS. Combined endodontic-orthodontic treatment of transverse root fractures in the region of the alveolar crest. *Oral Surg Oral Med Oral Pathol* 1973; 36(3):404-15.
- Ingber JS. Forced eruption. I. A method of treating isolated one and two wall infrabony osseous defects — rationale and case report. *J Periodontol* 1974; 45(4):199-206.
- Potashnick SR, Rosenberg ES. Forced eruption: principles in periodontics and restorative dentistry. *J Prosthet Dent* 1982; 48(2):141-8.
- Ingber JS. Forced eruption: part II. A method of treating nonrestorable teeth — periodontal and restorative considerations. *J Periodontol* 1976; 47(4):203-16.

11. Ingber JS. Forced eruption: alteration of soft tissue cosmetic deformities. *Int J Periodontics Restorative Dent* 1989; 9(6):416–25.
12. Johnson GK, Sivers JE. Forced eruption in crown-lengthening procedures. *J Prosthet Dent* 1986; 56(4):424–7.
13. Salama H, Salama M. The role of orthodontic extrusive remodeling in the enhancement of soft and hard tissue profiles prior to implant placement: a systematic approach to the management of extraction site defects. *Int J Periodontics Restorative Dent* 1993; 13(4):312–33.
14. Mantzikos T, Shamus I. Forced eruption and implant site development: soft tissue response. *Am J Orthod Dentofac Orthop* 1997; 112(6):596–606.
15. Mantzikos T, Shamus I. Case report: forced eruption and implant site development. *Angle Orthod* 1998; 68(2):179–86.
16. Mantzikos T, Shamus I. Forced eruption and implant site development: an osteophysiologic response. *Am J Orthod Dentofacial Orthop* 1999; 115(5):583–91.
17. O'Neal RB, Butler BL. Restoration or implant placement: a growing treatment planning quandary. *Periodontol 2000* 2002; 30:111–22.
18. Abrams H, Koczyk RA, Kaplan AL. Incidence of anterior ridge deformities in partially edentulous patients. *J Prosthet Dent* 1987; 57(2):191–4.
19. Hawkins CH, Sterrett JD, Murphy HJ, Thomas JC. Ridge contour related to esthetics and function. *J Prosthet Dent* 1991; 66(2):165–8.
20. Nozawa T, Sugiyama T, Yamaguchi S, Ramos T, Komatsu S, Enomoto H, and other. Buccal and coronal bone augmentation using forced eruption and buccal root torque: a case report. *Int J Periodontics Restorative Dent* 2003; 23(6):585–91.
21. Garber DA. The esthetic dental implant: letting restoration be the guide. *J Am Dent Assoc* 1995; 126(3):319–25.
22. Vanarsdall RL. Orthodontics and periodontal therapy. *Periodontol 2000* 1995; 9:132–49.
23. Ziskind D, Sharon E, Hirschfeld Z, Becker A. Analysis of lateral tooth movement during forced orthodontic eruption. *J Prosthet Dent* 2000; 84(4):462–6.