

Osteonecrosis of the Maxilla in a Patient with a History of Bisphosphonate Therapy

• Maico D. Melo, DMD •
• George Obeid, DDS •

A b s t r a c t

Bisphosphonates, which inhibit osteoclasts, alleviate many of the devastating consequences of metastatic bone disease. However, bisphosphonates may play a role in the development of osteonecrosis of the jaws. We report our experience in the management of a patient with a history of bisphosphonate therapy who presented with osteonecrosis of the jaws following dental extraction to make others, particularly the broader dental community, aware of this potential complication. We also review the pharmacologic properties of bisphosphonates and their possible role in the pathophysiology of osteonecrosis. Until more is known about the role of bisphosphonates in the development of osteonecrosis of the jaws, we recommend that measures be taken to prevent osteonecrosis in those at risk, including, when feasible, a dental consultation before initiating bisphosphonate therapy.

MeSH Key Words: case report; diphosphonates/adverse effects; osteonecrosis/chemically induced

© J Can Dent Assoc 2005; 71(2):111-3
This article has been peer reviewed.

Bisphosphonates are used widely in the management of bone diseases including osteoporosis, Paget's disease and hypercalcemia related to malignancy. Bisphosphonates inhibit osteoclasts, the cells responsible for bone demineralization. They have also been shown to inhibit tumour cell proliferation and inhibit angiogenesis.¹⁻⁷ These added features have made bisphosphonates useful in the management of bone metastases. Several clinical trials have shown that bisphosphonates reduce skeletal tumour burden in patients with multiple myeloma, breast cancer and prostate cancer,⁸⁻¹⁰ leading to an increase in the use of bisphosphonates in the management of metastatic disease.

Recently, it has been reported that bisphosphonates are capable of causing osteonecrosis of the jaws.^{11,12} Although this previously unrecognized complication is seen predominantly with the nitrogen-containing bisphosphonates, pamidronate and zoledronate, it has also been reported in patients taking non-nitrogen-containing bisphosphonates, alendronate and risedronate.¹² The former are indicated for the management of hypercalcemia of malignancy and are administered intravenously, whereas the latter are used in the management of osteoporosis and Paget's disease and are given orally. We were interested to learn of this complica-

tion, as we were recently involved in the management of a patient with a history of long-term bisphosphonate therapy presenting with osteonecrosis of the maxilla following routine dental extractions. We report on our experience in the management of this patient to make others aware of this potential complication.

Case Report

A 72-year-old woman was referred to us for treatment of a nonhealing extraction socket in the upper left maxilla following surgical extraction of her first molar 16 months earlier. Her past medical history included metastatic breast cancer, Parkinson's disease and hypertension. In addition to zoledronate, her medications included capecitabine, trastuzumab, levodopa and metoprolol.

Repeated attempts by the referring surgeon to close the extraction socket had been unsuccessful. At the time of presentation to our clinic, the woman had developed an oroantral communication and reported a foul-smelling discharge from the surgical site, but no pain for the past 3 months. On examination, we found bony exposure of the maxillary alveolus, and the surrounding soft tissues were erythematous and edematous (Fig. 1). In addition, the upper left premolars exhibited significant mobility.

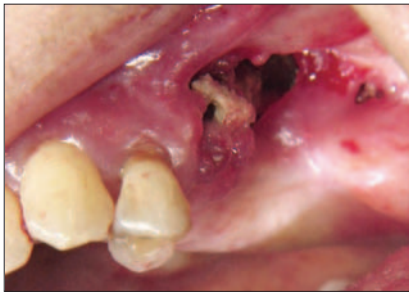

Figure 1: Pre-operative intraoral photograph showing exposed necrotic bone in upper left maxilla.

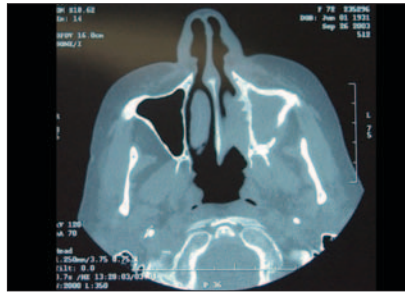

Figure 2: Axial computed tomography scan showing perforation of posterior wall and opacification of left maxillary sinus.

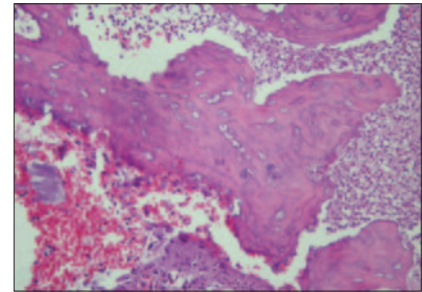


Figure 3: Photomicrograph of surgical specimen showing necrotic bone with numerous inflammatory cells and clusters of filamentous bacteria [hematoxylin and eosin stain, original magnification $\times 100$].

Computed tomography revealed that the posterior wall of the left maxillary sinus was perforated and the sinus lining appeared thickened (Fig. 2). We were of the opinion that the oroantral communication had failed to heal due to the presence of underlying necrotic bone.

We decided to debride the site surgically. A mucoperiosteal flap was raised to allow access to the left maxilla; necrotic bone and overlying granulation tissue were removed and submitted for pathologic evaluation. The upper left first premolar was extracted, as it was retained within necrotic bone. Interestingly, the upper left second premolar had spontaneously exfoliated in the time between our initial consultation and the surgery. Following debridement of the necrotic bone and removal of granulation tissue, the surgical site was closed with resorbable sutures and allowed to heal by secondary intention. No attempt was made to close the oroantral communication.

The pathology report indicated that the surgical specimen exhibited osteonecrosis, with evidence of filamentous bacteria consistent with an actinomycotic osteomyelitis (Fig. 3). Whether this represents a true primary actinomycotic infection or superinfection of necrotic bone with *Actinomyces* is debatable. At postoperative visits over 6 months, the soft tissues surrounding the surgical site were no longer erythematous or edematous but the oroantral communication persists, albeit less conspicuously.

Discussion

Studies have shown that in addition to osteoclast inhibition, bisphosphonates, particularly the more potent nitrogen-containing bisphosphonates, also inhibit bone metastases and reduce skeletal tumour burden.¹³ Although bisphosphonates vary in their potency, they share the ability to persist in bone for a prolonged period as they are not metabolized appreciably.¹⁴ One study,¹⁵ which examined the pharmacokinetic properties of bisphosphonates, reported that they persist for up to 12 years once they have been taken up in human bones. This may prove problematic in the management of complications related to bisphosphonates and implies that the potential for

bisphosphonate-related osteonecrosis to develop may remain for several years even in those who have discontinued the drug.

Bisphosphonates have also been shown to inhibit proliferation in a variety of human tumour cells in vitro, including breast, myeloma, melanoma and prostate cell lines.¹⁻⁵ In an attempt to improve understanding of the anti-tumour properties of bisphosphonates, investigators have examined the effects of these drugs on intracellular signalling pathways and shown that they are capable of inducing apoptosis.⁴ Inducing apoptosis would lead directly to a decrease in the number of tumour cells as well as nontumour cells as this is a ubiquitous cellular process.

Bisphosphonates also exhibit antiangiogenic properties.^{6,7} This is believed to be important in reducing tumour burden by depriving tumour cells of adequate nutrient and blood supply. Overall, it appears that bisphosphonates alter the bone microenvironment making it less favourable for tumour cell colonization. Unfortunately, these changes also alter the normal homeostatic mechanisms of bone and presumably make it less favourable for normal bone cells.

Recently, bisphosphonates have been associated with increased risk for the development of osteonecrosis.¹¹ Although the precise role of bisphosphonates remains to be determined, the alteration in bone homeostasis coupled with odontogenic or surgical insult, or both, may be key to the development of osteonecrosis of the jaws.^{11,12} This is supported by the observation that tooth extraction is a frequent precipitating event.^{11,12} In our patient, tooth extraction was also the precipitating event in the development of osteonecrosis. However, lesions consistent with osteonecrosis have also been reported to occur spontaneously in the jaws.¹²

An earlier case report¹⁶ identified etidronate, a bisphosphonate once used in the management of osteoporosis, as the cause of medication-induced dental implant failure. It described the failure of 5 successfully restored dental implants approximately 6 months after the patient began receiving etidronate. Although the authors correctly point

out that additional factors, including the development of a parafunctional habit, may have contributed to the implant failure, they recommended that dental implants not be placed in patients receiving bisphosphonate therapy and advised against bisphosphonate therapy in patients with existing dental implants. To our knowledge, no additional reports have addressed the effects of bisphosphonate therapy on dental implants in vivo. It has been suggested that bisphosphonates, with their antiresorptive properties, might one day be employed to facilitate implant osseointegration, but data to support this are lacking.¹⁷ Thus, until more information is available regarding the role of bisphosphonates in the outcome of dental implants, it seems reasonable to adhere to the recommendations outlined above.

It is also interesting to note that certain similarities exist in the clinical presentation of bisphosphonate-related osteonecrosis and osteoradionecrosis. We speculate that there may be similarities in the underlying pathophysiology of these conditions. In osteoradionecrosis, radiation leads to homeostatic alteration of bone metabolism characterized by hypocellular, hypovascular and hypoxic changes that predispose the mandible to necrosis.¹⁸ The necrotic bone is susceptible to and often secondarily infected in patients with osteoradionecrosis. In addition, the risk of developing lesions persists for the lifetime of the irradiated patient. We believe that in bisphosphonate-related osteonecrosis, bisphosphonates alter bone homeostasis sufficiently that the ability of bone to heal after minor insults is compromised. Under certain conditions the bone may also become secondarily infected and sequester, leading to a lesion that appears clinically similar to osteoradionecrosis.

Although much remains to be learned about the complex interactions by which bisphosphonates exert their effects, it seems prudent to make health care professionals and patients aware of the potential risk. Novartis, the manufacturer of Aredia (pamidronate) and Zometa (zoledronic acid), recently added osteonecrosis of the jaws to the precautions section of their product monographs. Novartis also recommends that patients receiving either pamidronate or zoledronic acid should avoid invasive dental surgery. It is not clear at this time whether discontinuing bisphosphonates would significantly alter the risk or course of osteonecrosis of the jaws.

We are currently collaborating with oncologist colleagues to identify strategies to improve the care of patients at our hospital. However, until more is known about the role of bisphosphonates in the development of osteonecrosis of the jaws, we recommend that measures be taken to prevent osteonecrosis in those at risk. This includes adopting appropriate preventive dentistry with control of dental caries and periodontal disease, avoiding dental implant placement and using soft liners on dentures.

Similar to protocols in place at many institutions for preventing osteoradionecrosis in patients about to receive radiation treatment of the head and neck, we recommend that a thorough dental examination and necessary tooth extractions with time for healing be performed before commencing intravenous bisphosphonate therapy.

In addition, because dental surgery seems to be a precipitating event in the development of most cases of bisphosphonate-related osteonecrosis, it seems appropriate to recommend alternatives to tooth extraction for patients with a history of receiving either pamidronate or zoledronic acid. If alternatives to tooth extraction are not possible, the patient should be made aware of the potential risk of osteonecrosis and the surgeon should be prepared to assist the patient should it develop.

Unfortunately, there are insufficient data to guide unequivocally the management of patients who have developed bisphosphonate-related osteonecrosis. Until such a time, we recommend that efforts be focused on preventing the progression of lesions and limiting complications related to infection. To achieve this, background antibiotic coverage with penicillin-type antibiotics or a suitable alternative, such as doxycycline in penicillin-allergic patients, daily rinsing with 0.12% chlorhexidine mouthwash and conservative debridement of sequestering bone should be considered. ♦



Dr. Melo is resident, department of oral and maxillofacial surgery, Washington Hospital Center, Washington, DC.



Dr. Obeid is chair, department of oral and maxillofacial surgery, Washington Hospital Center, Washington, DC.

Correspondence to: Dr. Maico D. Melo, Room GA-144, Washington Hospital Center, 110 Irving St. NW, Washington DC 20010, USA. E-mail: mmelo2@msn.com.

The authors have no declared financial interests.

References

1. Aparicio A, Gardner A, Tu Y, Savage A, Berenson J, Lichtenstein A, and others. In vitro cytoreductive effects on multiple myeloma cell induced by bisphosphonates. *Leukemia* 1998; 12(2):220-9.
2. Lee MV, Fong EM, Singer FR, Guenette RS. Bisphosphonate treatment inhibits the growth of prostate cancer cells. *Cancer Res* 2001; 61(6):2602-8.
3. Riebeling C, Forsea AM, Raisova M, Orfanos CE, Geilen CC. The bisphosphonate pamidronate induces apoptosis in human melanoma cells in vitro. *Br J Cancer* 2002; 87(3):366-71.
4. Shipman CM, Rogers MJ, Apperley JF, Russell RG, Croucher PJ. Bisphosphonates induce apoptosis in human myeloma cell lines: a novel anti-tumor activity. *Br J Haematol* 1997; 98(3):665-72.
5. Senaratne SG, Pirianov G, Mansi JL, Arnett TR, Colston KW. Bisphosphonates induce apoptosis in human breast cancer cell lines. *Br J Cancer* 2000; 82(8):1459-68.

6. Wood J, Bonjean K, Ruetz S, Bellahcene A, Devy L, Foidart JM, and others. Novel antiangiogenic effects of the bisphosphonate compound zoledronic acid. *J Pharmacol Exp Ther* 2002; 302(3):1055-61.
7. Fournier P, Boissier S, Filleur S, Guglielmi J, Cabon F, Colombel M, and others. Bisphosphonates inhibit angiogenesis in vitro and testosterone-stimulated vascular regrowth in the ventral prostate in castrated rats. *Cancer Res* 2002; 62(22):6538-44.
8. Berenson JR. Advances in the biology and treatment of myeloma bone disease. *Semin Oncol* 2002; 29(6 Suppl 17):11-6.
9. Powles T, Paterson S, Kanis JA, McCloskey E, Ashley S, Tidy A, and others. Randomized, placebo-controlled trial of clodronate in patients with primary operable breast cancer. *J Clin Oncol* 2002; 20(15):3219-24.
10. Saad F, Gleason DM, Murray R, Tchekmedyian S, Veneer P, Lacombe L, and others. A randomized, placebo-controlled trial of zoledronic acid in patients with hormone-refractory metastatic prostate carcinoma. *J Natl Cancer Inst* 2002; 94(19):1458-68.
11. Marx RE. Pamidronate (Aredia) and zolodronate (Zometa) induced avascular necrosis of the jaws: a growing epidemic. *J Oral and Maxillofac Surg* 2003; 61(9):1115-7.
12. Ruggiero SL, Mehrotra B, Rosenberg TJ, Engroff SL. Osteonecrosis of the jaws associated with the use of bisphosphonates: a review of 63 cases. *J Oral and Maxillofac Surg* 2004; 62(5):527-34.
13. Fleisch H. Development of bisphosphonates. *Breast Cancer Res* 2002; 4(1):30-4.
14. Russell RG, Rogers MJ, Frith JC, Luckman SP, Coxen FP, Benford HL, and others. The pharmacology of bisphosphonates and new insights into their mechanisms of action. *J Bone Miner Res* 1999; Suppl 2:53-65.
15. Lin JH, Russell RG, Gertz B. Pharmacokinetics of alendronate: an overview. *Int J Clin Pract* 1999; 101:18-26.
16. Starck WJ, Epker BN. Failure of osseointegrated dental implants after diphosphonate therapy for osteoporosis: a case report. *Int J Oral Maxillofac Implants* 1995; 10(1):74-8.
17. Teronen O, Kontinen YT, Lindqvist C, Salo T, Ingman T, Lauhio A, and others. Human neutrophil collagenase MMP-8 in peri-implant sulcus fluid and its inhibition by clodronate. *J Dent Res* 1997; 76(9):1529-37.
18. Marx, RE: Osteoradionecrosis: a new concept of its pathophysiology. *J Oral Maxillofac Surg* 1983; 41(5):283-8.