

Combined Endodontic Therapy and Surgery in the Treatment of Dens Invaginatus Type 3: Case Report

Ulisses Xavier da Silva Neto, DDS, PhD; Vinício Hidemitsu Goto Hirai, DDS, MSc; Vula Papalexiou, DDS, MSc; Silvana Beltrami Gonçalves, DDS, MSc; Vânia Portela Ditzel Westphalen, DDS, PhD; Clovis Monteiro Bramante, DDS, PhD; Wilson Denis Martins, DDS, PhD, OMFS

Contact Author

Dr. Martins
E-mail: w.denis@pucpr.br



ABSTRACT

An accurate understanding of the morphology of the root canal system is a prerequisite for successful root canal treatment. Invaginated teeth have a complex root canal configuration that cannot be instrumented effectively and should be treated by both endodontic therapy and surgery. A case of dens invaginatus Type 3 in a maxillary lateral incisor with a periapical lesion and its successful treatment by these combined methods is reported.

MeSH Key Words: dens in dente/therapy; dental pulp cavity/abnormalities; incisor/abnormalities; root canal therapy/methods

© J Can Dent Assoc 2005; 71(11):855-8
This article has been peer reviewed.

Dens invaginatus is a developmental anomaly resulting from infolding of the surface of the tooth crown before calcification has occurred.^{1,2} Numerous mechanisms have been proposed as a cause of this phenomenon, including local delay in enamel formation, infolding of the enamel organ within the dental pulp and local external influences on the tooth germ.³ The etiology of dens invaginatus is still not entirely known.⁴

The reported incidence of dens invaginatus ranges from 0.04% to 10%⁵ and the teeth most commonly affected are the maxillary lateral incisors. Oehlers⁶ classification of invaginations is the most widely recognized.

Type 1 is an enamel-lined minor invagination occurring within the confines of the crown, not extending beyond the amelo-cemental junction. Type 2 consists of an enamel-lined form that invades the root but remains as a blind sac; it may or may not connect with the dental pulp. Type 3 invaginations penetrate through the root, perforating the apical area and forming a second foramen in the apical or periodontal area; there is no immediate connection with the

pulp. Type 3 invaginations may be completely lined by enamel, although cementum is also frequently found.

Clinically, the finding most often associated with dens invaginatus is early pulpal involvement when channels extend from the invagination into the pulp.⁷ Because the invagination forms a space conducive to dental caries, bacteria and their products gain access to the dental pulp via the channels, resulting in pulp pathosis.

Several treatments of pathosis associated with dens invaginatus have been suggested: endodontic therapy, endodontic surgery, combined treatment or extraction.^{7,8} Some cases have been treated with calcium hydroxide to induce apical closure and promote repair. Occasionally, the presence of immature roots necessitates apexification.^{9,10} In some cases, surgical procedures may also be necessary.^{11,12}

Removal of dens invaginatus with the aid of an operating microscope and subsequent root canal treatment has also been described.² Extraction is only indicated in supernumerary teeth or if endodontic therapy and apical surgery have failed or are not possible.¹⁰

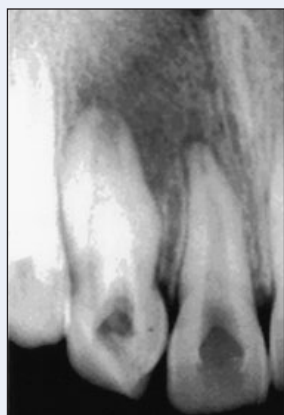

Figure 1: Preoperative radiograph of maxillary lateral incisor showing Type 3 dens invaginatus with periapical radiolucency.

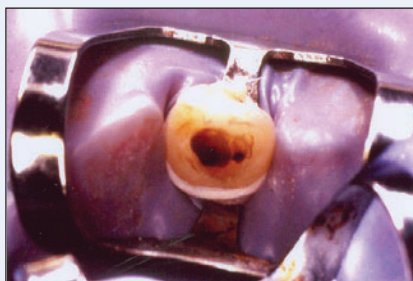


Figure 2: Access opening demonstrating 2 distinct canal orifices.

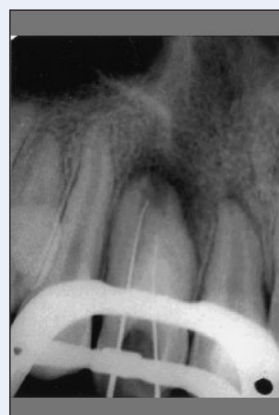

Figure 3: Radiograph with K-files in both canals.

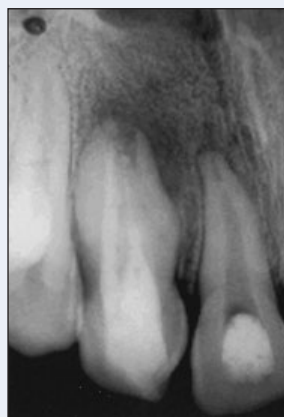

Figure 4: Immediate post-obturation radiograph.

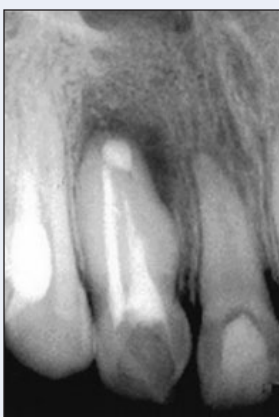

Figure 5: Immediate post-surgery radiograph.

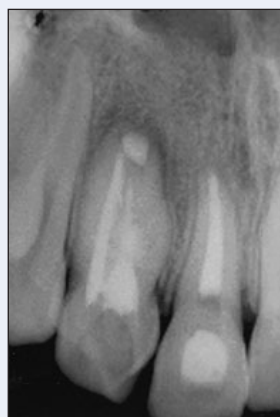

Figure 6: Radiograph taken at 3 months follow-up.

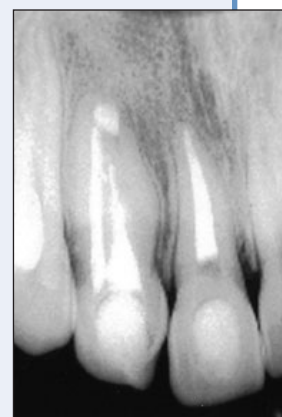

Figure 7: One year after treatment, the radiographic appearance of the periapical area is normal for both the central and lateral incisors.

The purpose of this article is to describe the use of combined endodontic therapy and surgery in the treatment of Type 3 dens invaginatus in a maxillary lateral incisor.

Case Report

A 12-year-old girl was referred to the endodontic clinic at the Pontifical Catholic University of Paraná with pain and swelling in her maxillary right lateral incisor. The patient described recent severe pain over 3 days, but no previous history of any signs or symptoms. The medical history was noncontributory. The tooth was sensitive to percussion, but failed to respond to pulp sensitivity testing. A periapical radiograph revealed a radiolucent lesion in the apical third of the right lateral incisor (Fig. 1).

A clinical diagnosis of dens invaginatus (Oehlers' Type 3), necrotic pulp and acute apical abscess was established. Following isolation of the tooth with a rubber dam, the pulp chamber was opened and the invagination orifice located. When the orifice was enlarged, the primary root canal was discovered in a more distal position (Fig. 2).

A radiograph was obtained with files inserted in the root canals (Fig. 3) to establish working lengths. There did not appear to be any connection between the primary root canal and the invagination. Both canals were debrided thoroughly and prepared by the step-back technique to a size 50 file.

Copious irrigation with 1% sodium hypochlorite solution was carried out throughout the procedure. After

drying the root canals with paper points, calcium hydroxide was applied and the cavity was temporarily sealed with Cavit (ESPE, Seefeld, Germany).

Two weeks later, the patient was without symptoms or swelling. The root canal system was filled using Thermafil obturation (Dentsply Maillefer, Ballaigues, Switzerland) and zinc oxide–eugenol sealer (Endofill, Dentsply).

A postoperative radiograph was obtained (Fig. 4). Immediately following treatment of the lateral incisor, the central incisor was treated with conventional orthograde (nonsurgical) endodontic therapy.

After 15 days, the patient returned and apical surgery was performed to remove a portion of the root with undebrired space and to retro-seal the canal.

The surgical intervention consisted of apical curettage, root-end resection, root-end preparation with ultrasonic tips and retrofilling (Fig. 5). A vestibular flap was raised and the rough borders of the root were smoothed, granulation tissue was removed, mechanical retention provided and retrograde ProRoot–MTA (Dentsply) inserted. Sutures were used to close and healing was uneventful. At 3-month and 6-month follow-up examinations, the patient was asymptomatic and radiographic evidence of satisfactory healing was confirmed by a decrease in the size of the apical radiolucency (Figs. 6 and 7).

Discussion

Dens invaginatus requires early diagnosis and treatment, as it may result in radicular and periapical pathosis. Treatment may vary from case to case. In the current case, an Oehlers⁶ Type 3 invagination on a maxillary lateral incisor extended from the crown to the apex of the root, with no apparent connection with the main canal. Radiography showed a periapical pathosis.

In this type of developmental anomaly, there may be direct communication between the pulp and the oral cavity. When this is the case, microorganisms from saliva infect the pulp and necrosis may lead to the formation of an apical lesion. Many investigators have reported the occurrence of pulpal and periapical pathosis related to dental invaginations, which suggests that apical pathosis from pulpal death is a common occurrence related to caries or defects within the invagination.^{13,14}

Usually, a patient will not discover an anomaly such as dens invaginatus until clinical signs appear, i.e., an acute dentoalveolar abscess or sinus tract.

Several hypotheses have been postulated regarding the development of an invaginated tooth. A recent theory proposes that it is a consequence of the degeneration of the dental lamina, which can lead to fusion, gemination or agenesis. This is supported by the fact that invagination is most common in maxillary lateral incisors and premolars, the most common sites of agenesis, and that it occurs in supernumerary teeth.^{15–17}

The treatment of invaginated teeth is a complex procedure. They present a complex root canal configuration that is often not possible to instrument completely. As a result, these teeth should be selected for combined orthograde and surgical treatment.^{7,18} Endodontic surgery is indicated for cases of severe forms of dens invaginatus where periapical lesions are prominent.⁸ In other cases, combined treatment may be necessary, that is, endodontic therapy followed by endodontic surgery, because of the complexity of the root morphology. The surgery will provide an additional retrograde seal to the root canals, which may remain a source of irritation.

Occasionally, temporary root canal filling with calcium hydroxide may be indicated. It was used in this case for 15 days without challenge.⁹ Also, the use of intracanal medication may be needed to assist in the disinfection of root canal systems that are not fully accessible.

The root canal was filled using the Thermafil technique because it allows the flow of warm, softened gutta-percha into major irregularities within the canal system.

Conclusion

Because of the complications presented by dens invaginatus Type 3 and an acute periapical abscess, combined nonsurgical and surgical endodontic therapy was indicated in this case. Follow-up radiography over 1 year showed evidence of complete healing. ✦

THE AUTHORS



Dr. da Silva Neto is a professor of endodontics at the Pontifical Catholic University of Paraná, Curitiba, PR, Brazil.

Dr. Hirai is an endodontics specialist in private practice in Curitiba, Paraná, Brazil.

Dr. Papalexiou is a professor of periodontology at the Pontifical Catholic University of Paraná, Curitiba, PR, Brazil.

Dr. Gonçalves is a PhD candidate at the Bauru Dental School, University of São Paulo, Bauru, São Paulo, Brazil.



Dr. Westphalen is a professor of endodontics at the Pontifical Catholic University of Paraná, Curitiba, PR, Brazil.

Dr. Bramante is a professor of endodontics at the Bauru Dental School, University of São Paulo, Bauru, São Paulo, Brazil.



Dr. Martins is a professor of oral and maxillofacial surgery and stomatology at the Pontifical Catholic University of Paraná, Curitiba, PR, Brazil.

Correspondence to: Dr. Wilson Denis Martins, Av. República do Líbano, 462 Curitiba, Paraná, Brazil. CEP 82520-500. E-mail: w.denis@pucpr.br.

The authors have no declared financial interests in any company manufacturing the types of products mentioned in this article.

References

1. Jimenez-Rubio A, Segura JJ, Feito JJ. A case of combined dental development abnormalities: importance of a thorough examination. *Endod Dent Traumatol* 1998; 14(2):99–102.
2. Girsch WJ, McClammy TV. Microscopic removal of dens invaginatus. *J Endod* 2002; 28(4):336–9.
3. Hulsmann M. Dens invaginatus: aetiology, classification, prevalence, diagnosis, and treatment considerations. *Int Endod J* 1997; 30(2):79–90.
4. Dankner E, Harari D, Rotstein I. Conservative treatment of dens evaginatus of anterior teeth. *Endod Dent Traumatol* 1996; 12(4):206–8.
5. Hovland EJ, Block RM. Nonrecognition and subsequent endodontic treatment of dens invaginatus. *J Endod* 1977; 3(9):360–2.
6. Oehlers FA. Dens invaginatus (dilated composite odontome). I. Variations of the invagination process and associated anterior crown forms. *Oral Surg Oral Med Oral Pathol* 1957; 10(11):1204–18.
7. Rotstein I, Stabholz A, Heling I, Friedman S. Clinical considerations in the treatment of dens invaginatus. *Endod Dent Traumatol* 1987; 3(5):249–54.
8. de Sousa SM, Bramante CM. Dens invaginatus: treatment choices. *Endod Dent Traumatol* 1998; 14(4):152–8.
9. Ferguson FS, Friedman S, Frazzetto V. Successful apexification technique in an immature tooth with dens in dente. *Oral Surg Oral Med Oral Pathol* 1980; 49(4):356–9.
10. Jung M. Endodontic treatment of dens invaginatus type III with three root canals and open apical foramen. *Int Endod J* 2004; 37(3):205–13.
11. Beltes P. Endodontic treatment in three cases of dens invaginatus. *J Endod* 1997; 23(6):399–402.
12. Froner IC, Rocha LF, da Costa WF, Barros VM, Morello D. Complex treatment of dens invaginatus type III in a maxillary lateral incisor. *Endod Dent Traumatol* 1999; 15(2):88–90.
13. Caliskan MK. Traumatic gemination — triple tooth. Survey of the literature and report of a case. *Endod Dent Traumatol* 1992; 8(3):130–3.
14. Pindborg JJ. Pathology of dental hard tissues. Philadelphia: WB Saunders; 1970. p. 56–64.
15. Tavano SM, de Souza SM, Bramante CM. Dens invaginatus in first mandibular premolar. *Endod Dent Traumatol* 1994; 10(1):27–9.
16. Hulsmann M, Hengen G. Severe dens invaginatus malformation: report of two cases. *Oral Surg Oral Med Oral Pathol* 1996; 82(4):456–8.
17. Jimenez-Rubio A, Segura JJ, Jimenez-Planas A, Llamas R. Multiple dens invaginatus affecting maxillary lateral incisors and a supernumerary tooth. *Endod Dent Traumatol* 1997; 13(4):196–8.
18. Froner IC, Rocha LF, da Costa WF, Barros VM, Morello D. Complex treatment of dens invaginatus type III in a maxillary lateral incisor. *Endod Dent Traumatol* 1999; 15(2):88–90.