

Necrotizing Fasciitis of the Face: A Rare but Dangerous Complication of Dental Infection

• Christopher C. Fenton, BSc, DDS •
 • Thomas Kertesz, BSc, DDS •
 • Gerald Baker, DDS, MS, FRCD(C), FICD •
 • George K.B. Sándor, MD, DDS, PhD, FRCD(C), FRCSC, FACS •

A b s t r a c t

Necrotizing fasciitis of the face is extremely rare. However, dentists should be familiar with the presentation of this condition because of the suddenness of its onset, the rapidity of its spread, the resulting drastically disfiguring morbidity and the high rate of mortality associated with it. In this paper, we describe the presentation and treatment of a 57-year-old woman with necrotizing fasciitis of the face and neck due to dental causes and discuss factors in the management of this life-threatening condition.

MeSH Key Words: abscess complications; face; fasciitis, necrotizing/therapy; tooth diseases/complications

© J Can Dent Assoc 2004; 70(9):611-5
 This article has been peer reviewed.

Necrotizing fasciitis (NF) is a rapidly spreading infection involving the superficial fat and fascial layers with necrosis of the overlying skin. The lesion was first described during the American Civil War¹ and has been reported extensively in the general surgery literature. It is most common in the perineum, abdominal wall and extremities and is most often seen in the elderly and in immunocompromised patients.² NF is less common in the head and neck, especially in the face. In their review, Shindo and others³ found only 35 reports of facial NF.

This infection can result from dental,⁴⁻⁶ sinus,⁷ peritonsillar^{8,9} and salivary gland¹⁰ infections or infections secondary to surgery¹¹ or trauma.³ The causative agents have classically been described as group A beta-hemolytic streptococci and staphylococci and also include obligate anaerobic bacteria.^{5,12}

If not promptly recognized and treated, NF may spread into the deep spaces of the neck and compromise the airway; it may also spread into the mediastinum producing life-threatening sepsis.

In this report, we describe the presentation and treatment of facial NF in a 57-year-old woman and discuss management considerations.

Case Report

The oral and maxillofacial surgery service at Mount Sinai Hospital was consulted regarding a 57-year-old woman with a 5-day history of right-side facial swelling, trismus and pain. She had been seen previously by a dentist who prescribed amoxicillin but, because of lack of compliance with treatment, her symptoms continued to worsen. A review of her medical history revealed severe depression and an anxiety disorder, and her medications included an anti-depressant and a high-dose benzodiazepine. Clinical and radiographic examination revealed a moderate right buccal space infection with right submandibular involvement secondary to grossly decayed teeth 46 and 47. The parapharyngeal spaces were clear and there was no airway compromise. The patient was admitted for intravenous antibiotics, observation and analgesia. Unfortunately, on the night of her admission, she pulled out her intravenous catheter and discharged herself from the hospital against medical advice. Multiple attempts to contact her were unsuccessful.

Five days later, she returned to the emergency department with marked deterioration. She appeared toxic, was febrile and tachycardic. A large necrotic region on her right cheek extended from the zygomatic arch to below the

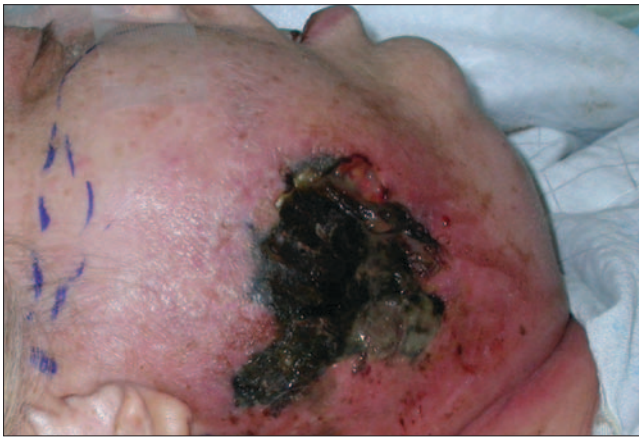

Figure 1: Patient with full-thickness necrosis of the cheek and initial extensive bullae and erythema from the zygomatic arch to the inferior border of the mandible.

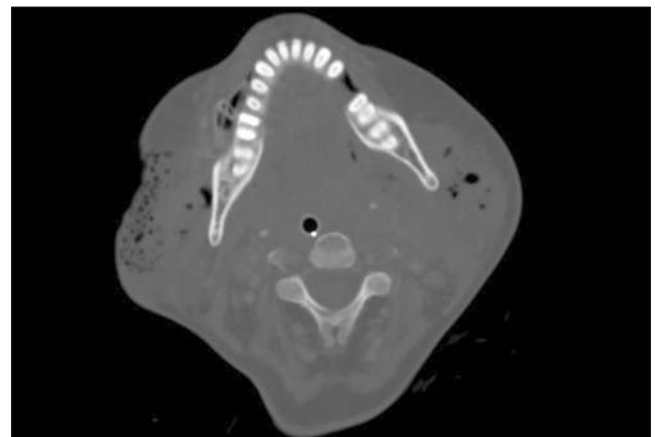


Figure 2: Preoperative CT scan showing marked edema and extensive subcutaneous gas formation, which is also present in the parotid gland bilaterally.

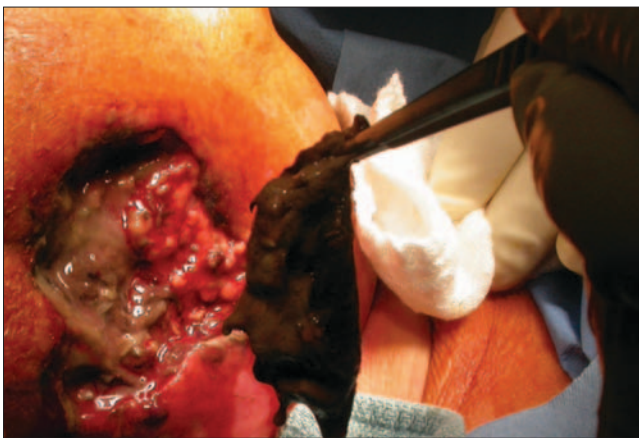


Figure 3: Necrotic tissue being excised from the wound. The margins of the excision had to be extended several times as the lesion continued to spread intraoperatively.

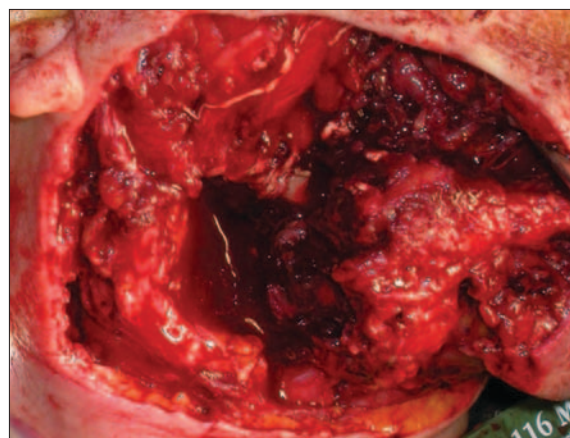


Figure 4: Postoperative defect after extensive resection of all necrotic tissues.

mandible (Fig. 1). There was severe right temporal, bilateral submandibular, cervical and floor of the mouth swelling.

The skin appeared grossly abnormal; a spectrum of findings ranged from erythema, patchy areas of bullae to frank necrosis. Marked crepitus was noted from the zygomatic region to the laryngeal cartilages in the neck. The patient was taken to the operating room for immediate endotracheal intubation, which was performed uneventfully. A tracheostomy was considered but was not performed due to the degree of paratracheal swelling. After the airway was secure, an emergent computed tomography (CT) scan revealed the presence of severe subcutaneous gas formation and marked generalized head and neck edema (Fig. 2).

The patient was taken to the operating room where immediate complete debridement of all necrotic tissue was performed until bleeding tissue was encountered. The areas of debridement had to be extended throughout the operation as the zones of involvement and necrosis were seen to extend and increase during the surgery (Figs. 3 and 4).

Clindamycin (900 mg intravenously every 8 h) was started following an intraoperative infectious disease consultation. Exploration and decompression of all involved fascial spaces was also completed, and teeth 46 and 47 were extracted. Multiple tissue samples were sent for culture, which later revealed the presence of a mixed infection, including *Streptococcus milleri*, coagulase negative *Staphylococcus* and anaerobic Gram-negative bacilli. The wound was packed with iodine gauze (Fig. 5). Intraoperatively, the patient exhibited signs of septic shock with hemodynamic instability requiring inotropic agents to maintain her blood pressure. She was transferred to the intensive care unit (ICU) and remained intubated.

The patient remained in the ICU for approximately 2 weeks. During the initial period in the ICU, hyperbaric oxygen treatment (HBOT) was administered 6 times. Wound care in the form of frequently changed povidone-soaked gauze and further debridement of necrotic tissue was carried out. On one occasion, the patient was taken to the operating room for further debridement and partial

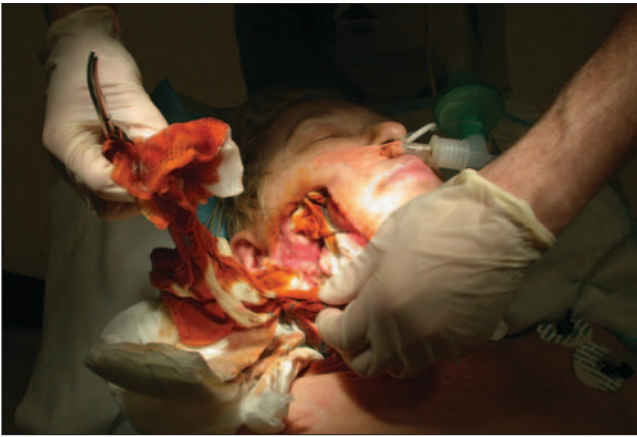

Figure 5: Wound management with povidone-soaked gauze dressings.

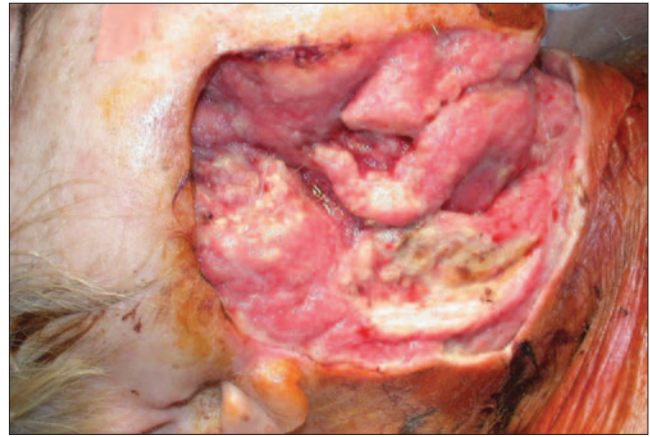


Figure 6: The appearance of fresh granulation tissue heralds improvement of the wound and its readiness for skin grafting.

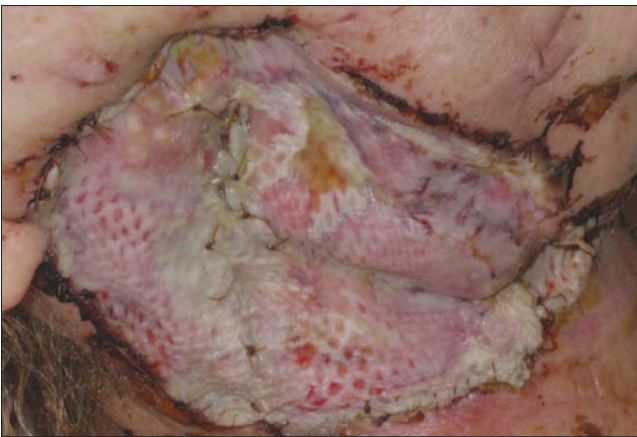

Figure 7: Split-thickness skin grafts with perforations placed over the resection defect.

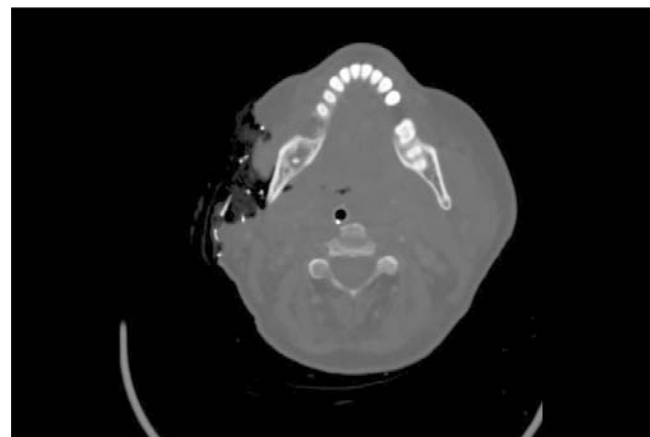


Figure 8: Postoperative CT scan showing resolution of the infection and the defect of the right face by resection of the necrotic tissue.

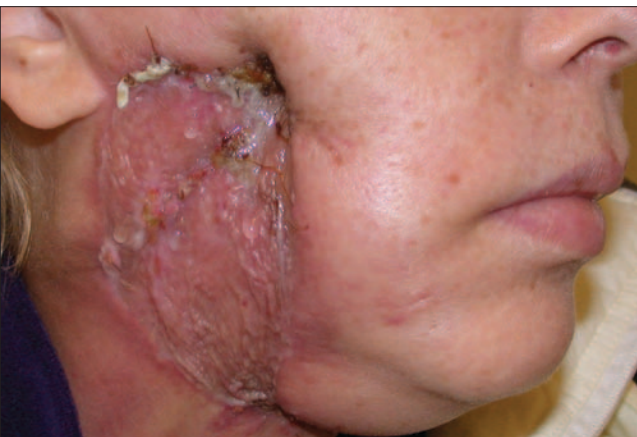

Figure 9: Healed skin grafts 4 weeks after resection.

decortication of the now-exposed surfaces of the mandible and zygoma. The mandible was covered using a split sternocleidomastoid muscle flap, and all teeth with questionable prognosis were extracted.

At a later date, when the wound bed was judged to be adequate (Fig. 6), multiple strips of split-thickness skin grafts were taken from the lateral thigh and grafted to the

exposed areas to provide primary cutaneous coverage over the large exposed area left by the surgical debridements (Fig. 7). Definitive cosmetic treatment was delayed until the patient's comorbid conditions, including her psychiatric status, were stabilized.

During the next 2 weeks, the patient continued to improve slowly, both hemodynamically and clinically, although her postoperative recovery was complicated by a case of hospital-acquired pneumonia and an initial period of poor oral feeding due to fatigue and poor masticatory muscle coordination. Her pneumonia responded well to antibiotic treatment and a percutaneous gastric tube was used initially for nutrition. Throughout her stay, she continued to be followed by the infectious disease and psychiatry teams. Repeat examinations by serial CT scan revealed improvements in the involved fascial spaces (Fig. 8). Laboratory values continued to normalize and the patient remained afebrile. She was discharged to a local rehabilitation hospital in stable condition.

At 4 weeks follow-up, the patient remained asymptomatic, skin coverage over her large wound was excellent (Fig. 9) and oral food intake was good. Definitive treatment

to provide bulk and improved cosmesis, in the form of further rotational or free vascularized flaps, will be considered.

Discussion

NF of the head and neck is a rare but potentially fatal disease that all dentists should be aware of⁴ as prompt diagnosis and recognition are the first and most important steps in its management. A delay in diagnosis could result in further disastrous morbidity.^{4,5}

The infection involves the superficial fascial planes of the head and neck, i.e., the superficial musculoaponeurotic system, which envelops the muscles that determine facial expression and extends from the frontalis muscle inferiorly to the platysma muscle and from the nasolabial fold posteriorly to the sternocleidomastoid muscle. In the initial stages before necrosis is seen, the infection spreads in the subcutaneous tissues and may appear as a routine dental infection.⁵ Initially, the overlying skin surface is smooth, tense, shiny and inflamed. As the disease progresses, the overlying skin becomes dusky and blisters or bullae eventually form.¹² The underlying subcutaneous destruction creates an ideal culture medium for bacterial growth, and the skin later becomes gangrenous and necrotic secondary to thrombosis of the perforating dermal vessels.

The clinician must maintain a high index of suspicion with any patient presenting with a rapidly spreading, swelling erythema and fever, and palpate the wound to check for crepitus, which might indicate subcutaneous gas production. The absence of crepitus does not rule out gas formation, as this may be deep and inaccessible to clinical examination.¹² The first clinician to see the patient should mark the extent of the borders or periphery of the suspected tissue involvement with a felt pen so that the progression of the disease can be monitored later by the team who takes over the care of the patient. This will help the clinicians judge the degree and rapidity of the spread of the infection. The diagnosis of NF of the head and neck is often a clinical one; however, in the early stages a timely CT examination may reveal soft tissue gases in the neck. A CT scan is also helpful in rapidly determining the extent of the infection and the anatomic structures involved, and in identifying vascular thrombosis or vessel erosion.^{12,13}

Laboratory findings can include leukocytosis or leukopenia and hypocalcemia secondary to the deposition of calcium in necrotic tissues.¹ Blood and wound cultures should be obtained, but treatment must be initiated before obtaining the results.

Once the diagnosis is made, treatment must not be delayed. Regarding NF of odontogenic origin, Stoykewych, Becroft and Cogan⁴ found 4 factors that contribute significantly to morbidity and mortality: delayed treatment due to difficulty in recognizing the condition; inappropriate treatment; host debilitation; and the presence of a polymicrobial infection.

In the series reported by Umeda and others,⁵ 3 clinical factors were found to affect mortality: a delay in surgery; the development of mediastinitis; and the presence of medical comorbidities. The cornerstone of treatment is surgical debridement. All necrotic tissue must be removed until healthy bleeding tissue is encountered. Reluctance to debride facial soft tissues aggressively and avoid unsightly disfigurement often leads to undertreatment of the disease early in its course.³ Multiple surgical debridements in the operating room are usually needed.¹⁴

After surgical debridement, wounds are left open and packed with povidone-moistened gauze,¹⁵ which is changed frequently. It is important to prevent pooling of secretions in the wound that may provide a culture medium for further bacterial growth.

Along with debridement, appropriate antibiotic coverage is imperative. Classically, the organisms described in NF are group A beta-hemolytic *Streptococcus* and *Staphylococcus*; however, improved culture techniques have isolated a broader spectrum of microbes including obligate anaerobes. Odontogenic infections are often polymicrobial; initial therapy for NF could include broad-spectrum coverage and often more than one antibiotic is necessary.^{5,6} The initial antibiotics may include a penicillinase-resistant penicillin for streptococcal and staphylococcal bacteria, an aminoglycoside for Gram-negative bacteria and clindamycin or metronidazole for anaerobic organisms. The coverage can be narrowed when culture results are available.

Even with adequate surgical debridement and intravenous antibiotic therapy, the mortality rate associated with NF is 20% to 40%.¹⁶ Umeda and others⁵ review of NF of odontogenic origin revealed a mortality rate of 19.2%. Various adjunctive therapies have been tried to improve outcomes. Two that should be considered are HBOT and intravenous immunoglobulins G (IVIGG).

A number of studies^{17,18} have suggested that the outcome for patients with NF may be improved by HBOT, but not all have shown benefits.¹⁹ In the treatment of NF, IVIGG can neutralize superantigens and down-regulate the production of tumour necrosis factor. The use of IVIGG in NF was first reported in 1994²⁰ and Skitarelic and others²¹ were the first to describe their use in a case of head and neck NF. IVIGG have not been as extensively studied as HBOT and future clinical trials will be needed to determine their efficacy.

Once the infection has been resolved, the defect can initially be covered with a split-thickness skin graft and reconstructed secondarily by advancement flaps or vascularized free flaps if necessary.

Conclusions

In this report, we reviewed the history, clinical and radiographic presentation of a 57-year-old woman with NF of the face and discussed diagnostic and management

considerations. NF should always be considered in the diagnosis of cellulitic infection of the head and neck, including infections of dental origin. NF is associated with a high rate of morbidity and mortality. A delay in treatment due to difficulty in recognizing the condition may result in a disastrous outcome. ➤



Dr. Fenton is a senior resident in oral and maxillofacial surgery and anesthesia, University of Toronto, Toronto, Ontario.



Dr. Kertesz is a senior resident in oral and maxillofacial surgery and anesthesia, University of Toronto, Toronto, Ontario.



Dr. Baker is head, division of oral and maxillofacial surgery, Mount Sinai Hospital, and assistant professor, faculty of dentistry, University of Toronto, Toronto, Canada.



Dr. Sándor is an associate professor and director, graduate program in oral and maxillofacial surgery and anesthesia, University of Toronto, and coordinator of oral and maxillofacial surgery at The Hospital for Sick Children and Bloorview MacMillan Children's Centre, Toronto, Ontario, and docent in oral and maxillofacial surgery at the University of Oulu, Oulu, Finland.

Correspondence to: Dr. George K.B. Sándor, The Hospital of Sick Children, S-527, 555 University Ave., Toronto ON M5G 1X8. E-mail: george.sandor@utoronto.ca.

The authors have no declared financial interests.

References

1. Chattar-Cora D, Tulsyan N, Cudjoe EA, Onime GD, Pyo DJ, Weinstein L. Necrotizing fasciitis of the head and neck: a report of two patients and review. *Head Neck* 2002; 24(5):497-501.
2. Mohammadi I, Ceruse P, Duperret S, Vedrinne J, Bouletreau P. Cervical necrotizing fasciitis: 10 years' experience at a single institution. *Intensive Care Med* 1999; 25(8):829-34.
3. Shindo ML, Nalbhone VP, Dougherty WR. Necrotizing fasciitis of the face. *Laryngoscope* 1997; 107(8):1071-9.
4. Stoykewych AA, Beecroft WA, Cogan AG. Fatal necrotizing fasciitis of dental origin. *J Can Dent Assoc* 1992; 58(1):59-62.
5. Umeda M, Minamikawa T, Komatsubara H, Shibuya Y, Yokoo S, Komori T. Necrotizing fasciitis caused by dental infection: a retrospective analysis of 9 cases and a review of the literature. *Oral Surg Oral Med Oral Pathol Oral Radiol Endod* 2003; 95(3):283-90.
6. Dale RA, Hoffman DS, Crichton RO, Johnson SB. Necrotizing fasciitis of the head and neck: review of the literature and report of a case. *Spec Care Dentist* 1999; 19(6):267-74.
7. Raboso E, Llaverro MT, Rosell A, Martinez-Vidal A. Craniofacial necrotizing fasciitis secondary to sinusitis. *J Laryngol Otol* 1998; 112(4):371-2.
8. Skitarelic N, Mladina R, Matulic Z, Kovacic M. Necrotizing fasciitis after peritonsillar abscess in an immunocompetent patient. *J Laryngol Otol* 1999; 113(8):759-61.
9. Hadfield PJ, Motamed M, Glover GW. Synergistic necrotizing cellulitis resulting from peri-tonsillar abscess. *J Laryngol Otol* 1996; 110(9):887-90.
10. Marioni G, Bottin R, Tregnaghi A, Boninsegna M, Staffieri A. Craniofacial necrotizing fasciitis secondary to parotid gland abscess. *Acta Otolaryngol* 2003; 123(6):737-40.
11. Feinerman IL, Tan HK, Roberson DW, Malley R, Kenna MA. Necrotizing fasciitis of the pharynx following adenotonsillectomy. *Int J Pediatr Otorhinolaryngol* 1999; 48(1):1-7.
12. Banerjee AR, Murty GE, Moir AA. Cervical necrotizing fasciitis: a distinct clinicopathological entity? *J Laryngol Otol* 1996; 110(1):81-6.
13. Becker M, Zbaren P, Hermans R, Becker CD, Marchal F, Kurt AM, Marre S, and others. Necrotizing fasciitis of the head and neck: role of CT in diagnosis and management. *Radiology* 1997; 202(2):471-6.
14. Lin C, Yeh FL, Lin JT, Ma H, Hwang CH, Shen BH, and other. Necrotizing fasciitis of the head and neck: an analysis of 47 cases. *Plast Reconstr Surg* 2001; 107(7):1684-93.
15. Ahrenholz DH. Necrotizing soft tissue infections. *Surg Clin North Am* 1988; 68(1):199-214.
16. Bahu SJ, Shibuya TY, Meleca RJ, Mathog RH, Yoo GH, Stachler RJ, and other. Craniofacial necrotizing fasciitis: an 11-year experience. *Otolaryngol Head Neck Surg* 2001; 125(3):245-52.
17. Gozal D, Ziser A, Shupak A, Ariel A, Melamed Y. Necrotizing fasciitis. *Arch Surg* 1986; 121(2):233-5.
18. Riseman JA, Zambone WA, Curtis A, Graham DR, Konrad HR, Ross DS. Hyperbaric oxygen therapy for necrotizing fasciitis reduces mortality and the need for debridements. *Surgery* 1990; 108(5):847-50.
19. Shupak A, Shoshani O, Goldenberg I, Barzilai A, Moskuna R, Bursztein S. Necrotizing fasciitis: an indication for hyperbaric oxygen therapy? *Surgery* 1995; 118(5):873-8.
20. Yong JM. Necrotizing fasciitis [letter]. *Lancet* 1994; 343(8910):1427.
21. Skitarelic N, Mladina R, Morovic M, Skitarelic N. Cervical necrotizing fasciitis: sources and outcomes. *Infection* 2003; 31(1):39-44.