

Clinical Showcase

Anterior Resin Crowns in Special Needs Patients

Dr. Charlie Inga, DDS

Esthetic-type anterior resin crowns have been used in the general pediatric population for many years, but unfortunately, much less so in the special needs population. This article presents the case of a special needs patient who received anterior resin crowns, outlining the steps taken to create beautiful and long-lasting esthetic restorations.

Full coronal restorations of carious primary incisors are indicated when caries are present on multiple surfaces; the incisal edge is involved; there is extensive cervical decalcification; pulpal therapy is indicated; and caries are minor but the patient's oral hygiene is very poor, resulting in a high caries risk. In selected cases, permanent incisors have also been beautifully restored and esthetic results achieved without the need for an impression, laboratory models or follow-up for insertion of crowns or veneers.

General anesthesia is used for the special needs patients

in our clinic who require extensive dental restorations. This provides optimal conditions for the placement of anterior resin crown restorations. However, these restorations have also been placed on select, cooperative patients without the use of anesthesia.

Anterior resin crowns are an attractive first choice for many clinicians, but they are very technique-sensitive. Hemorrhage or saliva contamination on the tooth will interfere with the bond, causing the restoration not to adhere and to subsequently fail. Thorough and complete rubber dam isolation of the teeth is necessary to create an ideal bonding environment for placement of successful long-term restorations. The following clinical steps and photographs are intended as a guide to restoring teeth with anterior resin crowns.

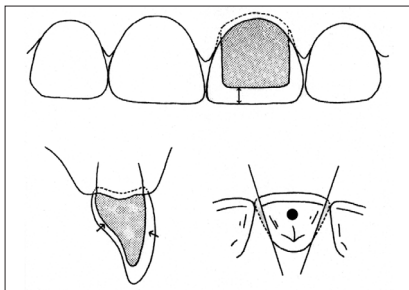


Figure 1: Illustration of anterior resin crown preparation. The amount of tooth structure removed will depend on the individual tooth and decay levels.

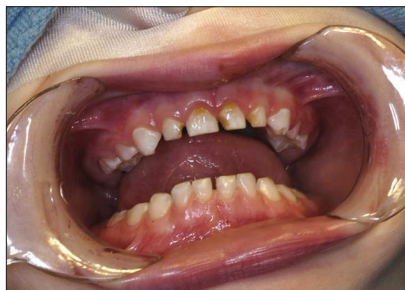

Figure 2: A 5-year-old patient with developmental delay needed extensive dental rehabilitation under general anesthesia, including anterior restorations. His mother did not want stainless steel crowns on the anterior teeth.

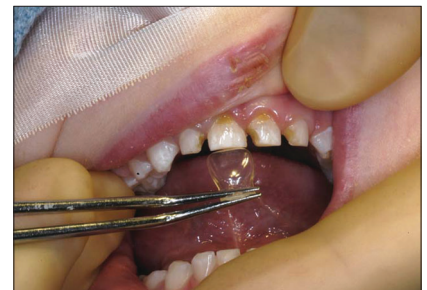

Figure 3: Shade selection should take place before the tooth is isolated. The width of the tooth is also noted, such that an appropriate crown form can be chosen.



Figure 4: The quadrant is isolated using a rubber dam with the smallest holes possible, placing an Ivory 212 clamp on tooth 51 and inverting the dam around the tooth being worked on.

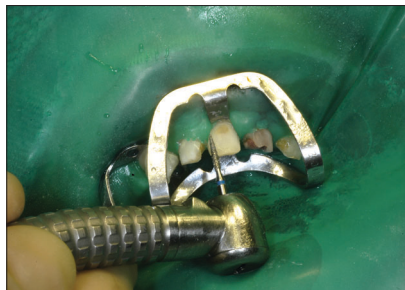


Figure 5: Removal of tooth structure (see Box 1).

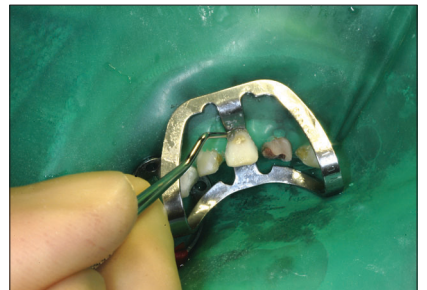

Figure 6: Decay is removed with round burs and spoon excavators. Pulpal therapy or protection is provided at this time.

Box 1 Removal of tooth structure

The incisal surface is reduced by 1.5–2.0 mm with a tapered diamond bur. The facial surface is reduced beginning with a feather edge at the gingival surface and progressively deeper as the preparation extends toward the incisal surface, to a depth of 0.5–1.0 mm. The lingual surface is reduced with a football-shaped diamond bur by about 0.5 mm. The interproximal areas are reduced with a tapered diamond bur by approximately 0.5–1.0 mm and are parallel to one another. The recommended finish line is a feather edge that should end midway in the gingival sulcus. All line angles are rounded.

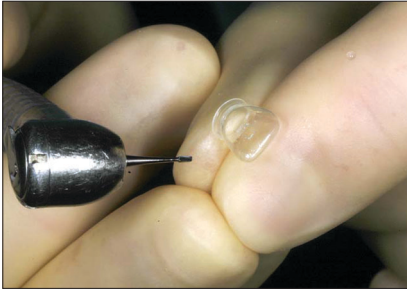


Figure 7: Previously chosen crown form that most accurately represents the desired mesiodistal width of the tooth. From the lingual surface, an air vent is placed on the cingulum area with a bur or sharp explorer to allow air to escape, preventing the formation of voids in the composite. The air vent also helps to position the crown correctly, which is extremely important when seating multiple crowns (prevents facial and lingual switching).

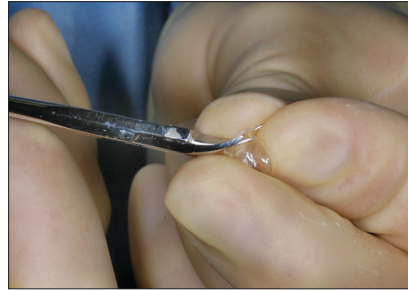

Figure 8: Gingival excess is trimmed with crown and collar shears or fine-tipped scissors. The crown form is then ready to be checked on the tooth.

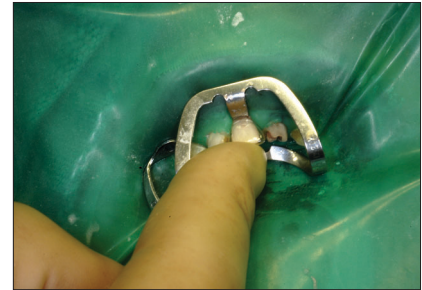

Figure 9: The crown form should extend approximately 0.5–1.0 mm below the finish line. The height should be of appropriate incisal length to yield a natural-appearing tooth. If the length is slightly longer, it can be corrected when finishing the composite. The critical fit is at the gingival surface. The crown form should be trimmed to appropriate cervical length and should fit snugly but not too tightly.

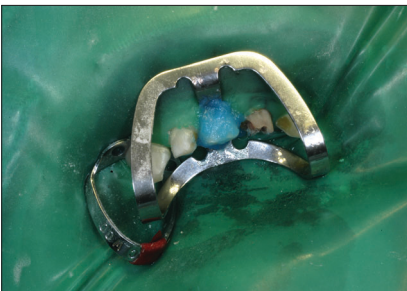

Figure 10: The tooth structure is prepared for the composite. The tooth is etched and the bonding agent placed.

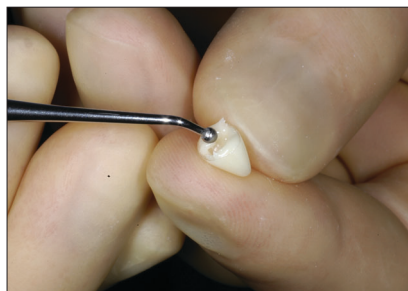


Figure 11: The crown is filled approximately two-thirds full with composite resin. Pushing the composite to all corners of the crown form will help prevent the formation of voids or pockets of air.

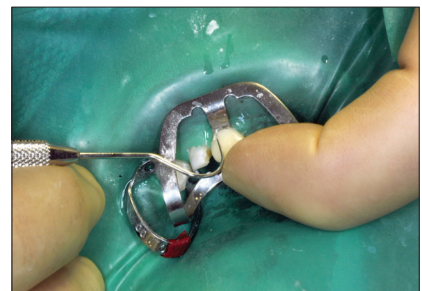

Figure 12: The crown form filled with composite is placed on the tooth, confirming the snug fit around the gingival margin. Excess material should flow from the gingival margin and vent hole. The crown is then held in place and the excess material removed.



Figure 13: The composite material is cured as recommended by the manufacturer. The light source should be placed on the facial, lingual and incisal surfaces.

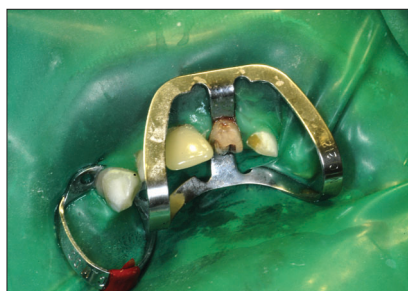

Figure 14: The Ivory 212 clamp is moved to tooth 61. The tooth is prepared and a pulpotomy started.

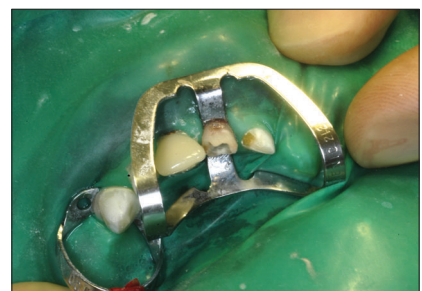

Figure 15: The pulp chamber is filled with zinc-oxide eugenol (ZOE) pulp paste. The ZOE material prevents the composite from curing if left on the tooth preparation.

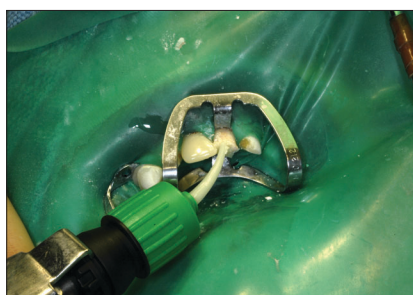

Figure 16: Fuji glass-ionomer liner (GC Amercia, Alsip, Ill.) is placed and cured. The liner can be etched with the tooth preparation for bonding of the composite crown to the tooth.

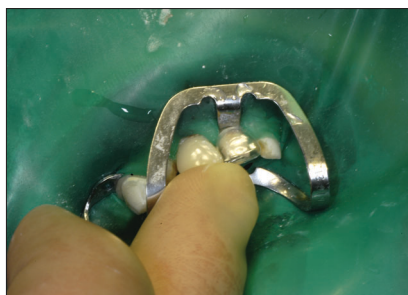

Figure 17: The crown form filled with composite is placed and cured following the same steps as previously described.

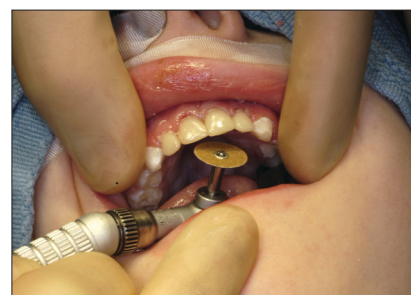

Figure 18: The anterior teeth have now been cured and are ready for finishing. The anterior resin crown forms will need to be removed. This is done by using sandpaper discs on the lingual vent holes, which causes the crown form to thin.

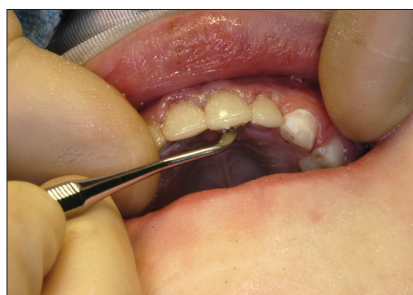

Figure 19: Carefully slitting the material with an instrument will help peel off the crown.

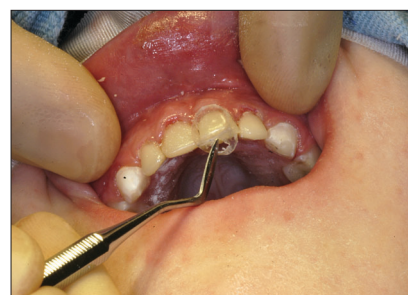

Figure 20: The crown form is removed.

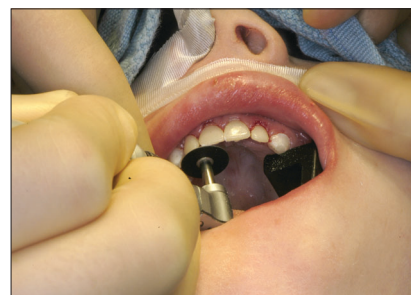

Figure 21: After removing the crown forms, occlusion and contour must be evaluated and adjusted as necessary with finishing burs and abrasive discs. It is not necessary to finish the facial surface of the restoration. When the composite polymerizes in contact with the crown form, it creates a great finish.

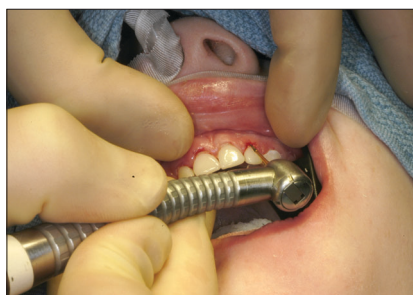

Figure 22: The marginal fit must be verified. Overhangs can be removed with composite finishing burs.

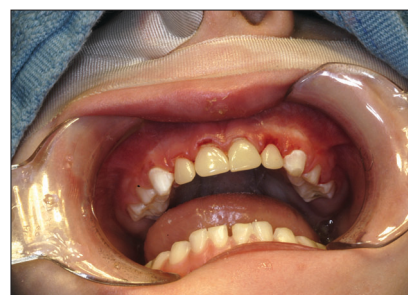

Figure 23: Esthetic anterior teeth restorations both parent and child are happy with.

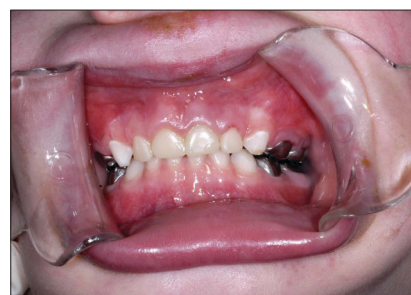

Figure 24: At one-week follow-up, the child is doing well and brushing well.

Esthetic dentistry can be performed on special needs patients. We treated and followed up with many medically compromised patients at Texas Scottish Rite Hospital for Children, where more than 130 anterior resin crowns were placed over the past 4 years. The crowns look as good now as on the day they were placed. With their child's smile looking better, parents become more motivated about the issue of oral hygiene and adopt a more positive attitude about their child's oral health. ✦



Dr. Charlie Inga is the assistant director at Texas Scottish Rite Hospital for Children, and is an assistant professor in the department of pediatric dentistry at Texas A&M University Health Science Center/Baylor College of Dentistry, Dallas, Texas. He has no declared financial interests in any company manufacturing the types of products mentioned in this article.

Correspondence to: Dr. Charlie Inga, 2222 Welborn St, Dallas, TX 75219. E-mail: cinga@tsrh.org.

Dr. Inga's session at the joint SCD/IADH congress, "Anterior resin crowns in special needs patients" is part of the Lunch & Learn event scheduled for Thursday, August 26.