

Intentional Angulation of an Implant to Avoid a Pneumatized Maxillary Sinus: A Case Report

- Terry J. Lim, DMD, Dip Prosth, FRCD(C) •
- Anna Csillag, DDS, Dip Oral Rad, FRCD(C) •
- Tassos Irinakis, DDS, Dip Perio, MSc •
- Adi Nokiani, BSc, DMD •
- Colin B. Wiebe, DDS, Dip Perio, MSc, FRCD(C) •

A b s t r a c t

This case report describes placement of an implant in the posterior maxilla so as to avoid a pneumatized sinus and also to avoid the need for a sinus lift procedure. An 81-year-old woman presented with an edentulous span in the upper right posterior maxilla. She had been missing teeth in this area for many years, and there was a combination of resorption of the alveolar ridge and pneumatization of the maxillary sinus. Eleven years previously, implants had been placed anterior to this region, but the patient was told that implants could not be placed posteriorly unless a sinus lift was done. At the time of the current presentation she was still unwilling to undergo a sinus lift procedure but wanted to know if implants could be placed in the posterior right maxilla. A tomogram obtained with a radiographic stent in place indicated that there was insufficient bone height to allow placement of implants at the usual angulation without a sinus lift. Therefore, to avoid the need for a sinus lift, 2 implants were placed with palatal angulation as guided by a tomographically determined surgical stent. The treatment planning and surgical and restorative techniques are reviewed here. A postoperative tomogram was obtained to determine the final position of the implants. The outcome has been favourable for the patient and the clinicians. In situations where there is sufficient palatal bone medial to the maxillary sinus, placing implants at an angle may prevent the need for a sinus lift procedure, assuming that proper development of an occlusal restorative scheme is possible.

MeSH Key Words: dental implantation, endosseous/methods; dental prosthesis design; maxilla/surgery; tomography, x-ray computed

© J Can Dent Assoc 2004; 70(3):164–8
This article has been peer reviewed.

The presence of a pneumatized maxillary sinus is often a contraindication to the placement of osseointegrated implants in the posterior maxillary segments without prior surgical procedures, such as onlay-type maxillary ridge augmentation,¹ sinus lift techniques^{2,3} and the less invasive osteotome technique.⁴ These techniques have yielded good success rates, although many patients are hesitant to undergo them because they are perceived as invasive.^{5,6} In the case of the sinus lift, complications may occur,^{7,8} and the 2-stage technique that is often employed lengthens treatment time by 6 to 12 months (the period needed for the bone graft to be incorporated). Patients are more likely to accept overall treatment that avoids the need for a sinus lift.

Case Report

An 81-year-old woman presented with a request for placement of osseointegrated implants in the second premolar and molar sites of the right maxilla. She was taking medication for hypertension (irbesartan), hormone replacement therapy (conjugated equine estrogen) and osteoporosis (etidronate). She had smoked for 35 years but had quit 25 years previously. All teeth on the right maxilla other than the central incisor had been missing for 20 years. Eleven years previously 2 implants had been placed in the right lateral incisor and cuspid positions (Fig. 1). The implant in the maxillary right cuspid location was angulated distally, which prevented future placement of an implant in the first premolar site (Fig. 2). The implants had been placed in the existing ridge, which had subsequently

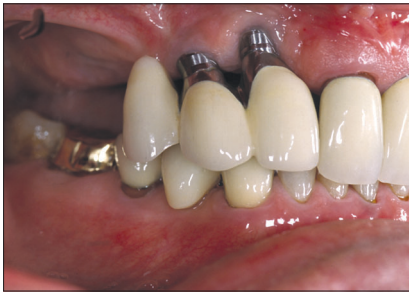

Figure 1: Implants placed in the site 12 and 13 region of an 81-year-old woman 11 years previously. The angled abutment was an esthetic concern, and there was a cantilever pontic at site 14.

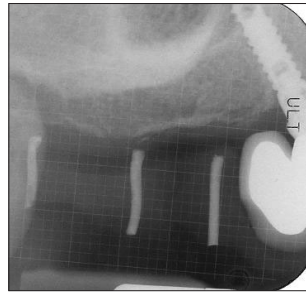


Figure 2: Periapical radiograph of the site 13 implant, which is distally angulated into site 14. A grid shows lack of bone height at sites 15 and 16.

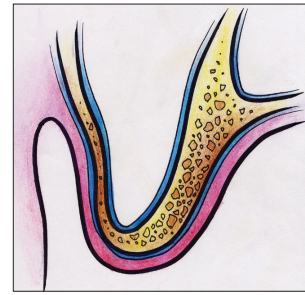


Figure 3a: Diagram of the bone located inferior to the right maxillary sinus.

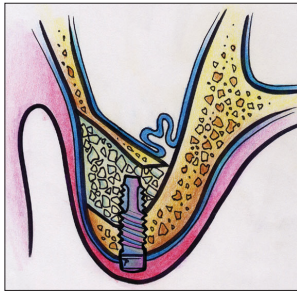

Figure 3b: Diagram of the traditional sinus lift procedure.

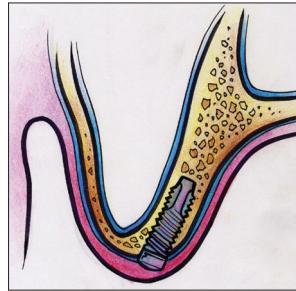


Figure 3c: Diagram of the implant angulation strategy employed in this case to avoid a sinus lift procedure.

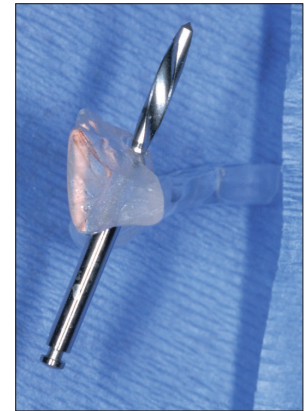


Figure 4: Radiographic and surgical stent. The drill is positioned at 31°.

resorbed; the result was palatal positioning that necessitated an angled abutment to restore the teeth in non-crossbite occlusion. The metal of the abutments were apparent when she smiled, although she was not concerned about this esthetic compromise. The implants in sites 12 and 13 had been restored by splinting them together and adding a cantilever pontic at site 14.

The patient was happy with her previous implant therapy but desired more posterior teeth on the right maxilla. At the time of the initial implant treatment she had been told that posterior implants could not be placed unless a sinus lift was done first. She had declined the sinus lift at that time and had proceeded with the site 12 and 13 implants. She was now hopeful that new types of implants or techniques might allow her to have posterior teeth without undergoing a sinus lift. Tomography performed with a radiographic stent in place revealed 4 to 6 mm of vertical bone height from the crest of the ridge to the floor of the sinus. Interestingly the tomograms also showed a thick palatal wall from the medial wall of the sinus to the hard palate, and it was decided to use the palatal bone rather than elevating the sinus (Figs. 3a to 3c).

Preoperative Evaluation

A radiographic stent with gutta-percha markers was used for the tomographic scan. The most incisal point of the

gutta-percha marker over the desired implant site was used as a reference point (Fig. 4). To accommodate the implant into the medial wall of the sinus, angulation of 31° for the tooth 15 implant and 30° for the tooth 16 implant was necessary. A protractor was used to draw lines on the stent at the necessary angles for each corresponding marker. A 2-mm twist drill (Nobel Biocare, Göteborg, Sweden) was then used to hollow out the stent at the necessary angles. The surgeon could then use the predrilled angles in the stent to guide both the pilot drill and the 2-mm twist drill.

A Comm-Cat IS-2000 complex-motion tomographic unit (Imaging Sciences International, Hatfield, Pa.) was used for tomographic evaluation of the area of missing teeth 14, 15 and 16. A tomographic stent with gutta-percha markers intimately adapted to the buccal surfaces of the teeth at the proposed sites of implantation was in place during the imaging. A maxillary vertex view was obtained and scanned into the computer. This initial image of the maxillary vertex, along with scout images, helped in selecting the angle of the cross-sectional cuts to yield accurate anatomic information. Special care was taken to align the tomographic plane (layer) perpendicular to the alveolar process.

Slice thickness was set at 2 mm for the cross-sectional images and 15 mm for the sagittal (reference) views. The magnification was 26% throughout (Grossman technique).

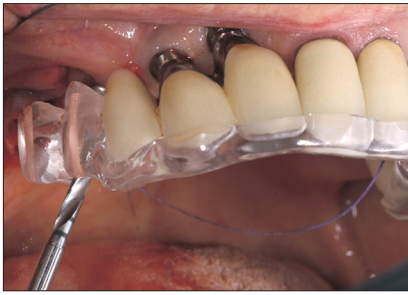


Figure 5a: With the surgical stent in place, the osteotomy was performed according to angulation determined from the tomograms.

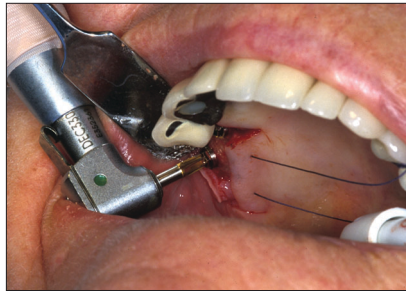

Figure 5b: Insertion of the implant.

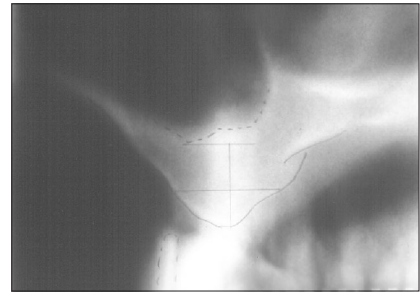


Figure 6a: Pretreatment tomogram of site 15.

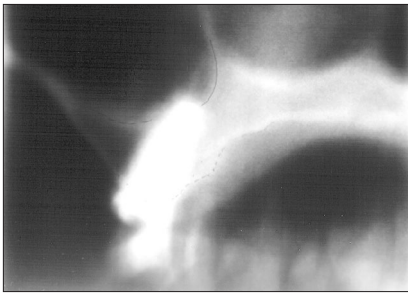


Figure 6b: Post-treatment tomogram of site 15. There is minor penetration at the superior extent of the implant.

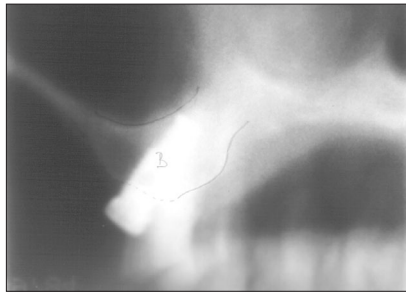


Figure 6c: Post-treatment tomogram of site 16.

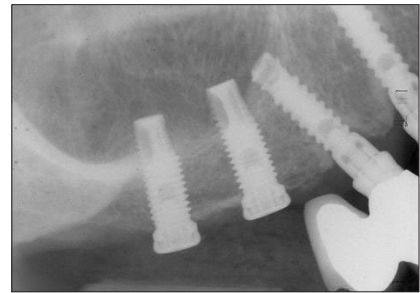


Figure 6d: Final periapical radiograph before restorative treatment was initiated.

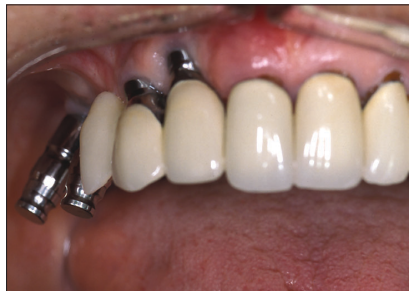

Figure 7: Angulation of pick-up impression copings used to create the master cast.

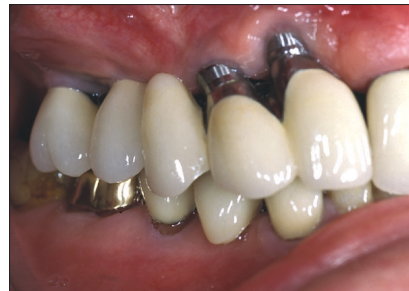

Figure 8: Final prosthesis 6 months after placement.

Hypocycloidal motion was used for both the cross-sectional and sagittal views. During scanning, a cross-sectional tomogram was obtained every 3 mm through the area of interest. The tomograms were traced, and height and width were measured for each individual slice. The height measurements were performed in the axial inclination as indicated by the tomographic markers (5.5 to 8.5 mm through the scanned area). The tomograms revealed that the cortices were well defined and of nearly uniform thickness. The cancellous bone was of relatively lower density, consisting of smaller marrow spaces and a regular trabecular network.

The extent of the maxillary sinus was evaluated in the sagittal plane and in the bucco-palatal direction. This structure appeared to occupy the buccal portion of the alveolar process, with sufficient bone remaining between the medial part of the maxillary sinus and the palatal aspect of the alveolar process.

Mild thickening of the mucosal lining, parallel to the floor of the maxillary sinus, was noted; this was most likely of infectious or allergic origin. No significant buccal or palatal resorption of the alveolar process was observed, and the alveolar process was 11 to 13 mm wide in the area of interest.

Surgical Procedure

A full-thickness crestal incision was made from site 14 distal to the 17 area, with small releasing incisions to the buccal and palatal surfaces (on both the mesial and distal extent of the flap; **Figs. 5a** and **5b**). The palatal flap was held in a retracted position by a suture that encircled a bicuspid on the left maxilla. The radiographic stent was positioned, and a round bur was used to start the osteotomy; the standard 2-mm twist drill was then used in the Brånemark implant system (Nobel Biocare). A standard osteotomy was prepared with the pilot drill and 3-mm twist

drills, along with direction indicators and depth gauges. Two Brånemark Mark III implants (11.5 mm × 3.75 mm diameter; Nobel Biocare) were placed at sites 15 and 16. Bone quality was classified as type 3. Cover screws were placed, and the incision was closed with interrupted 4-0 sutures. The patient attended postoperative appointments at 3 weeks and 2 months. At 4 months the implants were uncovered and 3-mm healing abutments were placed.

Before the restorative phase of treatment was initiated, new tomograms were obtained to confirm the position of the implants relative to the maxillary sinus and the palatal wall. The scanning parameters for the postsurgical tomographic evaluation were the same as for the initial evaluation. Both implants appeared to be well integrated, with no perifixtural bone loss. The implants were positioned at a palatal axial inclination, between the inferior and medial wall of the maxillary sinus and the palatal cortex of the alveolar process (Figs. 6a to 6d). The most superior part of the implant at site 15 appeared to have minor penetration into the air space of the maxillary sinus, but no mucosal reaction was noted at the site of perforation.

Restorative Procedure

Because of the severe angulation of each implant (31° from the long axis of the marker), an initial transfer impression was taken, with transfer impression copings (3i Implant Innovations Inc., Palm Beach Gardens, Fla.) being used to locate the implants. A custom tray was then fabricated and a final pick-up impression, with pick-up impression copings (3i Implant Innovations Inc.), was used to create the master cast (Fig. 7). Custom abutments were used to correct the angulation, which was then tried in to verify implant position intraorally and the positions on the master cast. A pattern resin index (GC Corporation, Tokyo, Japan) was used to maintain the relation between the 2 custom abutments. After verification of the fit of the abutments, a new occlusal registration was taken, and final crowns, consisting of porcelain fused to metal, were fabricated. The prosthesis was tried in and then cemented in with TempBond (Kerr Corporation, Romulus, Mich.) (Fig 8).

Conclusions

The posterior maxilla often loses horizontal bone from the buccal aspect, this resorption being most evident in the first year after extraction of the teeth and slowing thereafter.^{9,10} As a result, the maxilla may develop a crossbite tendency with the existing mandible, which may create problems for development of the final occlusal scheme during definitive restoration. The success of using angulated abutments in this situation is well established.^{11,12} In the case reported here, angulated abutment and cemented crowns were used to correct the 31° angulation of the 2 implants.

The osteotome technique requires sufficient initial bone height and seems more appropriate for single implants. In this case there was probably sufficient bone height for initial fixation. However, the osteotome technique was not used because the 2 implants were being placed adjacent to one another and the more vertical angulation of the implants, combined with the palatal direction of maxillary bone resorption, would have necessitated facial correction, as was the case for the previously restored site 12 and 13 implants.

The positioning of the 2 implants was planned so that the head of each implant exited the alveolar ridge near the functional cusps of the mandibular teeth. Correction of the 31° angulation of the implants allowed the crowns to be fabricated such that a crossbite was avoided. Although appearance was not of major concern to the patient, the use of custom abutments yielded superior esthetic appearance anteriorly (relative to the original fixed-bridge implant). The custom abutments also eliminated the access hole that is used in screw-retained restorations. The use of the angulated implants also helped the patient to accept the treatment because it addressed her desire to avoid intrusion into the right maxillary sinus with either a sinus lift procedure or the osteotome technique. Although the osteotome technique can be effective, the angulated implant in the medial wall of the sinus offers both the surgeon and the prosthodontist an alternative to traditional implant placement in this location. ♦



Dr. Lim is in full-time specialist private practice in prosthodontics in Calgary, Alberta.



Dr. Csillag is in full-time specialist private practice in oral and maxillofacial radiology in Calgary, Alberta.



Dr. Irinakis is a full-time clinical assistant professor at the University of British Columbia, Vancouver. He is also in part-time private practice in periodontics in Vancouver.



Dr. Nokiani has recently completed his DMD training at the University of British Columbia in Vancouver.



Dr. Wiebe is in full-time specialist private practice in periodontics in Calgary, Alberta. He is also a part-time clinical assistant professor at the University of British Columbia, Vancouver.

Correspondence to: Dr. Tassos Irinakis, Faculty of Dentistry, University of British Columbia, 2199 Wesbrook Mall, Vancouver, BC V6T 1Z3. E-mail: irinakis@interchange.ubc.ca.

The authors have no declared financial interests in any company manufacturing the types of products mentioned in this article.

References

1. Nevins M, Jovanovic SA. Localized bone reconstruction as an adjunct to dental implant placement. *Current Opin Periodontol* 1997; 4:109–18.
2. Tatum H. Maxillary and sinus implant reconstruction. *Dent Clin North Am* 1986; 30(2):207–29.
3. Garg AK. Augmentation grafting of the maxillary sinus for placement of dental implants: anatomy, physiology, and procedures. *Implant Dent* 1999; 8(1):36–46.
4. Summers RB. The osteotome technique: Part 3 — Less invasive methods of elevating the sinus floor. *Compendium* 1994; 15(6):698–700, 702–4.
5. Tong DC, Rioux K, Drangsholt M, Beirne OR. A review of survival rates for implants placed in grafted maxillary sinuses using meta-analysis. *Int J Oral Maxillofac Implants* 1998; 13(2):175–82.
6. Olson JW, Dent CD, Morris HF, Ochi S. Long-term assessment (5 to 71 months) of endosseous dental implants placed in the augmented maxillary sinus. *Ann Periodontol* 2000; 5(1):152–6.
7. Doud Galli SK, Lebowitz RA, Giacchi RJ, Glickman R, Jacobs JB. Chronic sinusitis complicating sinus lift surgery. *Am J Rhinol* 2001; 15(3):181–6.
8. Regev E, Smith RA, Perrott DH, Pogrel MA. Maxillary sinus complications related to endosseous implants. *J Oral Maxillofac Implants* 1995; 10(4):451–61.
9. Cawood JI, Howell RA. A classification of the edentulous jaws. *Int J Oral Maxillofac Surg* 1988; 17(4):232–6.
10. Tallgren A. The continuing reduction of the residual alveolar ridges in complete denture wearers: a mixed longitudinal study covering 25 years. *J Prosthet Dent* 1972; 27(2):120–32.
11. Asikainen P, Klemetti E, Vuillemin T, Sutter F, Rainio V, Kotilainen R. Titanium implants and lateral forces — an experimental study with sheep. *Clin Oral Implants Res* 1997; 8(6):465–8.
12. Celletti R, Pameijer C, Cornelis H, Bracchetti G, Donath K, Persichetti G, and other. Histologic evaluation of osseointegrated implants restored in nonaxial functional occlusion with preangled abutments. *Int J Periodontics Restorative Dent* 1995; 15(6):562–73.