

Clinical Showcase

Clinical Showcase is a series of pictorial essays that focus on the technical art of clinical dentistry. This section features step-by-step case demonstrations of clinical problems encountered in dental practice. This month's article is by Dr. Pierre Boudrias, one of the featured speakers at the 2004 Pacific Dental Conference, presented in partnership with the Canadian Dental Association. The conference will take place in Vancouver, B.C., from March 4 to 6. If you would like to propose a case or recommend a clinician who could contribute to Clinical Showcase, contact editor-in-chief Dr. John O'Keefe at jokeefe@cda-adc.ca.

Anterior Single-Tooth Implant Restorations: Clinical Rules for Reducing Risk Factors

Pierre Boudrias, DMD, MSD

Implant restoration is traditionally used in clinical situations where healthy teeth are adjacent to an edentulous space and one or more diastema.¹ Today, this restorative approach is commonly used. The implant placement protocol has been simplified, and loading concepts have been enhanced.^{2,3} A well-recognized technique involves the simultaneous placement of the implant and healing abutment in good quality bone, which reduces patient discomfort and the risks of unattractive gingival scarring that could occur during the second surgical phase (subsequent placement of the healing abutment).

However, the placement of an implant without first carefully examining the periodontium, the condition of the teeth and the intensity of occlusal contacts may have

unfortunate mechanical and esthetic consequences.⁴ This article summarizes the preoperative evaluation criteria for single-tooth implant restorations and lists clinical pitfalls to avoid.

Practical Tips: Planning and Treatment

When planning a restorative implant, surgical and restorative considerations must be looked at in tandem. These considerations apply to both external hex implants and internally connected implants. **Table 1** lists the primary contraindications.

Here are a few practical tips that help in clinically evaluating single-tooth implant restorations and facilitating treatment:

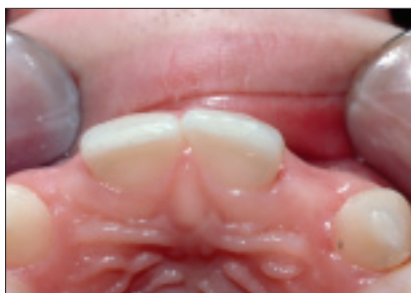

Figure 1a: Congenitally missing teeth 12 and 22.

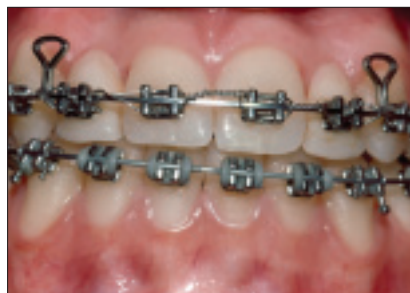

Figure 1b: Orthodontic treatment to correct the position of the teeth and open edentulous spaces.

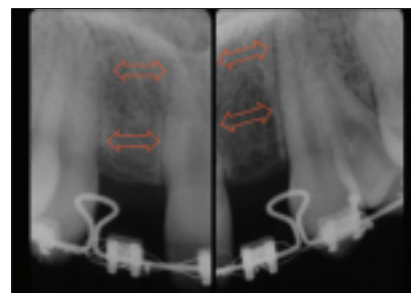


Figure 1c: Evaluation of the position of the roots for implant placement. Orthodontic correction would move the teeth to create a usable edentulous space.

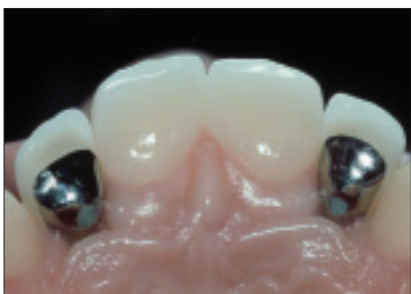

Figure 1d: Lingual orifice filled with a resin composite.

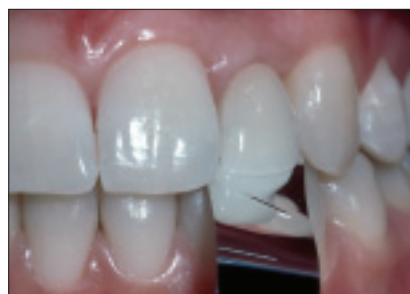

Figure 1e: Verification of occlusal contacts using shimstock.

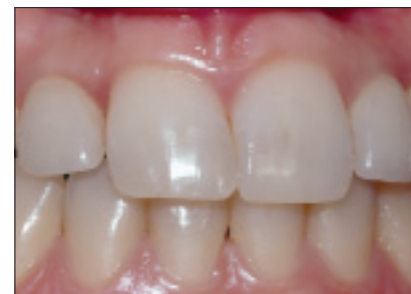

Figure 1f: Clinical appearance of dentogingival complex 11 years after insertion of the crowns on teeth 12 and 22.

Clinical Showcase

- The replacement of a congenitally absent tooth (missing lateral incisors) by an implant-supported crown is a long-lasting treatment that is less invasive for the adjacent teeth, but one that often requires orthodontic correction (Figs. 1a to 1g). To ease the placement of the implant, the teeth must be moved to create an upper mesiodistal edentulous space of 6 mm without producing root convergence of the adjacent teeth (Fig. 2). The orthodontic treatment must be finalized before placement of the implant. When the edentulous space is larger than the contour of the future restoration, a crown with diastema(s) may be the appropriate choice of restorative treatment (Fig. 3). In this clinical situation, a surgical guide is made from a diagnostic wax-up in order to insert the implant at the exact position defined on the diagnostic cast.⁵
- The placement of an implant must be postponed until after growth.⁶ During this time, several changes occur in

the dental arch, resulting in 3-dimensional changes in the position of the teeth. These changes may lead to occlusal interference and poor positioning of the teeth in relation to that of the implant. Therefore, an implant, especially in the esthetic zone, should not be considered until a girl reaches 15 years of age and a boy reaches 17 years of age (Fig. 4).

- The absence of gingival papilla is an esthetic handicap. A periodontal probe should be used to measure the height between the summit of the osseous crest and the interproximal contact (Fig. 5). A distance equal to or less than 5 mm would ensure optimal healing and re-establishment of the gingival papilla after placement of the implant.⁷ This rule applies specifically to triangular central incisors having interproximal contacts on the incisal third of the tooth (Fig. 6). Rectangular or square teeth are however easier to deal with esthetically.

Table 1 Surgical and Restorative Contraindications

Surgical contraindications	Restorative contraindications
Low bone volume (quality and contour)	Mesiodistal width of edentulous space < 6 mm
Proximity of anatomical structures	Insufficient interocclusal space
Insufficient gingival morphology	Overly high occlusal intensity (pronounced vertical overjet)
Root convergence	Extensive or defective restorations of adjacent teeth (poor prognosis)
Poor general and periodontal prognosis of adjacent teeth	Poor oral hygiene

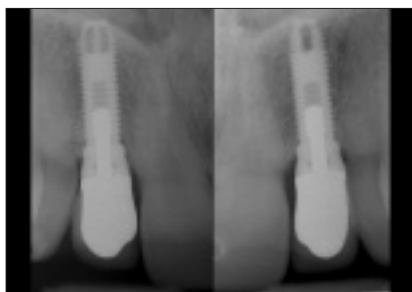

Figure 1g: Radiologic evaluation of implant-supported restorations 11 years after insertion of the crowns (zinc phosphate cement).

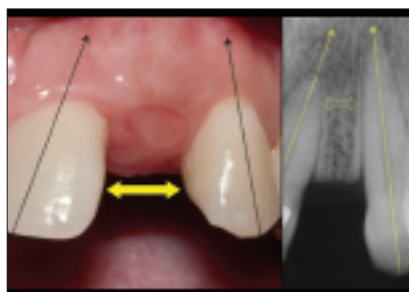


Figure 2: Sufficient intercoronal space and insufficient interradicular space.

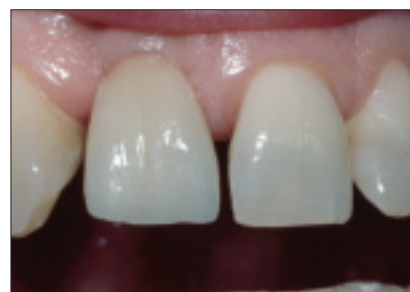

Figure 3: Preserved diastema. Cemented implant-supported restoration on tooth 11.

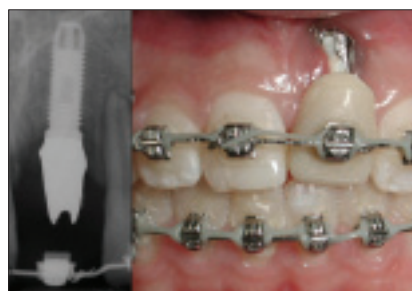

Figure 4: An implant placed in a patient who is too young will lead to an unattractive crestal defect and inadequate positioning of the implant following growth.

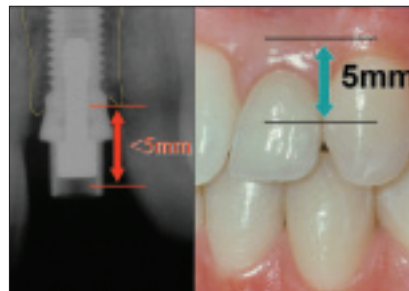


Figure 5: A 5-mm space between the interproximal contact and the osseous crest is ideal in order to preserve the gingival papilla.

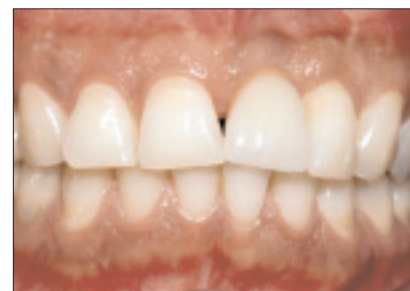

Figure 6: Gingival embrasures from triangular incisors with interproximal contact at the incisal third are difficult to fill in (cemented implant-supported restoration on tooth 21).

A new implant (Perfect, Nobel Biocare) with interproximal scallops appears promising for preserving the height of interproximal osseous crests during an immediate placement procedure with this type of implant (Fig. 7).⁸

- The esthetic quality of the implant restoration depends on the morphology of the edentulous crest. Having an osseous crest with adequate volume (height and thickness) is critical for placing an implant along an appropriate longitudinal axis. Keratinized gingiva with good morphology contributes to the natural, esthetic appearance of the restoration. Labial concavity may be caused by low bone volume or gingival thickness. In this case, a bone and/or gingival graft is indicated.⁹⁻¹¹ There are 3 methods of evaluating bone volume: visual analysis and palpation, sagittal computed tomography using a radiopaque medium (scanner)¹² and bone survey with ridge mapping.¹³ The bone survey with ridge mapping allows reproduction of the sagittal bone profile on a diagnostic cast (Figs. 8a and 8b). If any doubt remains, a scanner will accurately confirm the contour of the osseous crest (Fig. 9).
- An edentulous crest with sufficient bone volume will enable the clinician to place the implant with an acceptable longitudinal axis. In a sagittal plane, this

longitudinal axis must pass through the restoration somewhere between the incisal edge area and the middle third of the lingual surface¹⁴ (Fig. 10). An overly labial or lingual longitudinal axis would definitely lead to restorative problems. A rule of thumb for a maxillary incisor involves ensuring that the prosthetic parts appear on the lingual side of an imaginary straight line that joins the labial surfaces of the adjacent teeth to the edentulous space.

- The implant must be sunk 4 mm apically into the labiogingival margin in order to hide the metal collar (subgingival 2-mm collar) and to establish a cosmetically pleasing gingival profile around the crown (Fig. 11a). Here, the gingival morphology is very similar to that of an ogival pontic and is ideally created using a temporary restoration (Figs. 11b, 11c and 11d).
- Choosing the diameter of the implant is based on the area in the mouth where the implant will be used and the occlusal stress placed on the restoration, and not on bone mass. Implants that are 3.75 mm and 4 mm in diameter are generally appropriate for an anterior restoration. However, an implant with a small diameter (3.25 mm) may be used for maxillary lateral incisors and mandibular incisors, due to the lower intensity of

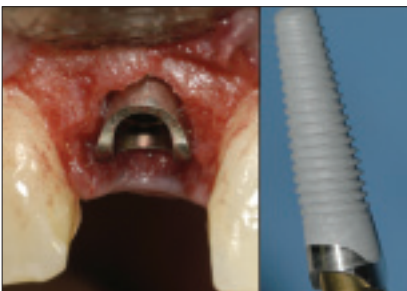

Figure 7: Tooth 12 was extracted and a scalloped implant inserted immediately. The interproximal scalloped sides with titanium oxide should help to maintain the height of the interproximal osseous crests (placement of the implant: Dr. Éric Morin).

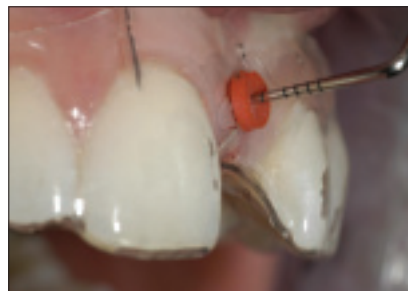

Figure 8a: The bone survey was performed at 3 points on the labial side and the palatal side, as well as 1 or 2 points at the summit of the edentulous crest using a measuring guide (acrylic stent).

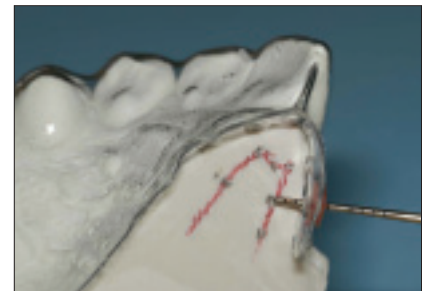


Figure 8b: The values obtained using the measuring guide are reproduced on a sagittal section of the diagnostic cast in order to draw the bone profile.

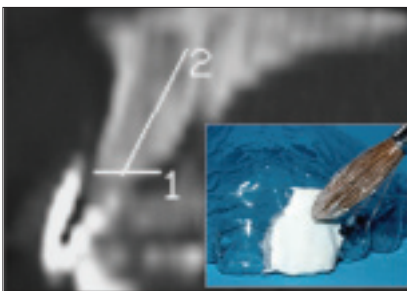


Figure 9: Bone volume can be evaluated using a scanner with radiopaque media (barium sulfate, gutta-percha point).

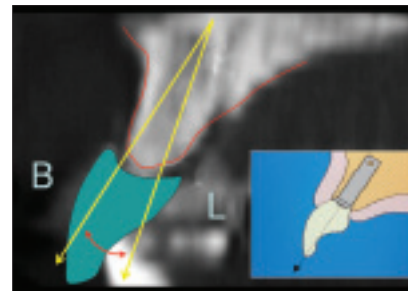


Figure 10: Sagittal scanner section and tracing indicating the acceptable limits of the longitudinal axis of the implant. The longitudinal axis must pass between the incisal edge and the middle third of the lingual surface.

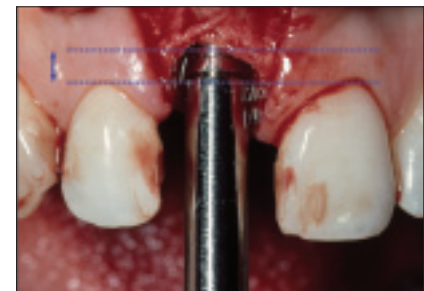


Figure 11a: The implant must be sunk to more than 4 mm apically to the gingival-labial margin (placement of the implant: Dr. Élise Shoghikian).

Clinical Showcase

the occlusal forces and lower risk of fracture.¹⁵ Lastly, the small diameter of these implants complicates an esthetic and harmonious emergence, especially in the case of maxillary central incisors.

- An impression can be made directly on the implant, and a master cast can be poured with an implant replica and flexible gingiva. Thus, choosing the abutment is far easier without the constraints of the oral environment (e.g., gingiva, saliva).

The longitudinal axis in the anterior zone often passes through the incisal edge of the crown because of the rectilinear shape of the implant (versus the convex shape of a tooth) and bone morphology. A crown cemented on an abutment is thus indicated since the insertion cavity for the prosthetic screw would leave an opening in the incisal edge (Figs. 12a and 12b). For a cemented crown, an opening is created in the lingual third of the framework of the ceramo-metal crown (Fig. 1d). This orifice is used as an evacuation channel to minimize the hydraulic pressure when cementing the crown (the zinc phosphate cement makes it easier to remove any excess cement lodged under the gingiva) and as an anchor if the crown should have to be removed later.¹⁶ This orifice is filled with a resin composite after the crown has been cemented.

A screw-retained crown (premachined UCLA cast onto abutment) can be made provided the longitudinal axis of the implant passes through the middle third of the lingual surface of the future crown without weakening the porcelain incisal third (Fig. 13). This restoration has the advantage of being completely reversible. The prosthetic screw is covered with a thin layer of friable material (white gutta-percha) and the access cavity on the lingual side is filled with a resin composite.

- The abutment screw is tightened using a torque wrench in accordance with the manufacturer's recommendations. The proximal contacts of a crown cemented on an abutment or of a screw-retained crown are adjusted to provide proper seating of both types of crowns. The occlusal contacts are then adjusted to maximum intercuspation laterally and protusively, during which the patient tightly clenches his or her teeth. It should be possible to pull a thin shimstock while feeling only slight friction at the occlusal points of contact (Fig. 1e). This serves to compensate for the missing periodontal membrane around the implant.

In conclusion, esthetic and functional success of a single-tooth implant restoration in the anterior zone requires meticulous clinical examination. The planning and treatment must involve the restorative dentist and surgeon, and quality technical work. ♦

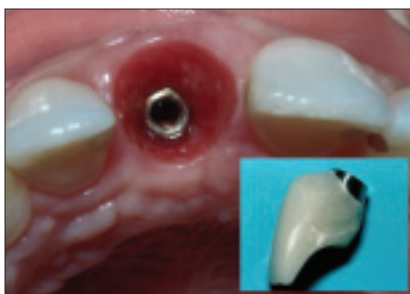

Figure 11b: Gingival morphology can be modified using a temporary implant-supported restoration.

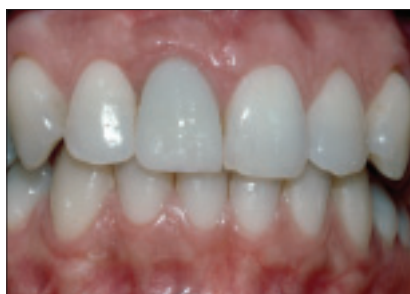

Figure 11c: Temporary screw-retained implant restoration on tooth 11.

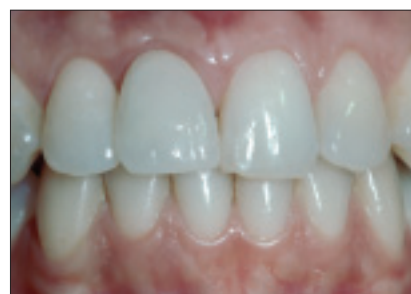

Figure 11d: Cemented ceramic implant-supported restoration on tooth 11.



Figure 12a: The Procera abutment (Nobel Biocare) enables the placement of the abutment/crown junction at the desired subgingival depth while following the shape of the interproximal gingival scallop.

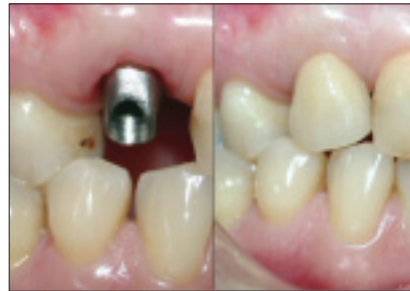

Figure 12b: The longitudinal axis of the implant passes through the incisal edge. The restoration is cemented on a Procera titanium abutment.

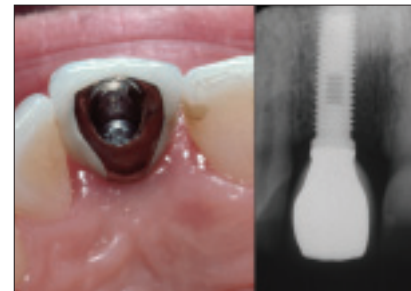


Figure 13: The longitudinal axis of the implant passes through the middle third of the lingual surface of a screw-retained restoration (premachined UCLA cast onto abutment).



Dr. Pierre Boudrias is a professor in the department of restorative dentistry and head of fixed prosthodontics at the University of Montreal. He teaches fixed partial prosthodontics and implantology and maintains a private practice at the university. Dr. Boudrias has no declared financial interest in any company manufacturing the types of products mentioned in this article.

Correspondence to: Dr. Pierre Boudrias, Faculty of Dentistry, University of Montreal, P.O. Box 6128, Downtown Station, Montreal, QC H3P 1J2. E-mail: pierre.boudrias@umontreal.ca.

Dr. Boudrias' seminar "Implant Restoration for the Partially Edentulous Patient: Practical Concepts and Case Presentations" will be presented on Thursday, March 4. For more information on the PDC/CDA conference, visit www.pacificdentalonline.com.

References

1. Laney WR, Jemt T, Harris D, Henry PJ, Krogh PH, Polizzi G, and others. Osseointegrated implants for single-tooth replacement: progress report from a multicenter prospective study after 3 years. *Int J Oral Maxillofac Implants* 1994; 9(1):49-54.
2. Glauser R, Gottlow J, Lundgren AK, Sennerby L, Portmann M, Ruhstaller P, and other. Immediate occlusal loading of Branemark system implant with TiUnite surface: histological evaluation after 6 months. *Applied Osseointegration Res* 2002; 3(1):25-8.
3. Becker W, Becker BE, Israelson H, Lucchini JP, Handelsman M, Ammons W, and others. One-step surgical placement of Branemark implants: a prospective multicenter clinical study. *Int J Oral Maxillofac Implants* 1997; 12(4):454-62.
4. Mazurat RD, Love WB, Pesun IJ. The role of the restorative dentist in the diagnosis and maintenance phases of implant therapy — Part II: Prosthetic planning. *J Can Dent Assoc* 1994; 60(9):814-8.
5. Koyanagi K. Development and clinical application of a surgical guide for optimal implant placement. *J Prosthet Dent* 2002; 88(5):548-52.
6. Oesterle LJ, Cronin RJ. Adult growth, aging, and the single-tooth implant. *Intern J Oral Maxillofac Implants* 2000; 15(2):252-60.
7. Tarnow DP, Magner AW, Fletcher P. The effect of the distance from the contact point to the crest of bone on the presence or absence of the interproximal dental papilla. *J Periodontol* 1992; 63(12):995-6.
8. Wohrle PS. Nobel Perfect esthetic scalloped implant: rationale for a new design. *Clin Implant Dent Relat Res* 2003; 5 Suppl 1:64-73.
9. Langer B. Soft tissue complications — the esthetic dilemma. *Int J Oral Maxillofac Implants* 2003; 18(5):767-8.
10. Simion M, Jovanovic SA, Tinti C, Benfenati SP. Long-term evaluation of osseointegrated implants inserted at the time or after vertical ridge augmentation. A retrospective study on 123 implants with 1-5 year follow-up. *Clin Oral Implants Res* 2001; 12(1):35-45.
11. Torrea AS, Fonseca DM, Jovanovic SA. Single-unit implant-supported restoration in the vertically deficient anterior maxilla. *Pract Periodontics Aesthet Dent* 1999; 11(5):571-5.
12. Weinberg LA. CT scan as a radiologic data base for optimum implant orientation. *J Prosthet Dent* 1993; 69(4):381-5.
13. Boudrias P. Evaluation of the osseous edentulous ridge (i.e. ridge mapping): probing technique using a measuring guide. *J Dent Québec* 2003; 40:301-2.
14. Engelman MJ. Clinical decision making and treatment planning in osseointegration. Chicago: Quintessence Publishing Co, Inc.; 1996. Chapter 6:81-100.
15. Rangert B, Sennerby L, Meredith N, Brunski J. Design, maintenance and biomechanical considerations in implant placement. *Dent Update* 1997; 24(10):416-20.
16. Okamoto M, Minagi S. Technique for removing a cemented superstructure from an implant abutment. *J Prosthet Dent* 2002; 87(2):241-2.