

Spontaneous Mandibular Fracture in a Partially Edentulous Patient: Case Report

- Philippe Libersa, DMD, PhD •
- David Roze, DMD •
- Thierry Dumousseau, MD •

A b s t r a c t

This article describes the case of a 78-year-old patient whose mandibular fracture was treated with miniplate osteosynthesis. After initial treatment, panoramic radiography revealed a fracture of the miniplate, and at follow-up, a loosening of the replacement plate. For the dental practitioner, this clinical case highlights the importance of panoramic radiography and occlusal analysis and stabilization for diagnosis of mandibular fracture, evaluation of miniplate fracture and treatment, especially in the absence of trauma.

MeSH Key Words: fractures, spontaneous/surgery; mandibular fractures; postoperative complications

© J Can Dent Assoc 2003; 69(7):428–30
This article has been peer reviewed.

The mandible is the most commonly fractured bone of the face because of its prominent and exposed position.¹ It is the only moving bone of the facial skeleton, and its physiological functions must be considered in the treatment of trauma.² The most common mechanisms of injury to this bone include motor vehicle crashes, falls, fights, sports injuries and removal of the third molar.³ Spontaneous fractures without an obvious cause are rare.

Treatment methods include closed reduction with maxillomandibular fixation (Gunning splint), closed reduction without maxillomandibular fixation, and open reduction and fixation with interosseous wires or screws and plates.⁴

This report presents a case of spontaneous mandibular fracture subsequent to placement of a new denture, as well as fracture of the miniplate used to reduce the original fracture.

Case Report

An almost totally edentulous 78-year-old man without a significant dental history was admitted to hospital with a large, hard edema in the left lateral mandibular area. Fifteen days before being admitted to hospital, the patient had consulted his dentist with pain and swelling of the left mandibular region. The only treatment provided by his

dentist at that time was a course of antibiotics, which had been ineffectual.

Clinical examination revealed impaired function and mobility, as well as severe edema.

Panoramic radiographic examination showed a displaced mandibular fracture and bone radiolucency in the left second molar area (Fig. 1). During surgery to repair the fracture, a biopsy sample for later analysis was taken from the area where the bone appeared radiolucent on the panoramic radiographs, as immediate histological examination seemed unnecessary.

Treatment by Gunning splints seemed to be the treatment of choice, to avoid the risk of aseptic necrosis of the mandible. However, this method of treatment was impossible in this case because the mandibular fracture was 2 weeks old, and the massive edema would have prevented correct placement of the denture on the mandibular ridge. Therefore, the fracture was reduced by an intraoral open reduction and was stabilized with a titanium miniplate. The fracture site was stabilized with special forceps, and monocortical titanium screws were placed on each side of the fracture. During this reduction, the mandibular incisors, which had a questionable prognosis, were not extracted, because the patient had recently been fitted with a new partial lower and upper denture. Histological examination revealed a nonmalignant osteitis lesion.

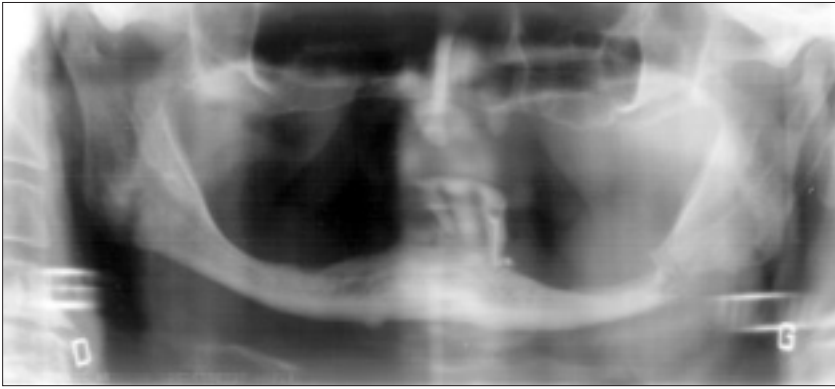


Figure 1: Panoramic radiograph demonstrates displacement of the fragments of mandibular bone.

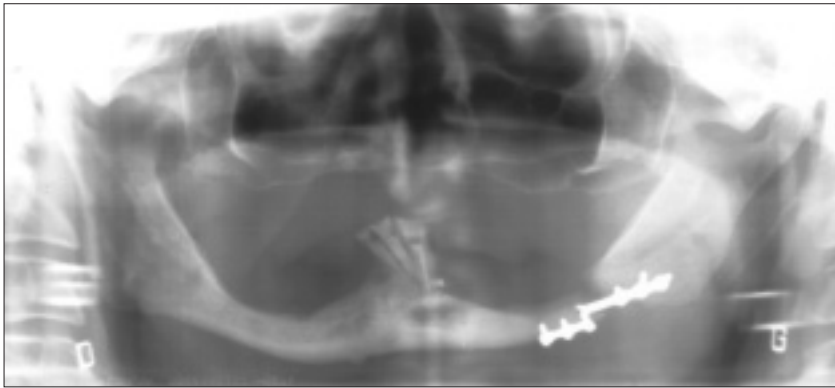


Figure 2: Panoramic radiograph of the patient 3 weeks after fracture reduction shows miniplate fracture.

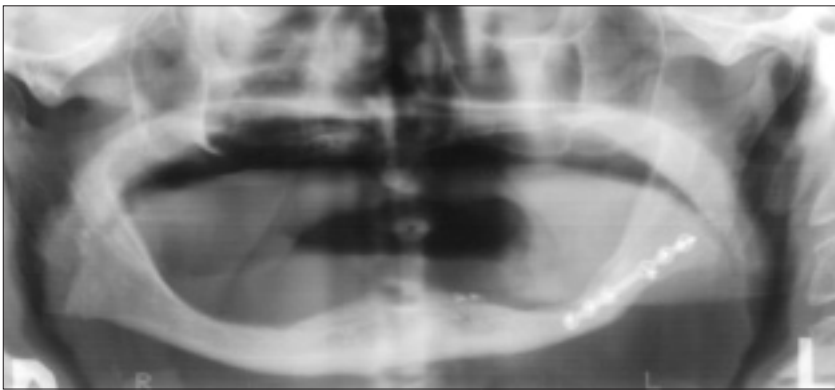


Figure 3: Panoramic radiograph of the patient 1 year later confirms good bone healing.

Postoperative panoramic radiography demonstrated satisfactory reduction of the fracture. The patient was advised to eat a liquid diet for 2 days, followed by a diet of soft food for 6 weeks.

Temporary paresthesia of the left mandibular area disappeared progressively. Twenty-one days after the surgery, the patient noticed renewed pain in the same area, and panoramic radiography revealed that the titanium miniplate had fractured (Fig. 2). It was presumed that this fracture might have occurred because of an internal defect in the miniplate, as the patient had complied strictly with his

postoperative instructions and had been unaware of any cracking sound while using the mandible. A second surgical procedure was performed to remove the “defective” miniplate, which was replaced by another plate of the same design. Postoperative panoramic radiography confirmed that the miniplate and the screws were well placed in the mandibular bone. Eight days later, follow-up panoramic radiography showed that one of the monocortical screws immediately adjacent to the fracture had become partially unscrewed. This development suggested that unusually strong forces were being exerted in this area.

During precise questioning, the patient reported that a new upper and lower denture had been fitted 2 weeks before the mandibular fracture. He had continued wearing the new upper denture day and night after the fracture reduction. After consultation, it was decided to delay further surgery, as the displacement of the screws was limited. However, the patient was asked to refrain from wearing his maxillary denture at any time.

Two months later, radiographic examination confirmed the formation of a bone callus. Three months later, the remaining lower anterior teeth were extracted. After 1 year, a complete head and neck examination showed the stability of the fracture segments, and panoramic radiography confirmed good bone healing (Fig. 3).

Discussion

Although the mandible is membranous during its embryonic stage, its physical structure resembles a bent long bone,⁵ and it is subject to biomechanical compression, bending, torsion and traction.⁶ This arch of corticocancellous bone projects downward and forward from the base of the skull and constitutes the strongest and most rigid component of the facial skeleton.

However, it is more commonly fractured than the other bones of the face, and the teeth or lack thereof may be the most important factor in determining where fractures occur. Other factors that can influence fractures are the forces exerted by the muscles of mastication, the occlusal loading pattern and the osseous anatomy. Fractures of the edentulous mandible most often occur in elderly people.

As the patient ages, bony strength is reduced. According to Thaller,⁷ there is no definitive recommendation for either closed or open reduction in cases of fracture in the edentulous mandible. In the case reported here, Gunning splints could not be used, so osteosynthesis of the fractured edentulous mandible was achieved by means of miniplates and monocortical screws. Bicortical screwing would be preferred from the perspectives of infection and pseudarthrosis,⁸ however, monocortical screwing causes fewer occlusal disorders. When troubles exist, they are minor, and only rarely is a second procedure required.^{9,10}

Complications may occur in miniplate osteosynthesis of mandibular fracture, but miniplate fractures are rare (occurring in 0.8% to 2% of cases, according to Edwards and others¹¹) and are generally due to noncompliance with instructions to eat a soft diet for 4 to 6 weeks.

The present case emphasizes 2 important aspects of treatment: (1) radiography for diagnosis and evaluation of mandibular fracture and treatment and (2) occlusal analysis and stabilization.¹²

Panoramic radiography is a standard clinical procedure for the evaluation of oral abnormalities, such as spontaneous edema in an edentulous area, especially when the patient does not report a specific precipitating event.

In the case reported here, panoramic radiography revealed a mandibular fracture with radiolucency in the fracture area. After fracture repair, postoperative panoramic radiography is recommended.¹³ In this case, the miniplate fracture suspected clinically was confirmed by panoramic radiography. A latter panoramic radiograph (after the second surgical reduction) showed that one of the monocortical screws had become unscrewed and also contributed to the diagnosis of this complication. Finally, the radiography confirmed the reduction of the fracture and formation of bone callus.

This case also underlines the importance of occlusal analysis before prosthetic rehabilitation and before treatment of a mandibular fracture. In a partially or totally edentulous patient with maxillary or mandibular dentures (or both), maximum occlusal forces are reduced; however, imperfect occlusion can still induce mandibular fracture, especially in a patient with mandibular atrophy. According to Barber and others¹⁴ and Childress and Newlands,¹² the goal of mandibular fracture repair is good occlusion, as illustrated by this case.

In this case, imperfect occlusion between the 3 remaining mandibular anterior teeth and the new maxillary denture seems to have been the main cause of fracture of the atrophic mandible, as well as the fracture of the miniplate osteosynthesis after reduction.

This patient did not report hearing any characteristic cracking sounds while eating or after surgery. He also carefully followed the recommended diet. Therefore, it is

surmised that nocturnal bruxist forces were responsible for these fractures. When these occlusal forces were removed, secondary osseointegration and satisfactory union were achieved without further surgery, despite the unscrewing of the monocortical screw. A new denture was fitted 9 months later, and total function and esthetic appearance were restored. ♦

Dr. Libersa is lecturer, department of dentistry, Abel Caumartin Centre, Regional University Hospital Centre, Lille, France.

Dr. Roze is staff member, department of dentistry, Abel Caumartin Centre, Regional University Hospital Centre, Lille, France.

Dr. Dumousseau is staff member, department of oral and maxillofacial surgery, Hospital Centre, Seclin, France.

Correspondence to: Dr. Philippe Libersa, 60, la posterie, 59830 Bourghelles, France. E-mail: sylvie.libersa3@libertysurf.fr.

The authors have no declared financial interests.

References

1. Banks P. Killey's fractures of the mandible. 4th ed. London: Butterworth-Heinemann Wright; 1991. p. 1-112.
2. Archer WH. Fractures of the facial bones and their treatment. In: Archer WH, editors. Oral and maxillofacial surgery. 5th ed. Philadelphia: WB Saunders; 1975. p. 259-60.
3. Iatrou I, Samaras C, Theologie-Lygidakis N. Miniplate osteosynthesis for fractures of the edentulous mandible: a clinical study 1989-96. *J Craniomaxillofac Surg* 1998; 26(6):400-4.
4. Joos V, Meyer U, Tkotz T, Weingart D. Use of mandibular fracture score to predict the development of complications. *J Oral Maxillofac Surg* 1999; 57(1):2-5.
5. Ma'aita J, Alwrikat A. Is the mandibular third molar a risk factor for mandibular angle fracture? *Oral Surg Oral Med Oral Pathol Oral Radiol Endod* 2000; 89(2):143-6.
6. Gola R, Cheynet F, Carreau JP, Guyot L. [The value of an osteosynthesis arch-plate combination in the application zone in the treatment of fractures of the body of the mandible.] Intérêt de l'association arc-plaque d'ostéosynthèse en zone utile dans le traitement des fractures du corpus de la mandibule. *Rev Stomatol Chir Maxillofac* 1996; 97(2):72-83.
7. Thaller SR. Fractures of the edentulous mandible: a retrospective review. *J Craniomaxillofac Surg* 1993; 4(2):91-4.
8. Jammet P, Souyris F, Atlan G, Dupoirieux L. [A comparative study of 2 series of mandibular osteosynthesis using screwed plates.] Étude comparative de deux séries d'ostéosynthèses mandibulaires par plaques vissées. *Rev Stomatol Chir Maxillofac* 1992; 93(2):76-9.
9. Peled M, Laufer D, Helman J, Gutman D. Treatment of mandibular fractures by means of compression osteosynthesis. *J Oral Maxillofac Surg* 1989; 47(6):566-9.
10. Souyris F, Lamarche JP, Mirfakhrai A. Treatment of mandibular fractures by intraoral placement of bone plates. *J Oral Surg* 1980; 38(1):33-5.
11. Edwards TJ, David DJ, Simpson DA, Abbott AH. The relationship between fracture severity and complication rate in miniplate osteosynthesis of mandibular fractures. *Br J Plast Surg* 1994; 47(5):310-1.
12. Childress SC, Newlands SD. Utilization of panoramic radiographs to evaluate short-term complications of mandibular fracture repair. *Laryngoscope* 1999; 109(8):1269-72.
13. Kawai T, Murakami S, Hiranuma H, Sakuda M. Radiographic changes during bone healing after mandible fractures. *Br J Oral Maxillofac Surg* 1997; 35(5):312-8.
14. Barber HD, Woodbury SC, Silverstein KE, Fonseca RJ. Mandibular fractures. In: Fonseca RJ, Walker RV, Betts NJ, Barber HD, editors. Oral and maxillofacial trauma. Philadelphia: WB Saunders; 1997. p. 473-526.