

Clinical Presentation and Differential Diagnosis of Nasolabial Cyst

- Donald R. Nixdorf, BSc, DDS, MS •
- Edmund Peters, DDS, MSc, FRCD(C) •
- Kevin E. Lung, BSc, DDS, MSc, FRCD(C) •

A b s t r a c t

Nasolabial cyst is a rare non-odontogenic, soft-tissue, developmental cyst occurring inferior to the nasal alar region. The patient usually presents with a slowly enlarging asymptomatic swelling, typically without radiographic abnormalities. This paper documents the presentation and management of a 46-year-old woman with a nasolabial cyst. The histopathologic features, differential diagnosis, treatment and prognosis are discussed.

MeSH Key Words: case report; diagnosis, oral; nonodontogenic cysts

© J Can Dent Assoc 2003; 69(3):146-9
This article has been peer reviewed.

Nasolabial cyst (also known as nasoalveolar or Klestadt's cyst) is a rare soft-tissue lesion that occurs in the region of the maxillary lip and alar base, lateral to the midline. It is developmental, rather than inflammatory, in origin and arises from non-odontogenic epithelium.¹ Two theories have been put forward regarding its pathogenesis. According to the first hypothesis, the cyst is derived from epithelial cells retained in the mesenchyme after fusion of the medial and lateral nasal processes and the maxillary prominence at approximately 30 days in utero.^{2,3} The second hypothesis suggests the persistence of epithelial remnants from the nasolacrimal duct extending between the lateral nasal process and the maxillary prominence.⁴ These 2 theories are not necessarily mutually exclusive; however, it has not been possible to demonstrate epithelial remnants within the embryonic mesenchyme.⁵ Thus, the latter theory appears more likely.⁶ The stimulus for development of cysts from these epithelial rests is not understood.

This paper documents the presentation and management of nasolabial cyst in a 46-year-old woman and discusses considerations related to the diagnosis.

Case Report

A 46-year-old woman presented with nonpainful lip swelling and nasal asymmetry (Figs. 1a and 1b). These symptoms had been evident for approximately 10 years,

over which time the swelling had been slowly enlarging. On palpation the lesion was approximately 2 × 2 cm, fluctuant, mobile and nontender. Intraoral examination revealed a pale mucosal swelling that distended the vestibule contiguous to the right maxillary incisors (Fig. 2). The associated teeth tested vital with ethyl chloride and were not mobile. Occlusal radiography showed a demarcated radiolucent area in the periapical region of the right maxillary incisors, with minimal root resorption of the central incisor (Fig. 3). No anomalies were noted on panoramic radiography or lateral cephalography.

The lesion was removed under general anesthesia. A sulcular incision was made, and a buccal full-thickness envelope flap raised to expose the lesion (Fig. 4). The cyst released easily from the bone, to reveal a dish-shaped crypt, and was peeled intact from the overlying mucosa. The previously noted resorption of the maxillary central incisor was confirmed following enucleation of the lesion. After curettage of the contiguous hard and soft tissues, the wound was closed by primary intention, and the final specimen was submitted for histopathologic diagnosis.

Microscopic evaluation of the excised specimen (Fig. 5) revealed a cystic structure lined alternately with squamous or cuboidal epithelium and extensive zones of mucus-containing goblet cells (Fig. 6). The supporting fibrous wall was unremarkable.



Figure 1a: Preoperative portrait photograph of a patient with a nasolabial cyst under the right alar base of the nose and the maxillary lip. Asymmetry cannot be easily discerned.

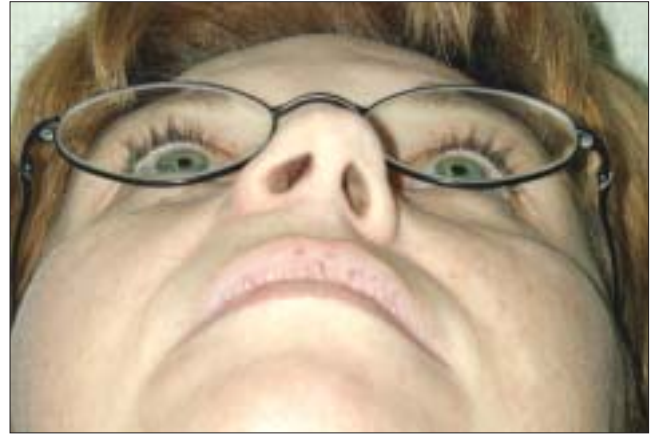

Figure 1b: Preoperative inferior photograph of the patient. Asymmetry caused by the submucosal cystic mass is clearly evident under the right alar base of the nose and the maxillary lip.

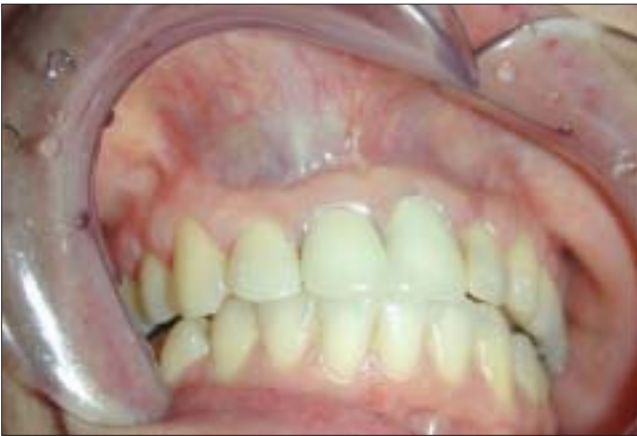

Figure 2: Intraoral view of the nasolabial cyst. The vestibule is distended by the submucosal cystic mass, which has a blue hue.

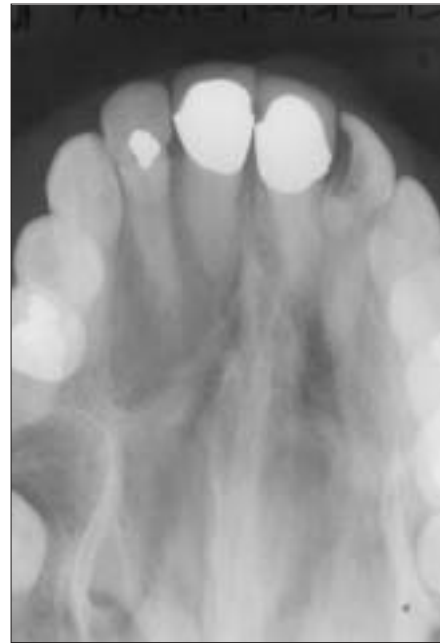

Figure 3: Occlusal radiograph shows a well-defined radiolucent area in the periapical region of the right maxillary incisors. There is slight root resorption of the central incisor.

Postoperative follow-up at 6 months showed good healing without evidence of recurrence. All adjacent teeth remained vital with no further evidence of root resorption.

Discussion

The differential diagnosis for a long-standing nonpainful vestibular soft-tissue swelling within the anterior maxillary-alar region is not extensive, once conditions other than benign cysts are excluded. However, only nasolabial cyst presents exclusively in this area.

Other soft-tissue lesions that can occur in this region include periapical inflammatory lesions (granuloma, cyst or abscess) that have perforated the bone. Vitality testing of

the adjacent teeth can help to rule out this possibility. Very rarely, aggressive developmental odontogenic lesions, such as keratocyst, extend through the bone cortex to cause soft-tissue swelling. The long-standing nature of this lesion and the limited bone involvement (suggested radiographically) made this diagnosis improbable. Developmental gingival cyst of the adult has a predilection for the bicuspid or canine region and might have been considered in this case. However, this lesion is usually localized in the gingival or contiguous alveolar mucosa and would not cause the distension of the vestibular mucosa that characterizes nasolabial cyst. Another possible cyst of non-odontogenic origin is the epidermoid or epidermal inclusion cyst. A

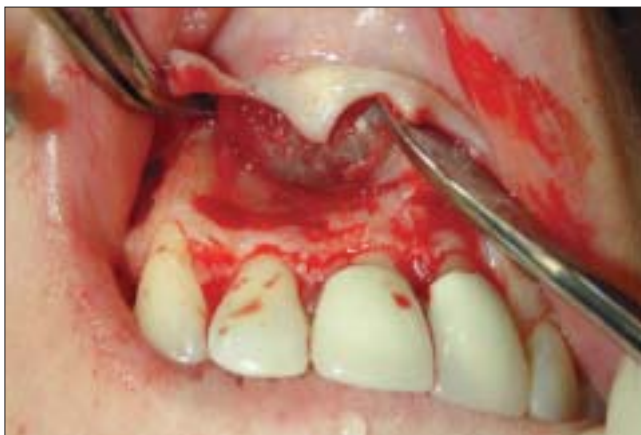

Figure 4: Surgical exposure of the nasolabial cyst reveals the dish-shaped crypt and attachment to the overlying tissue.

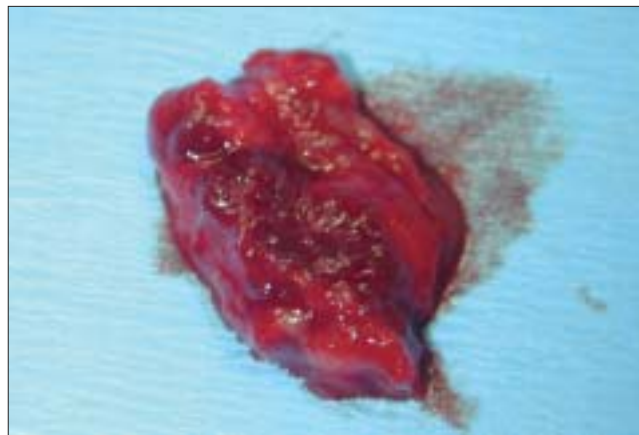


Figure 5: Surgical specimen. The cystic mass measured 15 × 10 × 4 mm.

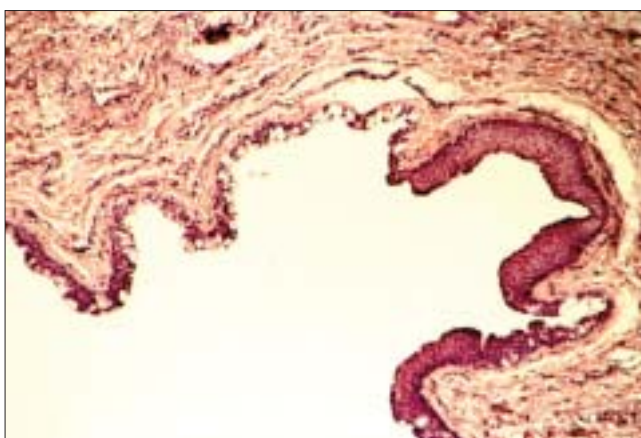


Figure 6: Histopathologic section shows the cyst lining characterized by extensive zones of goblet cells and stratified squamous epithelium. (Hematoxylin and eosin stain. Original magnification ×63).

distinguishing feature of this very rare cyst may be its yellow hue, as opposed to the normal pink or bluish coloration of a nasolabial cyst. Mucous extravasation cyst could also be considered. However, in such cases there is often a history of deflation and inflation as mucus within the lesion is periodically expressed and regenerated. As noted earlier, numerous non-odontogenic benign or malignant neoplasms may present in this area. Of particular significance are salivary gland neoplasms arising from minor salivary glands.

Nasolabial cyst occurs in 3 times as many women as men, and most patients present in the fourth decade of life.⁷ More than 10% of the cases reviewed by Allard² were bilateral. The soft-tissue swelling may obliterate the mucolabial fold, elevate the ala or the floor of the nose (or both) and fill in the labial vestibule intraorally, with or without nasal obstruction. A nasolabial cyst is usually not painful, unless it is secondarily infected. The lesion may spontaneously rupture and drain orally, nasally or, occasionally, via a cutaneous fistula.^{1,4,8} As in this case, bony erosions

have been reported in association with large lesions that have been present for extended periods.⁹

The diagnosis requires correlation of the clinical and histologic information. Histologically, nasolabial cysts may present with squamous, cuboidal or pseudostratified columnar ciliated epithelial lining, often with goblet cells.¹⁰ The supporting connective tissue is fibrous, often comprising components of the adjacent skeletal muscle.

The treatment of choice is conservative surgical excision,^{11,12} with an intraoral approach. The prognosis is excellent and recurrence is not expected.⁶

Conclusions

This report has presented the clinical and histologic features and treatment of a classic nasolabial cyst, as well as a review of diagnostic and management considerations. This lesion should always be considered in the diagnosis of soft-tissue vestibular swelling in the alar region. After conservative surgical excision, recurrence is rare. ♦

Dr. Nixdorf is a clinical assistant professor in the department of diagnostic and surgical sciences, School of Dentistry, University of Minnesota, Minneapolis, Minnesota.

Dr. Peters is professor in oral pathology and oral medicine in the department of dentistry, faculty of medicine and dentistry, University of Alberta, Edmonton, Alberta.

Dr. Lung is an oral and maxillofacial surgeon in private practice and an associate professor, faculty of medicine and dentistry, University of Alberta, Edmonton, Alberta.

Correspondence to: Dr. Donald Nixdorf, 6-320 Moos Tower, University of Minnesota, 515 Delaware Street S.E., Minneapolis, MN 55455. E-mail: nixdorf@umn.edu.

The authors have no declared financial interests.

References

1. Shafer WG, Hine MK, Levy BM. A textbook of oral pathology. 4th ed. Philadelphia: Saunders; 1983. p. 1–85.
2. Allard RH. Nasolabial cyst. Review of the literature and report of 7 cases. *Int J Oral Surg* 1982; 11(6):351–9.

3. Sperber GH. Craniofacial embryology. 4th ed. London: Wright; 1989. p. 31–57.
4. Neville BW, Damm DD, Allen CM, Bouquot JE. Oral and maxillofacial pathology. 1st ed. Philadelphia: Saunders; 1995. p. 1–43.
5. Neville BW, Damm DD, White DK. Color atlas of clinical oral pathology. 2nd ed. Philadelphia: Lippincott Williams & Wilkins 1999. p. 1–39.
6. Regezi JA, Sciubba J. Oral pathology: clinical – pathologic correlations. 2nd ed. Philadelphia: Saunders; 1993. p. 322–61.
7. Smith RA, Katibath RN, Merrell P. Nasolabial cyst: report of case. *J Can Dent Assoc* 1982; 48(11):727–9.
8. Precious DS. Chronic nasolabial cyst. *J Can Dent Assoc* 1987; 53(4):307–8.
9. Cohen MA, Hertzanu Y. Huge growth potential of the nasolabial cyst. *Oral Surg Oral Med Oral Pathol* 1985; 59(5):441–5.
10. Vasconcelos RF, Souza PE, Mesquita RA. Retrospective analysis of 15 cases of nasolabial cyst. *Quintessence Int* 1999; 30(9):629–32.
11. Adams A, Lovelock DJ. Nasolabial cyst. *Oral Surg Oral Med Oral Pathol* 1985; 60(1):118–9.
12. Wesley RK, Scannell T, Nathan LE. Nasolabial cyst: presentation of a case with review of the literature. *J Oral Maxillofac Surg* 1984; 42(3):188–92.