

# A Modified Impression Technique for Accurate Registration of Peri-implant Soft Tissues

• Nikolai Attard, BChD, MSc •  
• Izchak Barzilay, DDS, Cert Prostho, MS •

## A b s t r a c t

*Replacement of single missing teeth with an implant-supported restoration is recognized as a highly successful treatment. An impression technique for peri-implant soft-tissue replication in an anterior zone is described. The technique involves use of an interim restoration as an abutment for the final impression. This allows accurate duplication of the soft tissues and fabrication of a final restoration with the correct emergence profile.*

**MeSH Key Words:** dental implants, single tooth; dental impression techniques; dental prosthesis, implant-supported

© J Can Dent Assoc 2003; 69(2):80-3  
This article has been peer reviewed.

Osseointegration is a well-established treatment modality for the restoration of missing teeth. The impressive results reported for the treatment of complete edentulism<sup>1-3</sup> encouraged researchers to establish clinical trials for partially edentulous patients. These studies have underscored the merits of either implant-supported restorations<sup>4,5</sup> or combined implant- and tooth-supported restorations<sup>6</sup> in partially edentulous patients. Success has also been reported for single-tooth restorations.<sup>7-10</sup> The restoration of missing anterior teeth presents an esthetic challenge in terms of maintaining the smile line, preserving the soft tissues and obtaining an appropriate emergence profile from the gingival tissues.

This paper describes an impression technique that preserves the soft-tissue profile obtained after adequate gingival healing following surgery.

### Case Report

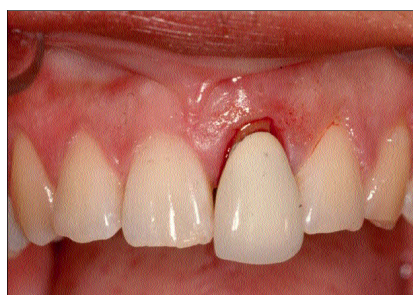A healthy 34-year-old patient presented with pain in tooth 21, which had previously been restored with a porcelain-fused-to-metal crown (Fig. 1). Clinical examination revealed a high smile line and mobility of tooth 21. Radiographic evaluation confirmed a root fracture (Fig. 2).

The proposed treatment plan included extraction of the tooth and replacement with an implant-supported restoration. The fractured tooth was extracted atraumatically, and an interim acrylic partial denture was inserted immediately. After 6 months, clinical and radiographic evaluation of the

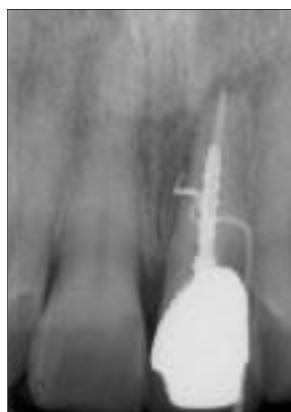site indicated osseous healing, and the region was deemed ready for placement of an implant (Fig. 3). A surgical guide was fabricated, and a single 15 × 3.75 mm Brånemark implant (MKIII, Nobel Biocare, Göteborg, Sweden) was inserted at the site. The surgery and healing phases were uneventful.

After a further 6-month period of undisturbed healing, the implant was exposed, and a temporary acrylic abutment (DCA 1049-0, Nobel Biocare) was secured to it. An acrylic denture tooth was bonded to the temporary abutment with Jet autocure acrylic (Lang Dental Mfg. Co., Inc., Wheeling, Ill.). After initial curing of the acrylic, the tooth was moulded by incremental addition of acrylic to provide an appropriate emergence profile from the soft tissues. The patient's occlusion was adjusted, and the interim restoration was removed. After chairside adjustment of the submerged portion of the restoration, the crown was polished and inserted. The abutment screw was secured and the access cavity obturated with a cotton pellet and interim filling material (Cavit, ESPE, Seefeld, Germany) (Fig. 4).

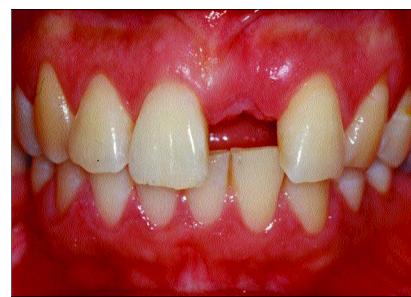The patient was evaluated 1 week after surgery, when the sutures were removed. The patient was encouraged to massage the gingival tissues gently 4 times a day for 2 minutes at a time. After 8 more weeks, to allow healing of the soft tissues, the patient returned for fabrication of the final restoration. Polyether impression material (Impregum, Universal Viscosity Polyether, ESPE) was used to make the final impression over top of the interim



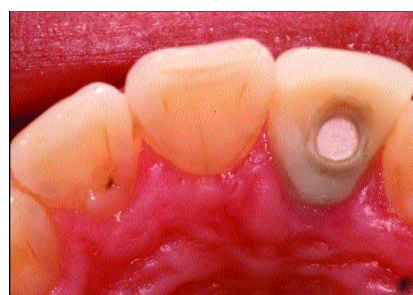
**Figure 1:** The restoration on tooth 21 is displaced, which suggests a root fracture.



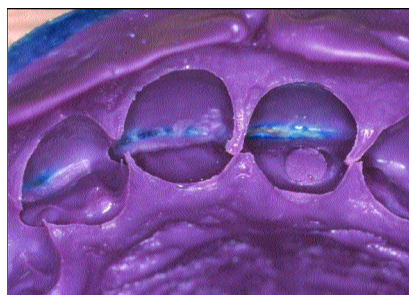
**Figure 2:** Radiographic investigation confirmed a root fracture.



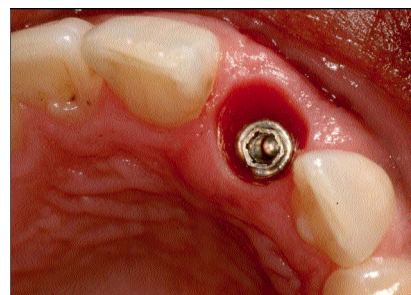
**Figure 3:** After a 6-month healing period, the site was ready for surgical placement of an implant. The implant was then allowed to heal for a further 6 months with no disturbance.



**Figure 4:** An interim restoration was fabricated with a denture tooth connected to a temporary cylinder.



**Figure 5:** The impression was checked for accuracy. The access hole was captured in the impression, which helped in positive seating of the interim restoration.



**Figure 6:** The soft tissues around the implant head, which have been moulded by the interim restoration, appear healthy.

restoration (Fig. 5). The impression was removed and checked for accuracy. The interim restoration was then removed and a healing abutment positioned (Figs. 6 and 7). Blue-Mousse fast-setting vinyl polysiloxane impression material (Parkell Biomaterials Division, Farmingdale, NY) was injected gently around the healing abutment to maintain the soft-tissue profile (Fig. 8).

An implant analogue was secured to the interim restoration by hand pressure, and the interim restoration was repositioned in the polyether impression (Fig. 9). A soft-tissue model was fabricated from polyvinyl soft-tissue analogue (Gi-Mask Automic, Coltene, Switzerland) and die stone (Extreme Green, Canadian Medical Dental Gypsum, Burlington, Ont.). This allowed correct replication of the soft tissues. After hardening of the die stone, an index was made of the contour of the interim restoration (Fig. 10). The restoration was then unscrewed from the cast, disinfected and reinserted into the patient's mouth.

The final restoration was fabricated by firing porcelain directly to an all-ceramic abutment (CerAdapt, Nobel Biocare). The restoration was inserted, and seating was confirmed with periapical radiography (Fig. 11). The occlusion and contact points were adjusted and seated, the

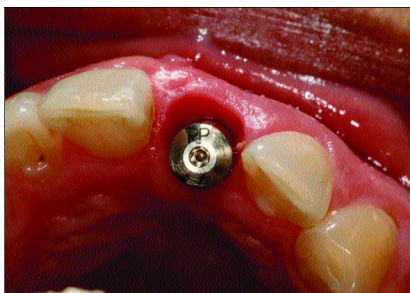
abutment screw was torqued to 32 Ncm, and the access hole was sealed with cotton and composite resin (Fig. 12).

## Discussion

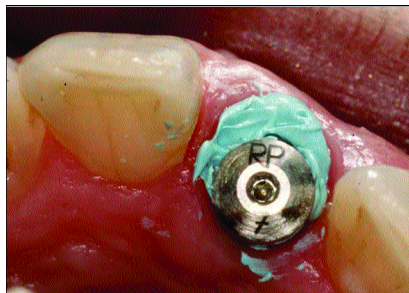
This article has presented an alternative impression technique for implant restorations. Conventional approaches for making impressions of implants use impression copings at either the fixture or the abutment level. However, these techniques do not replicate the soft tissues that have been custom moulded before the final impression. It is therefore difficult for the dental technologist to create an ideal emergence profile. Moreover, the patient may find the try-in and insertion appointments painful because the soft tissues are abruptly pushed away when the final restoration is seated.

In the technique discussed above, the impression coping was replaced by the interim crown itself. This technique is superior because it accurately registers the tissue profile that has been created with the interim restoration. Conventionally available components do not do this, and few methods are available that can easily reproduce the tissue contour.


A further advantage of this approach is that the soft tissues are replicated when the impression is poured, which gives the dental technologist the exact shape of the



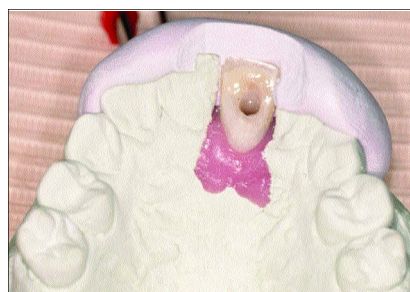
**Figure 7:** The healing abutment is smaller than the peri-implant sulcus. A space can be seen on the buccal aspect of the abutment.



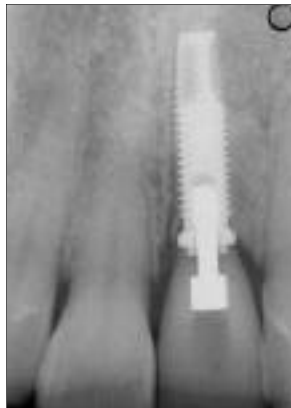**Figure 8:** To prevent the tissues from collapsing while the impression was being poured, fast-setting vinyl polysiloxane was injected gently around the healing abutment.



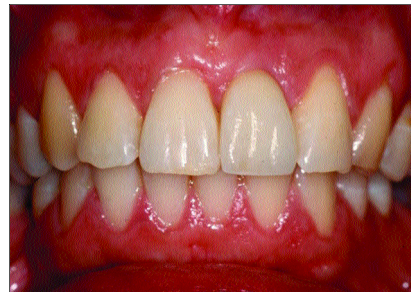
**Figure 9:** The crown was seated in the impression and the impression was poured.



**Figure 10:** An index of the interim crown was created with condensation vinyl polysiloxane putty. This helped in selection of the proper definitive abutment.



**Figure 11:** Radiograph of the final ceramic restoration in situ was used to verify proper seating.



**Figure 12:** After placement of the final restoration, the emergence of the crown from the soft tissues was excellent.

peri-implant sulcus. When the prosthesis is inserted, the shape of the prosthesis is identical with that of the interim restoration. This minimizes any soft-tissue distension when the restoration is placed. Optimal esthetics can therefore be maintained.

This method is very accurate in its duplication of the soft-tissue profiles in the mouth. However, it does rely on the clinician's ability to pour the impression immediately or to have it poured in a relatively short period of time. Placement of a fast-setting polyvinyl material helps to maintain the tissue profile while the impression is being poured. The patient may be without the prosthesis for approximately 1 hour while the pouring is accomplished.

The method described in this paper relies on the accuracy of the temporary cylinder in capturing the hex position of the implant. An accurate impression coping is one that connects to the implant hex without any rotational misfit. If misfit is present, the resulting prosthesis may be rotated slightly. This necessitates adjustment of the contact points and possibly manipulation of the porcelain to generate ideal contours on the crown. In the case reported here, only minor adjustment of the interproximal region was needed.

Ideally, a temporary cylinder with "zero rotation" would be needed to avoid such difficulties. Furthermore, the temporary restoration may be unstable in the impression. To minimize this problem, the proper impression material must be used. Moreover, acrylic dimples should be created on the interim restoration before the impression phase. The impression will then register the dimples without tearing, and the interim restoration can be inserted into it without loosening during pouring. The dimples can be used to confirm proper seating and provide the stability necessary during vibration pouring of the master cast. In the case presented, the access hole in the interim restoration was cleared to provide positive seating when it was placed in the impression (Fig. 5).

**Conclusions**

This paper has presented an impression technique that accurately duplicates the peri-implant tissue profile. The final prosthesis is shaped exactly like the interim prosthesis for ideal contour and soft-tissue position. Optimal esthetic results can be achieved with this method. ♦

---

**Acknowledgments:** The authors thank Dr. Peter Birek for surgical placement of the implant and express gratitude to Janet DeWinter and the staff of the Implant Prosthodontic Unit, faculty of dentistry University of Toronto.

**Dr. Attard** is a graduate resident, department of prosthodontics, faculty of dentistry, University of Toronto, Toronto, Ontario.

**Dr. Barzilay** is assistant professor, department of prosthodontics, University of Toronto, Toronto, Ontario, and head, division of prosthodontics, Mount Sinai Hospital, Toronto, Ontario. He is also in private practice in Toronto, Ontario.

**Correspondence to:** Dr. Nikolai Attard, Department of Prosthodontics, Faculty of Dentistry, University of Toronto, 124 Edward Street, Toronto, ON M5G 1G6. E-mail: nik.attard@utoronto.ca.

The authors have no declared financial interests in any company manufacturing the types of products mentioned in this article.

---

## References

1. Adell R, Lekholm U, Rockler B, Brånemark PI. A 15-year study of osseointegrated implants in the treatment of the edentulous jaws. *Int J Oral Surg* 1981; 10(6):387–416.
2. Zarb GA, Schmitt A. The edentulous predicament I: a prospective study of the effectiveness of implant supported fixed prostheses. *J Am Dent Assoc* 1996; 127(1):59–65.
3. Zarb G, Schmitt A. The edentulous predicament II: The longitudinal effectiveness of implant supported overdentures. *J Am Dent Assoc* 1996; 127(1):66–72.
4. Wyatt CC, Zarb GA. Treatment outcomes with implant supported fixed partial prostheses. *Int J Oral Maxillofac Implants* 1998; 13(2):204–11.
5. Lekholm U, Gunne J, Henry P, Higuchi K, Linden U, Bergstrom C, and others. Survival of the Brånemark implant in partially edentulous jaws: a 10-year prospective multicenter study. *Int J Oral Maxillofac Implants* 1999; 14(5):639–45.
6. Gunne J, Astrand P, Lindh T, Borg K, Olsson M. Tooth-implant and implant supported fixed partial dentures: a 10-year report. *Int J Prosthodont* 1999; 12(3):216–21.
7. Avivi-Arber L, Zarb GA. Clinical effectiveness of implant supported single-tooth replacement: the Toronto Study. *Int J Oral Maxillofac Implants* 1996; 11(3):311–21.
8. Henry PJ, Laney WR, Jemt T, Harris D, Krogh PHJ, Polizzi G, and others. Osseointegrated implants for single-tooth replacement: a prospective 5-year multi-center study. *Int J Oral Maxillofac Implants* 1996; 11(4):450–5.
9. Andersson B, Odman P, Lindvall AM, Brånemark PI. Five-year prospective study of prosthodontic and surgical single-tooth implant treatment in general practices and at a specialist clinic. *Int J Prosthodont* 1998; 11(4):351–5.
10. Scholander S. A retrospective evaluation of 259 single-tooth replacements by the use of Brånemark implants. *Int J Prosthodont* 1999; 12(6):483–91.