

# Point of Care

The Point of Care section of JCDA answers everyday clinical questions by providing practical information that aims to be useful at the point of patient care. The responses reflect the opinions of the contributors and do not purport to set forth standards of care or clinical practice guidelines. Readers are encouraged to do more reading on the topics covered. This month's responses were provided by speakers at the 2004 Pacific Dental Conference, presented in partnership with the Canadian Dental Association. The conference will take place in Vancouver, B.C., from March 4 to 6. If you would like to submit or answer a question, contact editor-in-chief Dr. John O'Keefe at [jokeefe@cda-adc.ca](mailto:jokeefe@cda-adc.ca).

---

## Question 1 How can I foster realistic patient expectations regarding complete dentures and minimize dissatisfaction at the delivery appointment?

---

### Background to the Issue

Many general dentists today express reluctance to provide complete denture services.<sup>1</sup> This reluctance may be due to:

- the increasing complexity of cases, which frequently involve frail, elderly patients
- limited denture experience in dental school and a feeling that mastery is not attainable with general dental skill sets
- fear that patients will not be satisfied.

Most dentures placed today are replacement dentures, which raises additional concerns about patients resisting change and not wanting to give up that which is familiar to them. The denture technique described below addresses the issues of tissue restoration and vertical dimension, while encouraging dentist–patient communication *before* prosthetic treatment begins.

### Managing Soft-Tissue Injuries

Persistent tissue irritation can prompt patients to seek replacement dentures; however, chronic denture injuries often go unnoticed until a dentist points them out. Pointing out such injuries is important because it highlights the benefits of treatment, while serving as a baseline against which change can be referenced. It is important for patients to understand that discomfort and injury don't necessarily go hand-in-hand and that chronic injury compromises future prosthetic treatment. Placement of a tissue conditioner, without making any other change to the denture base, is a reversible intervention that restores tissue health and buys time to consider treatment options.

### Managing Patient Expectations: Appearance and Function

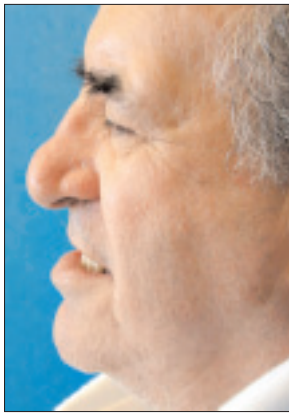Occlusal vertical dimension (OVD) of dentures is lost gradually and patients are often unaware of associated

changes in facial form and occlusion (Fig. 1). Incremental layering of tissue conditioner can re-establish posterior occlusion and increase OVD, while allowing restored facial form to be previewed. Placing incremental layers of tissue conditioner offsets flange overextensions and often eliminates the need for border adjustments. After 2 or 3 tissue conditioning appointments, dentists can weigh patient expectations against possible outcomes and begin prosthetic treatment. This time can be used to plan occlusion and tooth position.

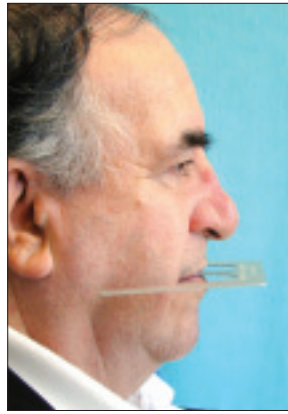### Predicting Success and Beginning Treatment

Tissue conditioners are functional impression materials, flowing to shape and defining coverage. It is important to evaluate OVD and freeway space as well as occlusal plane orientation with each placement of tissue conditioner. The occlusal plane should be verified using the interpupillary line and Camper's plane after placement of each layer of tissue conditioner (Fig. 2). Closest speaking space is used to confirm preservation of adequate freeway space. A low-viscosity, nonaqueous elastomeric impression wash placed on top of the tissue conditioner is then used to capture soft tissue detail and to record maxillo-mandibular relations when impressions are taken. An open-mouth impressing technique is used to capture mandibular tissues (Figs. 3 and 4) as the patient's tongue and facial muscles are activated.

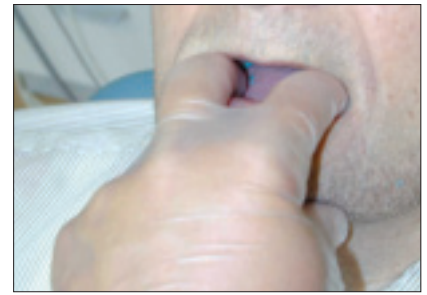Border molding is accomplished automatically in both arches as the tissue conditioner functionally defines flange extension and width. Maxillary denture impression and bite registration are simultaneously completed using a closed-mouth technique. Tissue compression/distortion is always a concern during denture impressing. With this technique, the tissue conditioner has already dynamically captured soft-tissue form and a very thin layer of low-viscosity polyvinylsiloxane will refine the surface detail of the conditioner. A few brushstrokes of tray adhesive are used to secure the impression to the tissue conditioner.



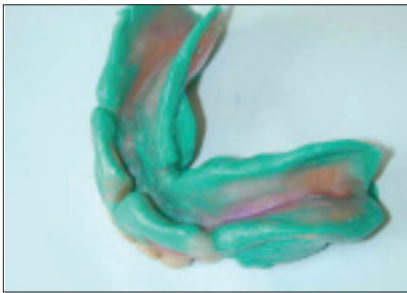
**Figure 1:** Profile of patient with lost occlusal vertical dimension.



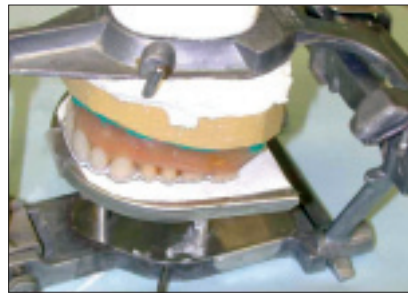**Figure 2:** Evaluation of occlusal plane using the Occlusal Plane Analyzer (Dentsply Trubyte).




**Figure 3:** Mandibular impressing, open-mouth technique.



**Figure 4:** Completed mandibular impression.



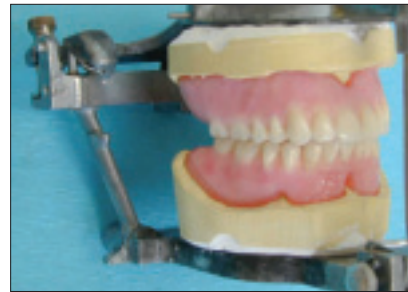**Figure 5:** Maxillary tooth position indexed to occlusal mounting table after closed-mouth maxillary impressing technique.



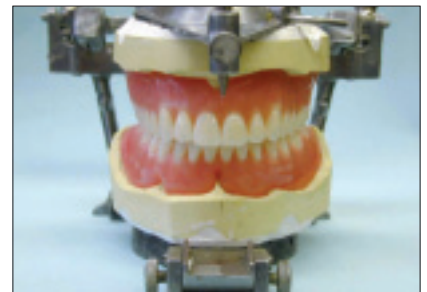**Figure 6:** Tooth position relationship to processed baseplate.



**Figure 7:** Final denture bases made of Eclipse Prosthetic Resin System (Dentsply Trubyte).



**Figure 8:** Replacement dentures ready for trial insertion.



**Figure 9:** Finished complete dentures.



**Figure 10:** Satisfied patient with replacement dentures.

### Model Articulation and Tooth Positioning

A mounting plate replaces the facebow and allows casts to be mounted with existing tooth positions referenced to the maxillary model. Tracing of existing tooth position (Fig. 5) facilitates tooth arrangement and allays patient fears regarding unwanted changes in appearance.

### Trial Insertion Using Final Denture Bases

The trial denture should be inserted on finished denture bases (Figs. 6 to 8) to allow problems with fit to be identified *before* final processing and improve occlusal record accuracy.<sup>2</sup> New denture resin technology allows simple construction of dimensionally stable final bases. The trial denture is ready for insertion at the second appointment in the denture construction sequence. Delivery of the finished prosthesis is completed at the third appointment (Figs. 9 and 10).

### No Surprises

The steps described above are familiar to most dentists and are independent of material selection. It is the sequencing of these steps that offers communication opportunities and insight. Use of tissue conditioners to restore OVD and define coverage supports an impression technique that simultaneously captures soft tissue detail and jaw relations, saving chair time and allowing existing tooth positions to

be referenced to the articulated models. Use of final denture bases at the try-in appointment ensures the same fit at delivery. My experience suggests the above clinical sequence will reduce postinsertion adjustments (19 patients treated for 27 complete denture arches with fewer than 25% requiring postinsertion adjustments to the denture base), will virtually eliminate remakes and improve patient satisfaction. This treatment sequence offers clinicians an opportunity to gracefully dismiss patients with unrealistic expectations and to help other patients understand when an implant-supported prosthesis should be considered. ♦

---

*Dr. Ewoldsen is adjunct associate professor, adult restorative dentistry, UNMC College of Dentistry, Lincoln, Nebraska. He is also director, clinical research and education, Dentsply Trubyte, York, Pennsylvania. E-mail: NEwoldsen@Dentsply.com.*

*Dr. Ewoldsen's seminar "From Functional Impressions to Finished Dentures: Three Appointments — Zero Surprises" will be presented on Thursday, March 4.*

---

### References

1. Melton AB. Current trends in removable prosthodontics. *J Am Dent Assoc* 2000; 131 Suppl:52S–56S.
2. Thomas-Weintraub A, Weintraub GS. Processed permanent record bases in complete denture therapy: rationale and technique. *Compend Contin Educ Dent* 1985; 6(9):660–5, 668.

---

## Question 2

I understand current research shows that dental decay is an infectious disease. What should I do differently now to treat my patients?

---

### Background to the Issue

The newest research (some of which is more than 15 years old) strongly supports the theory that dental decay is an infection caused by *Streptococcus mutans*. Children usually acquire the infection from their mother, but they can sometimes acquire it from their father or, more infrequently, from other children at a daycare centre.<sup>1</sup> The higher the maternal *S. mutans* levels in saliva, the greater the risk of transmission. Acquisition of the infection occurs around 1 to 2 years of age. It can be acquired in the pre-dentate period, but the organisms prefer hard surfaces for persistent colonization, and so are more commonly found when teeth are in the mouth.

The modern management of caries continues to be elimination of decay, restoration of affected teeth, and hardening of teeth with fluoride, thereby making them less susceptible to dissolution at any given acid pH. The newest development in topical fluoride is fluoride varnish.<sup>2</sup> Now dentists must go one step further to eliminate *S. mutans* organisms, either by killing them with a disinfectant such

as chlorhexidine or iodine, or by altering the oral environment, such that it is not conducive to the growth of the cariogenic bacteria. This is done by introducing xylitol into the oral environment. Xylitol is a natural sugar that does not promote decay and that facilitates the evolution of noncariogenic organisms.<sup>3,4</sup>

Essentially, to incorporate the most recent findings into dental practice, the dentist and patient have to do a little bit more than in the past to cure dental decay and to ensure that it is not passed on to children.<sup>5,6</sup> This is the new concept implied by the terms “managing dental decay as an infectious disease” and “medical management of caries.”

### Medical Management of Caries

The basics of caries management still apply to all patients:

#### Reduce/eliminate snacking

- Remind the patient not to constantly sip or eat fermentable carbohydrates like coffee with sugar, raisins and pretzels. All carbohydrates are food for decay-

causing bacteria. The stickier the snack (candy, raisins, dried apricots) and the more frequently it is ingested, the likelier there will be decay.

#### Use of toothbrush, floss and mouthrinse

- Advise the patient to floss and to brush with an over-the-counter fluoride toothpaste and to rinse daily with an over-the-counter nonalcohol mouthrinse containing 0.05% NaF.

Dentists treating high-risk patients should be aware of the newest protocols for caries management:

#### Fluoride treatments

- Prescribe a 5,000 parts per million fluoride toothpaste (e.g., Prevident 5000 Plus, ControlRx).

Rx Prevident

Disp 4.2 oz (1 tube)

Sig Use to brush teeth 2 times per day, especially before going to sleep at night

- In the dental office, apply fluoride varnish (e.g., Cavity Shield, Duraflo) to the teeth twice a year.

#### Antimicrobial products

- Have the patient rinse and brush his or her teeth with iodine for 1 minute once every 2 months (ensure the patient has no allergies to iodine or shellfish).

Rx Betadine Solution

Disp 8 oz bottle

Sig Once every 2 months, rinse and brush with 1 teaspoon of Betadine Solution in mouth and around teeth, then spit out.

or

- Have the patient rinse and brush his or her teeth with chlorhexidine once a day for 2 weeks every 3 months.

Rx Chlorhexidine 0.12%

Disp 16 oz.

Sig Every 3 months, rinse and brush with 1 tablespoon of the chlorhexidine solution in mouth for 1 minute once a day for 2 weeks.

#### Xylitol

- Advise the patient to chew 2 pieces of xylitol gum for 5 minutes 3 to 5 times a day (if the patient chews gum and has no temporomandibular joint problems) or to suck on xylitol candy 3 to 5 times a day. Xylitol must be the first ingredient in the gum or candy to ensure a high enough concentration to be effective.

Selected xylitol sources:

www.epicdental.com, 1-866 920-4200

www.xylitolworks.com, 1-800 601-0688

www.omniipharma.com, 1-800 445-3386

www.xylitolnow.com, 1-619 445-2689

www.bioscienceproducts.com, 1-800 595-1089 ♦

---

*Dr. Peter L. Jacobsen is a professor in the department of pathology and medicine, University of the Pacific, School of Dentistry, San Francisco, California. E-mail: pjacobse@pacific.edu. He has no declared financial interest in the companies manufacturing the types of products mentioned in this response.*

*Dr. Jacobsen will be presenting 2 seminars at the joint PDC/CDA convention on Friday, March 5, "Modern Dental Pharmacology" and "Over-the-Counter Dental Products."*

---

#### References

1. Berkowitz RJ. Acquisition and transmission of mutans streptococci. *J Calif Dent Assoc* 2003; 31(2):135–8.
2. Donly K. Fluoride varnishes. *J Calif Dent Assoc* 2003; 31(3):217–9.
3. Lynch H, Milgrom P. Xylitol and dental caries: an overview for clinicians. *J Calif Dent Assoc* 2003; 31(3):205–9.
4. Anderson M. A review of the efficacy of chlorhexidine on dental caries and the caries infection. *J Calif Dent Assoc* 2003; 31(3):211–4.
5. Stuart R, Hale K. The paradigm shift in the etiology, prevention, and management of dental caries: its effect on the practice of clinical dentistry. *J Calif Dent Assoc* 2003; 31(3):247–51.
6. Featherstone JD, Adair SM, Anderson MH, Berkowitz RJ, Bird WF, Crall JJ, and others. Caries management by risk assessment: consensus statement, April 2002. *J Calif Dent Assoc* 2003; 31(3):257–69.



**Question 3** What can be done for dental health care professionals who develop symptoms or reactions that may be due to latex hypersensitivity?

This question is being asked more frequently as people become increasingly concerned about dermatitis problems and issues surrounding latex allergies. The first step is to ascertain whether the problem represents a true hypersensitive reaction to latex. It is important to understand that the most common form of hand dermatitis is actually a nonspecific irritation and not an immunologic response. While routine handwashing is a fundamental application of good aseptic technique, frequent washing of hands by health professionals can lead to dermatitis or other exudative lesions, which may manifest as dry, chapped or abraded epithelium. Incomplete drying of hands before donning gloves or rinsing hands in hot water are the most common causes of irritation dermatitis (Fig. 1).

Diagnosis of true immunologic reactions either to components of natural rubber latex (type I, immediate) or to chemicals used in the manufacture of latex products (type IV, delayed) continues to be a serious challenge for health care workers and their patients. In addition to latex gloves used in the health care environment, a number of other devices can contain latex, including blood pressure cuffs, dental dams, elastic bands on masks, adhesive bandages, nitrous oxide nose cones and prophylaxis cups.

Type I hypersensitivity typically develops within minutes after a sensitized person comes into direct contact with allergens or is exposed via aerosolization. Natural rubber latex proteins adhering to glove powder can remain suspended in the air for prolonged periods after gloves are donned or new boxes of gloves are opened. Wheal and flare reactions (i.e., urticaria, hives) may develop along with pruritis and localized edema (Fig. 2). Coughing, wheezing, shortness of breath and respiratory distress may occur and can be life-threatening. In contrast, type IV or delayed

hypersensitivity reactions typically occur as contact dermatitis. Onset of symptoms may be delayed for several hours, with a 24- to 48-hour interval before the allergic reaction peaks (Fig. 3). Healing can take 4 days, with scabbing and sloughing of affected epithelial tissues.

Many of these reactions look alike in the early stages of development. Definitive diagnosis must be made by a qualified physician using specific clinical and laboratory tests, such as the in vitro radioallergosorbent (RAST) test or the in vivo skin-prick test. Should the condition be caused by a type I or type IV hypersensitivity, specific latex avoidance precautions must be followed by the health care worker. These include the use of latex-free products and possible accommodations in the work environment. ♦

*Dr. John A. Molinari is professor and chair of the department of biomedical sciences, University of Detroit, Mercy School of Dentistry, Detroit, Michigan. E-mail: molinaja@udmercy.edu.*

*Dr. Molinari's seminar "Emerging Disease and Challenging Issues in Infection Control" will be presented on Thursday, March 4.*

**Further Reading**

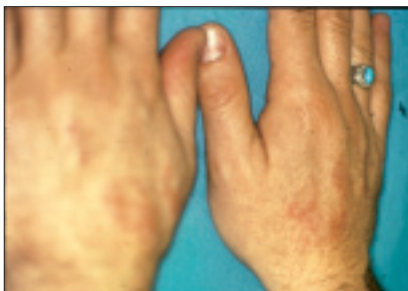Hamann CP, Turjanmaa K, Reitschel R, Siew C, Owensby D, Grunninger SE, and other. Natural rubber latex hypersensitivity: incidence and prevalence of type I allergy in the dental professional. *J Amer Dent Assoc* 1998; 129(1):43-54.

Jaeger D, Kleinhans D, Czuppon AB, Baur X. Latex-specific proteins causing immediate-type cutaneous, nasal, bronchial, and systemic reactions. *J Allergy Clin Immunol* 1992; 89(3):759-68.

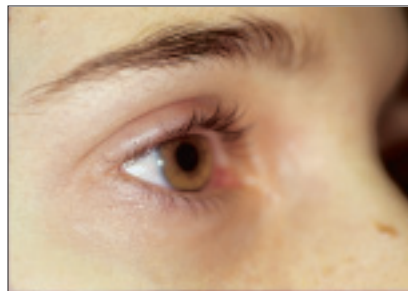
Poley GE Jr, Slater JE. Latex allergy. *J Allergy Clin Immunol* 2000; 105(6 Pt 1):1054-62.

Sussman GL, Tarlo S, Dolovich J. The spectrum of IgE-mediated responses to latex. *JAMA* 1991; 265(21):2844-7.

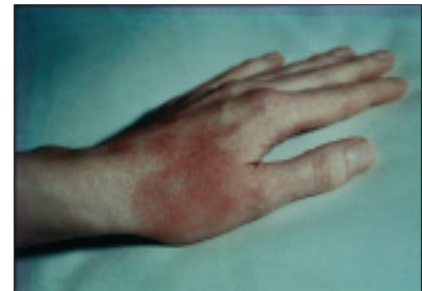Reitschel RL, Mathias CG, Taylor JS, Storrs FJ, Sherertz EF, Pratt M, and others. A preliminary report of the occupation of patients evaluated in patch test clinics. *Amer J Contact Dermat* 2001; 12(2):72-6.



**Figure 1:** Cutaneous type I reaction to natural rubber latex in latex examination gloves.



**Figure 2:** Anaphylactic conjunctivitis from aerosolized latex protein allergens.



**Figure 3:** Contact dermatitis (type IV hypersensitivity) on hand of dental hygienist after challenge with chemical accelerators used in latex glove manufacturing process.

## Question 4 What are the technical advantages and disadvantages of adopting digital radiography in my office?

Digital radiography is already seen as the up-and-coming technology that will replace film-based imaging technology.

What is the difference between film-based imaging and sensor-based imaging? The answer is a simple one. The x-ray film is being replaced by an electronic sensor based on 1 of 2 main technologies: the CCD (charged coupled device) or the CMOS (complimentary metal oxide semiconductor device). To date, only one company uses the latter (Shick Systems). Image acquisition is identical, with results so similar that it is difficult to distinguish one system from the other. The difference between different companies' systems is their software programming. A third type of system is the wireless storage phosphor system (SP).

At the University of the Pacific all available digital systems were tried, and they all had advantages and disadvantages. The dental school selected a CCD system. The decision was based on cost as well as the proximity of the company servicing the system. The students use only digital imaging for endodontic procedures and for 50% of full-mouth radiographs (7 to 8 sets).

### Advantages of Digital Radiography

The most important advantage is a reduction in the amount of radiation given to patients. Digital radiography requires one-third of the radiation needed with ultra-speed film. The reduction is smaller, however, when comparison is made with high-speed films like Insight F speed film.

A digital sensor (Fig. 1) placed with its holding device in the oral cavity allows the practitioner to view the area imaged in a fraction of a minute. If the sensor has been incorrectly placed, a slight position change will allow immediate correction of the image location or quality, saving considerable time in the case of endodontic and surgical procedures.

Film contrast and sharpness cannot be modified, while an image obtained by digital technology can be adjusted for contrast, positive/negative image and colourization, all features that enhance diagnostic abilities.

There is no longer a requirement to purchase and store film-processing chemicals, and maintenance costs for film-processing equipment are eliminated.

The display of digital images on a computer monitor in the operator makes for a powerful patient education tool.

### Disadvantages of Digital Radiography

The size (especially the thickness) of the sensor is still greater than the size of x-ray film. As a result, the sensor is



**Figure 1:** The sensor for the Dexis digital radiography system measures 1.5 inches  $\times$  1.14 inches  $\times$  0.3 inches.

more rigid than conventional film. Obtaining images of child patients may therefore be difficult, although the SP systems seem to override this problem. With the SP system, the sensor is like a celluloid film which, after exposure, needs to be scanned into the computer. This increases image acquisition time considerably. The average time needed is 2 minutes; other sensors allow instant imaging.

There may be some difficulty with positioning of the sensor, initially at least. Some dentists find that retakes are needed more often than with film.

The sensors are reusable, but cannot be sterilized. Care must therefore be taken to use proper barriers to prevent cross-infection. ♦

*Dr. Thomas Schiff is professor and chair of the maxillofacial radiology department of the University of the Pacific, School of Dentistry, San Francisco, California. E-mail: TSCHIFF@Pacific.edu. He has no declared financial interest in the companies manufacturing the types of products mentioned in this response.*

*Dr. Schiff's seminar "All You Ever Wanted to Know about Radiography but Were Afraid To Ask!" will be presented on Thursday, March 4.*

### Further Reading

- Miles DA. The deal on digital: the status of radiographic imaging. *Compend Contin Educ Dent* 2001; 22(12):1057–62.
- Parks ET, Williamson GF. Digital radiography: an overview. *J Contemp Dent Pract* 2002; 3(4):23–39.
- Van der Stelt PF. Principles of digital imaging. *Dent Clin North Am* 2000; 44(2):237–48. (This edition of *Dental Clinics of North America*, titled "Applications of Digital Imaging Modalities for Dentistry," is available to CDA members from the Resource Centre.)



For more information on the joint PDC/CDA conference, visit [www.pacificdentalonline.com](http://www.pacificdentalonline.com).