

# Clinical Showcase

*Clinical Showcase is a series of pictorial essays that focus on the technical art of clinical dentistry. This new section features step-by-step case demonstrations of clinical problems encountered in dental practice. This month's article is by Dr. Louis Malcmacher, one of the featured speakers at the 2004 Pacific Dental Conference, presented in partnership with the Canadian Dental Association. The conference will take place in Vancouver, B.C., from March 4 to 6. If you would like to propose a case or recommend a clinician who could contribute to Clinical Showcase, contact editor-in-chief Dr. John O'Keefe at [jokeefe@cda-adc.ca](mailto:jokeefe@cda-adc.ca).*

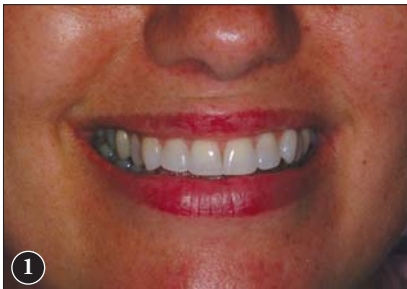## A New Twist to One-Hour Tooth-Whitening

Dr. Louis Malcmacher, DDS, FAGD

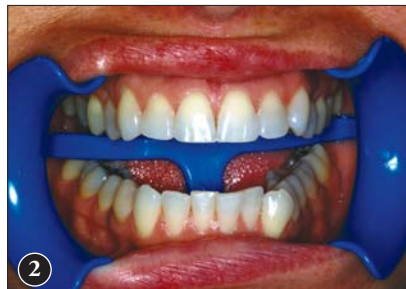Tooth whitening has undergone significant developments in the past few years with the advent of systems that can whiten teeth in one hour. Dentists have been very successful in this area of cosmetic dentistry, as they become familiar with proper technique and case selection. However, tooth whitening remains a challenging and sometimes frustrating procedure.

This article presents a new twist to the traditional one-hour whitening technique that has helped overcome some

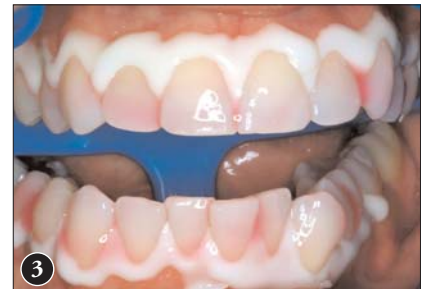of the initial challenges inherent in the procedure. Improvements to the one-hour process include etching the teeth before the application of the peroxide gels, wrapping the teeth to keep the oxygen released by the peroxide close to the enamel, and sealing the whitened teeth with an unfilled resin. Patients report greater satisfaction with this one-hour whitening process, as well as continued whitening for a few days afterwards.



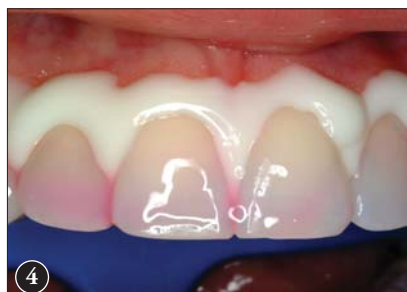**Figure 1:** This woman was not happy with the yellow colour of the cervical areas of the teeth. She tried wearing tooth-whitening trays but found that her teeth became very sensitive. She wanted to try one-hour whitening.



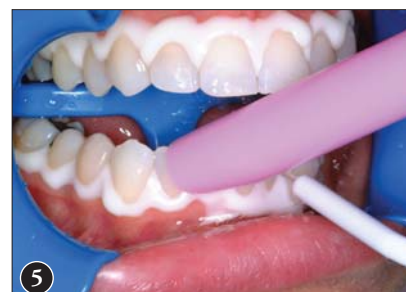**Figure 2:** Good retraction is crucial because the powerful peroxide materials can harm soft tissues.



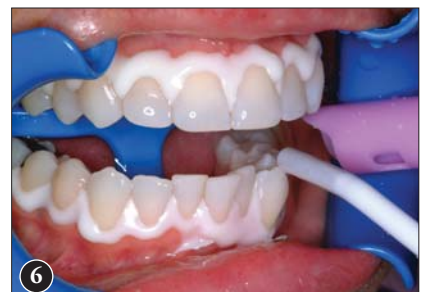**Figure 3:** Protecting the soft tissues is key to eliminating sensitivity. A dental dam resin is applied to the dry gingival tissues and cured into place. Most of the sensitivity comes from the peroxide formulations attacking exposed dentin in the cervical regions of the teeth. Great care must therefore be taken to completely cover these areas as well.



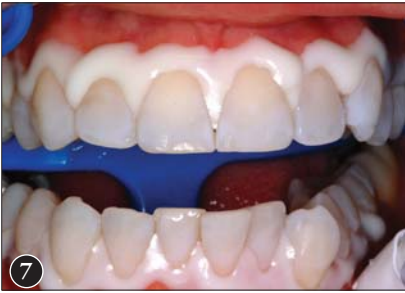**Figure 4:** A 37% phosphoric acid gel etchant is applied to the teeth for 5 seconds.



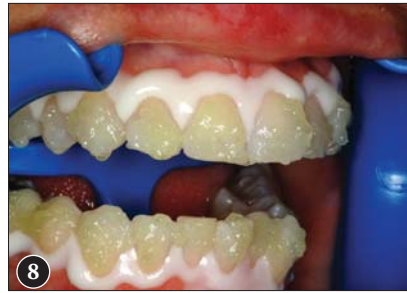**Figure 5:** The etchant is thoroughly washed off the teeth.



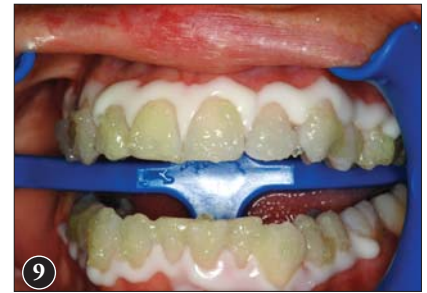**Figure 6:** The teeth are lightly dried.



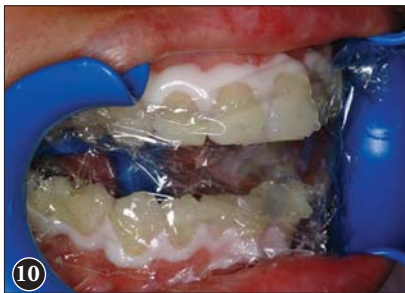**Figure 7:** The dried teeth will have a frosted appearance.



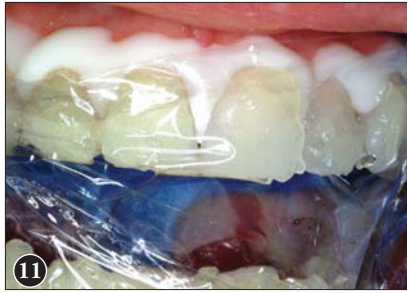**Figure 8:** A 35% hydrogen peroxide teeth whitening gel (Rembrandt Lightning Plus, Denmat Corporation, Santa Maria, Calif.) is applied to the freshly etched teeth in 1-mm-thick increments. This gel has a potassium nitrate desensitizer to help eliminate sensitivity.



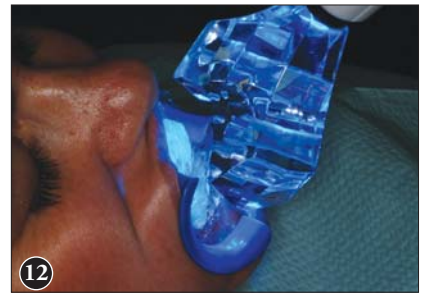**Figure 9:** Front view of the whitening gel applied to the teeth.



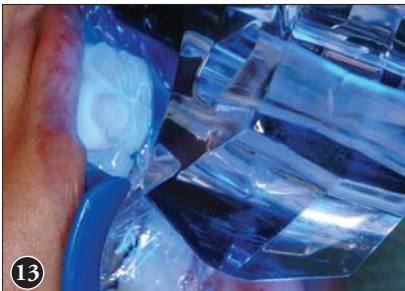
**Figure 10:** A cellophane wrap is placed gently on the gel. Care should be taken not to push the gel onto the soft tissues.



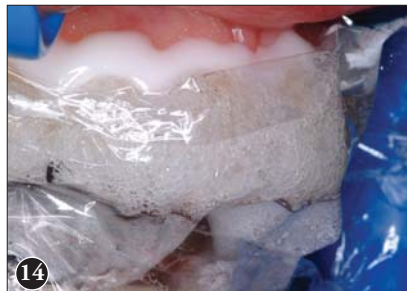**Figure 11:** The wrap keeps any oxygen release directed towards the enamel instead of dissipating into the air. More oxygen is thus available to whiten the teeth.



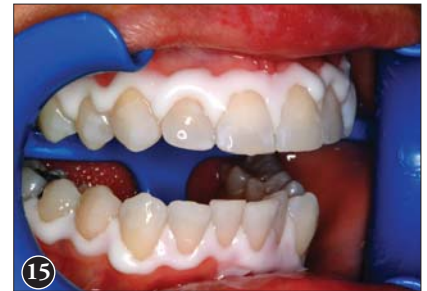**Figure 12:** A plasma arc light (Rembrandt Sapphire Light, Denmat Corporation) with a light-diffusing device (Rembrandt Crystal, Denmat Corporation) is placed close to the teeth.



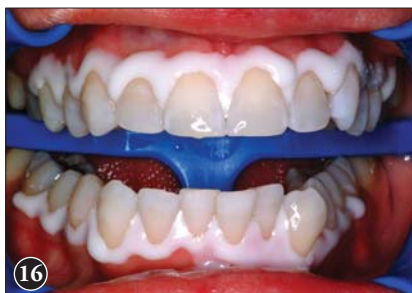**Figure 13:** The plasma arc light is left for approximately 40 minutes.



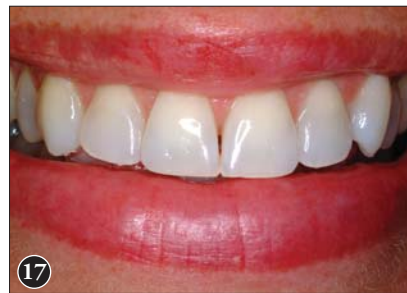**Figure 14:** Oxygen release associated with the 35% peroxide formula is significant. The captured oxygen is directed towards the teeth, thanks to the cellophane wrap.



**Figure 15:** The teeth are milky white after the cellophane wrap and the whitening gel are removed.



**Figure 16:** Clear unfilled resin sealant has been painted on the teeth and light-cured to seal the enamel pores that were opened with the etchant. Failure to seal the teeth after the procedure would result in immediate colour absorption once the patient imbibes any kind of chromogenic liquid.



**Figure 17:** Postwhitening smile with the yellow cervical stains removed.

Improvements to the one-hour tooth-whitening process include use of a cellophane wrap, as well as an etchant and a clear sealant, to deepen the whitening effect of the peroxide gel. Care must be taken to always protect the soft tissues from the strong whitening gels.

This case also illustrates how, when done properly, one-hour tooth whitening can be used in place of tray whitening if there are problems with tooth sensitivity, which can also be minimized by waiting at least one week after the patient has had a prophylaxis and by making sure all cervical lesions and areas are well covered, either with a restorative material or a dental dam. ♦

---

*Dr. Malcmacher is an internationally known lecturer and author. He maintains a general and cosmetic practice in Bay Village, Ohio.*

*Correspondence to: Dr. Louis Malcmacher, 27239 Wolf Rd, Bay Village, Ohio 44140. E-mail: dryowza@iname.com.*

*The author has no declared financial interests in any company manufacturing the types of products mentioned in this article.*



*Dr. Malcmacher's seminar "Advanced Esthetic Dentistry and Practice Management for Every Dental Practice" will be presented on Thursday, March 4. For more information on the joint PDC/CDA conference, visit [www.pacificdentalonline.com](http://www.pacificdentalonline.com).*

---