

Endodontic Treatment of Bilaterally Occurring 4-rooted Maxillary Second Molars: Case Report

• Adil H. Alani, BDS, HDD, PhD •

A b s t r a c t

The presence of 4-rooted maxillary second molars has been described in only a limited number of case reports. Studies of anatomical features have demonstrated substantial variation in the number of roots and root canals in different teeth. The maxillary second molar usually has 1, 2, or 3 roots and generally 3 or 4 root canals. This case describes the presence of 4 roots occurring bilaterally in maxillary second molars in one patient.

MeSH Key Words: case report; molar/abnormalities; tooth root/abnormalities

© J Can Dent Assoc 2003; 69(11):733-735
This article has been peer reviewed.

The principal objective of root canal treatment is to relieve pain, eliminate bacteria from the root canal and prevent reinfection. A clear understanding of root morphology and canal anatomy is an essential prerequisite to achieving clean, disinfected and 3-dimensionally obturated root canal systems. Undetected extra roots or root canals are a major reason for failure of root canal treatment.¹

Many of the challenges faced during root canal treatment may be directly attributed to an inadequate understanding of the canal morphology of teeth. Human molars show considerable anatomic variation and abnormalities with respect to number of roots and root canals. Unusual canal anatomy associated with the maxillary molars has been investigated in several studies.^{2,3} Most reports have focused on the morphology of the mesiobuccal root and particularly on its mesiopalatal canal.^{4,5} However, Christie and others⁶ have reported a variation in the number of roots and an unusual morphology of root canal systems in maxillary molars.

Radiographs are an important and necessary aid in root canal treatment, and accurate radiographic techniques and proper interpretation are essential for sound diagnosis and treatment. The use of preoperative radiographs is the best way to detect and evaluate root canal morphology and anatomy. Further radiographs should be taken at different angles to confirm any variation in anatomical features.⁷

The purpose of this clinical report is to describe the unusual anatomy of bilaterally occurring, 4-rooted maxillary second molars detected during routine root canal treatment.

Case Report

A 35-year-old woman was referred for root canal treatment of the right maxillary second molar. Two general dental practitioners had started root canal treatment. The tooth was asymptomatic and free from any clinical signs. A diagnostic radiograph revealed radiolucencies in the periapical area. The diagnosis of asymptomatic chronic apical periodontitis was made. Careful examination of the radiographs revealed the possibility of more than 1 palatal root (Fig. 1). The medical history was noncontributory.

Clinical examination revealed that both right and left maxillary first molars had been extracted and that mesial migration of the maxillary second molars had occurred. The tooth was anesthetized and isolated with a rubber dam, and access to the pulp chamber was achieved using a round diamond bur (ISO 801001016, Komet, Lemgo, Switzerland). Clinical evaluation of the internal anatomy confirmed the presence of 4 root canal orifices, 2 located buccally and 2 palatally (Fig. 2). The working lengths of each canal were estimated by means of an electronic apex locator (Root ZX, Morita, Tokyo, Japan), then confirmed by a radiograph. The canals were initially instrumented with #15 nickel titanium files (Dentsply Maillefer, Ballaigues, Switzerland) under irrigation with 5% sodium hypochlorite (NaOCl), then dried with sterile paper points.

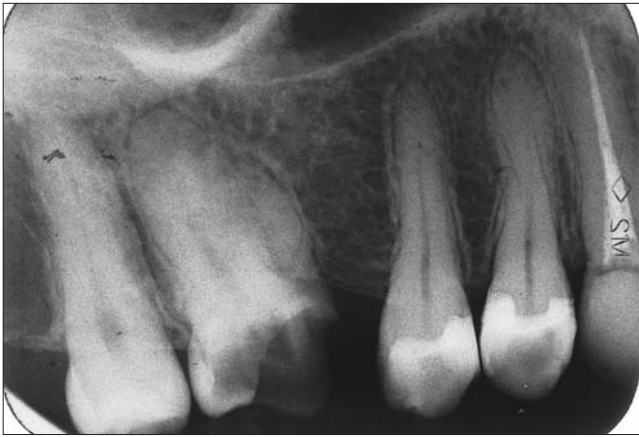

Figure 1: Preoperative radiograph of maxillary right second molar.




Figure 2: Clinical examination showing 4 root canal orifices: 2 located buccally and 2 palatally.

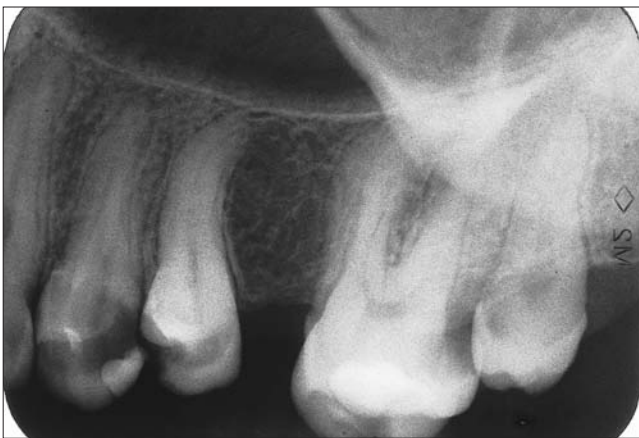

Figure 3: Preoperative radiograph of maxillary left second molar.

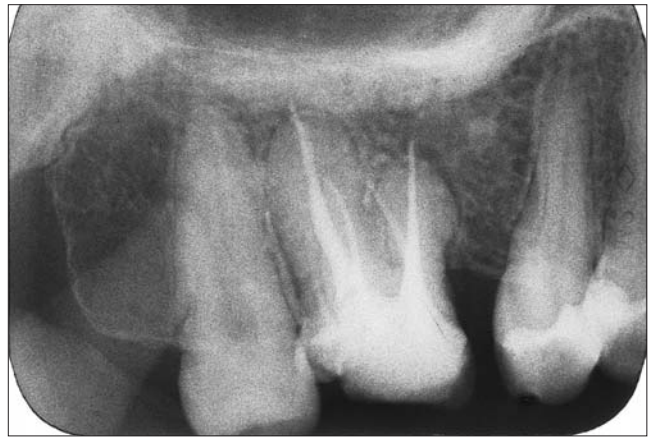

Figure 4a: Postoperative radiograph showing obturation of bilateral 4-rooted maxillary second molar.

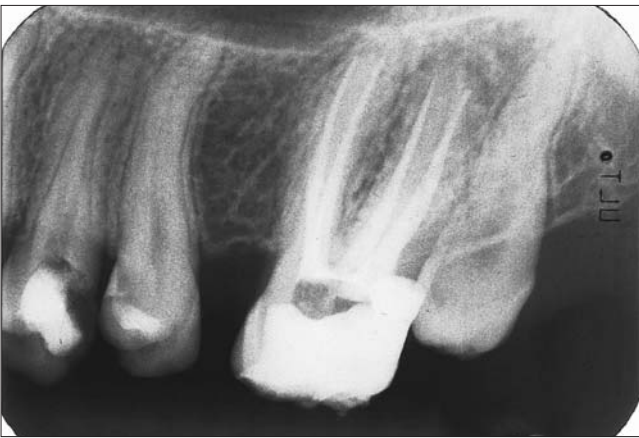

Figure 4b: Postoperative radiograph showing the separation and divergence of the 4-rooted maxillary second molar.

Calcium hydroxide paste (Produits Dentaires S.A., Vevey, Switzerland) was used as an intracanal medicament. A sterile cotton pellet was placed in the pulp chamber, and IRM cement (Dentsply De Trey GmbH, Konstanz, Germany)

was used to seal the access cavity after each appointment as a temporary filling to prevent coronal leakage.

After 3 days, the patient presented with severe pain in the left maxilla. Clinical examination revealed that the maxillary second molar had deep cervical caries. Thermal testing with ethyl chloride produced severe, long-lasting pain. There was no evidence of periapical radiolucency, but an interproximal carious lesion (distally) was confirmed. A diagnosis of irreversible pulpitis was established. Careful examination of the radiograph disclosed the presence of 4 roots (Fig. 3). The tooth was anesthetized and isolated with a rubber dam; access was gained using a round diamond bur. Caries was simultaneously removed. Pulp extirpation was carried out to relieve initial symptoms. Four root canal orifices were clearly identified, similar to those observed in the right maxillary second molar: 2 buccal and 2 palatal. The distance between the orifices of the 2 palatal roots was approximately 5 mm. Loupe magnification ($\times 3.5$) was used to clearly identify the number of canal orifices.

Root canal treatment was scheduled over 2 visits for each tooth because of the complexity of the root canal systems.

By the second appointment, all symptoms had disappeared. Coronal flaring was carried out using Gates Glidden burs (numbers 3 and 2; Dentsply Maillefer). All canals were cleaned and prepared by hand with nickel titanium files using a crown-down technique similar to that described by Saunders and Saunders.⁸ One week later, all canals were obturated with Tubli-seal (Kerr UK, Peterborough, U.K.) and laterally condensed gutta-percha points. Final radiographs were taken to establish the quality of the obturation (Figs. 4a and 4b). After completion of root canal treatment, the right maxillary second molar was fitted with a post and core with a porcelain-fused-to-metal crown; the left maxillary second molar was restored with a posterior composite filling (Z250, 3M Dental Products, St. Paul, Minn.).

Discussion

This report highlights the unusual anatomy of the maxillary second molar occurring bilaterally in the same patient. Most endodontic and dental anatomy textbooks describe the maxillary second molar as having 3 roots with 3 or 4 root canals.^{9–11} The reported percentage of 2-rooted maxillary molars ranges from 0–12%^{5,9} to 15%.¹² The prevalence of maxillary second molars with 4 roots (2 buccal and 2 palatal) is rare; a review and radiographic survey¹³ of 1,200 teeth found only 0.4% exhibiting this condition, which is rarer still in maxillary first molars. The possibility of maxillary second molars with 1 root and 1 root canal has been described in only a few textbooks.¹⁴ Studies¹⁵ have reported 0.6% of maxillary second molars with 1 root canal and, recently, Peikoff and others¹⁶ demonstrated that 3.1% of endodontically treated maxillary second molars had 1 root and 1 canal.

In certain circumstances, root canals may be left untreated during endodontic therapy if the practitioner is unable to detect their presence.¹⁷ The presence of extra roots is readily determined using routine radiography, as was demonstrated in the current case. However, teeth with extra canals and a normal number of roots present a greater challenge in terms of diagnosis and treatment. Extra root canals may be difficult to identify because of their superposition over other root canals or, sometimes, their relatively small size. Careful examination of the preoperative radiograph will aid in the detection of extra canals. Knowledge of anatomic aberrations, such as root position, root shape and relative root outline will also help decrease the failure rate of root canal therapy.

The current case demonstrated bilateral abnormality in maxillary second molars. Yew and Chan¹⁸ reported bilateral symmetry in 67% of cases of 3-rooted mandibular first molars, whereas Tamse and Kaffe¹⁹ found bilateral symmetry in 89.65% of cases of single conically rooted mandibular second molars. The findings of Peikoff and others¹⁶ were consistent with these studies; however, in many cases of contralateral pairs, where endodontic treatment was

performed, although the dental anatomy was similar, the bilateral symmetry was not always perfect.

Christie and others⁶ have proposed a classification system describing 3 types (I–III) of 4-rooted maxillary second molar abnormalities, based on root separation level and their divergences. Under this system, the maxillary left second molar (Fig. 3) presented here could be considered a type II molar (well-separated roots). The maxillary right second molar (Fig. 1) could fall into a new type IV category,²⁰ representing that of conjoined buccal and palatal root trunks. Deveaux²¹ presented a similar case in which endodontic treatment was performed on a maxillary second molar exhibiting 2 palatal roots classified as type II under this system.

Access to the root canal is the initial step in canal preparation. Properly designed and prepared access cavities will eliminate many potential problems during canal preparation and obturation. In the case reported here, a large access was required to locate the 2 palatal roots. Although the size of the mesiolingual cusp is larger in first maxillary molars than in second maxillary molars, teeth with 2 palatal roots often have a wider mesiodistal dimension of the palatal cusps.⁶ The access cavity on maxillary molars exhibiting 2 palatal roots should be wider than usual on the palatal aspect. The access outline will be square rather than triangular (Fig. 2). In the current case, the 2 palatal orifices were also found to be well developed and large.

Treatment prognosis for molars with 4 canals and 2 palatal roots should be considered to be the same as that for any maxillary molar. Failure to treat a missed canal is an obvious reason for root canal treatment failure.³ Therefore, all practitioners must make every effort to locate and treat all existing canals during root canal treatment.

Conclusions

Anatomic variation in the number of roots and root canals can occur in any tooth. Examination of clear radiographs taken from different angles and careful evaluation of the internal anatomy of teeth is essential. Root canal treatment is likely to fail if extra roots or root canals are not detected. The similarity in dental anatomy might occur in any bilateral teeth. As a result, the clinician should be aware that variations in tooth morphology may well occur bilaterally. ♦

Acknowledgement: The author would like to acknowledge Dr. Roy Trimmer and Dr. David Hemerling for their support and Miss Karen Villanueva for her assistance in the preparation of this report.

Dr. Alani is head of endodontic division, Tawam Hospital, Dental Centre, Al Ain, United Arab Emirates.

Correspondence to: Dr. Adil H. Alani, Tawam Hospital, Dental Centre, P.O. Box 15258, Al Ain, United Arab Emirates. E-mail: adilalani@hotmail.com.

The author has no declared financial interests in any company manufacturing the types of products mentioned in this article.

References

1. Slowey RR. Radiographic aids in the detection of extra root canals. *Oral Surg Oral Med Oral Pathol* 1974; 37(5):762-72.
2. Malagnino V, Gallottini L, Passariello P. Some unusual clinical cases on root anatomy of permanent maxillary molars. *J Endod* 1997; 23(2):127-8.
3. Stone LH, Stroner WF. Maxillary molars demonstrating more than one palatal root canal. *Oral Surg Oral Med Oral Pathol* 1981; 51(6):649-52.
4. Fogel HM, Peikoff MD, Christie WH. Canal configuration in the mesiobuccal root of the maxillary first molar: a clinical study. *J Endod* 1994; 20(3):135-7.
5. Eskoz N, Weine FS. Canal configuration of the mesiobuccal root of the maxillary second molar. *J Endod* 1995; 21(1):38-42.
6. Christie WH, Peikoff MD, Fogel HM. Maxillary molars with two palatal roots: a retrospective clinical study. *J Endod* 1991; 17(2):80-4.
7. Fava LRG, Dummer PMH. Periapical radiographic techniques during diagnosis and treatment. *Int Endod J* 1997; 30(4):250-61.
8. Saunders WP, Saunders EM. Effect of noncutting tipped instruments on the quality of root canal preparation using a modified double-flared technique. *J Endod* 1992; 18(1):32-6.
9. Weine FS. Access cavity preparation and initiating treatment. In: Weine FS, editor. *Endodontic therapy*. 4th ed. Saint Louis (MO): C.V. Mosby; 1989. p. 245-51.
10. Ingle JI, Backland LK, Peters DD, Buchanan S, Mullaney TP. Endodontic cavity preparations. In: Ingle JI, Backland LK, editors. *Endodontics*. 4th ed. Baltimore (MD): Williams and Wilkins 1994. p. 92-227.
11. Walker RT. Pulp space anatomy and access. In: Pitt Ford TR, editor. *Harty's endodontics in clinical practice*. 4th ed. Oxford, UK: Wright; 1998. p. 16-36.
12. Al Shalabi RM, Omer OE, Glennon J, Jennings M, Claffey NM. Root canal anatomy of maxillary first and second permanent molars. *Int Endod J* 2000; 33(5):405-14.
13. Libfield H, Rotstein I. Incidence of four-rooted maxillary second molars: literature review and radiographic survey of 1,200 teeth. *J Endod* 1989; 15(3):129-31.
14. Burns RC, Herbranson EJ. Tooth morphology and cavity preparation. In: Cohen S, Burns RC, editors. *Pathways of the pulp*. 7th ed. Saint Louis (MO): C.V. Mosby; 1998. p. 150-202.
15. Hartwell G, Bellizzi R. Clinical investigation of in vivo endodontically treated mandibular and maxillary molars. *J Endod* 1982; 8(12):555-7.
16. Peikoff MD, Christie WH, Fogel HM. The maxillary second molar: variations in the number of roots and canals. *Int Endod J* 1996; 29(6):365-9.
17. Reeh ES. Seven canals in a lower first molar. *J Endod* 1998; 24(7):497-9.
18. Yew S, Chan K. A retrospective study of endodontically treated mandibular first molars in a Chinese population. *J Endod* 1993; 19(9):471-3.
19. Tamse A, Kaffe I. Radiographic survey of the prevalence of conical lower second molar. *Int Endod J* 1981; 14(3):188-90.
20. Baratto-Filho F, Fariniuk LF, Ferreira EL, Pecora JD, Cruz-Filho AM, Sousa-Neto MD. Clinical and macroscopic study of maxillary molars with two palatal roots. *Int Endod J* 2002; 35(9):796-801.
21. Deveaux E. Maxillary second molar with two palatal roots. *J Endod* 1999; 25(8):571-3.