

Facial Slot Class II Restorations: A Conservative Technique Revisited

• Nels Ewoldsen, DDS, MSD •

A b s t r a c t

Conservative instrumentation of initial posterior approximal caries is beneficial to patients and simplifies surgical management. This article describes a minimally invasive technique for preparing Class II lesions while keeping the marginal ridge and occlusal surface intact. Eradication of caries by minimally invasive techniques and restoration of tooth form after such cavity preparation necessitates specialized restorative materials that feature adhesion to tooth structure and ion exchange to facilitate remineralization. This article outlines a conservative instrumentation sequence, followed by use of a highly viscous, rapid-setting, capsulated glass ionomer cement, for the restoration of initial posterior approximal lesions.

MeSH Key Words: dental cavity preparation/methods; dental restoration, permanent/methods; glass ionomer cements

© J Can Dent Assoc 2003; 69(1):25–8
This article has been peer reviewed

Responsible management of initial carious lesions may include either noninvasive management or restorative interventions. Once the decision has been made to surgically treat an initial lesion, minimally invasive techniques should be used to preserve tooth structure, which will lessen the risk of tooth fracture, iatrogenic damage and future tooth sensitivity. Instrumentation of caries can be accomplished most conservatively if a direct-access approach is used, infected dentin removed and caries-affected dentin is allowed to remineralize. Conservative instrumentation of caries, adhesive restorations and remineralization are the core concepts of an emerging restorative attitude stressing minimally invasive dentistry. According to these concepts, tooth preparation is considered complete once a sound cavosurface margin has been established and all infected dentin has been removed. Replacement of lost tooth structure is then completed with an adhesive biomimetic, cariostatic material.

Traditional Class II amalgam preparations fall short of minimally invasive principles and are not usually optimal for the initial management of an approximal lesion.¹ Although Class II cavity preparation design has changed recently, indirect approaches are still being used to access approximal caries.^{2–5} Restorative materials have also changed, but even revised Class II preparations restored with resin-based adhesive materials require an occlusal

approach, which is frequently less direct and less conservative than access from either the facial or lingual approach.^{2,6–8} It is now worth considering new, ultraconservative, direct-access approaches for restoring approximal caries. Ultraconservative preparations require adhesive restorative materials with unique flow and fill properties, as well as the ability to chemically bond to tooth and to remineralize caries-affected dentin.

Roggenkamp and others⁹ first described the facial slot Class II cavity preparation for use with dental amalgam in 1982. This preparation, which involves accessing caries by the facial approach, followed the instrumentation sequence used for Class III preparations. When first presented, the facial slot preparation was considered ultraconservative because it allowed the most direct access to caries. Because amalgam was the recommended restorative material, mechanical retention was required. Use of an adhesive, biomimetic, cariostatic restorative material allows even more conservative preparation.

The facial slot Class II cavity preparation saves time, conserves tooth structure, offers better esthetics, does not alter occlusal relationships, may preserve a natural proximal contact and enjoys greater patient acceptability than traditional approaches. This restoration is particularly well suited to situations where interproximal relationships are compromised because of misalignment of teeth. This article

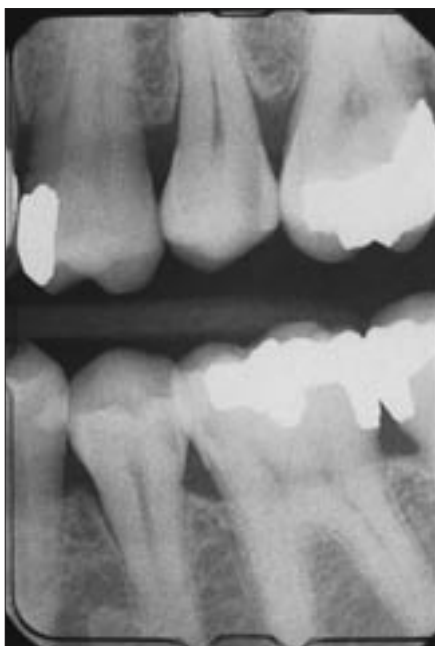

Figure 1: Preoperative radiograph indicates the need for facial slot Class II restoration in tooth 35 after placement of a conventional-approach mesio-occluso-distal amalgam restoration in tooth 36.

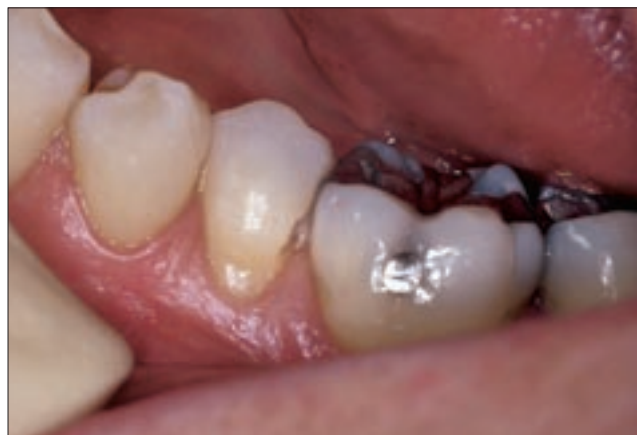

Figure 2: The approximal lesion in tooth 35 has been accessed in the most direct manner possible, and the enamel has been penetrated with a one-quarter round bur.

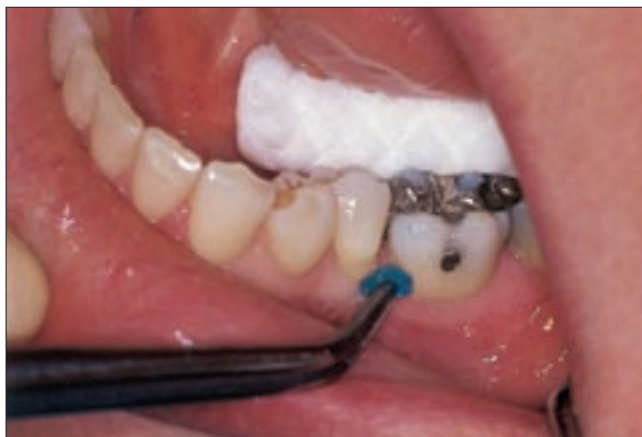

Figure 3: The preparation is conditioned for 15 seconds with Cavity Conditioner (GC America, Alsip, Ill.; 20% polyacrylic acid with 3% aluminum chloride).

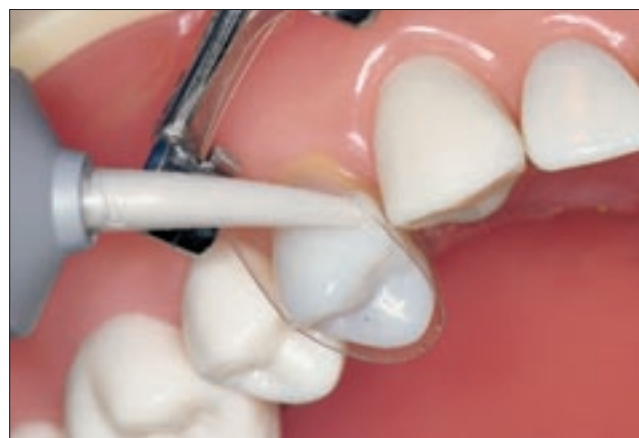

Figure 4: This Typodont (United States Dental Institute, Kingsport, Tenn.) example demonstrates placement of the capsule nozzle to deliver Fuji IX GP Fast glass ionomer (GC America) directly into the cavity after the matrix has been loosely placed. The cavity is slightly overfilled, and the matrix is then secured.

describes and illustrates the preparation of a facial slot Class II cavity and restoration with a highly viscous, rapid-setting, capsulated glass ionomer. The handling improvements associated with newer, higher-density, highly viscous glass ionomer cements (GICs) minimize the porosity and incomplete filling that are associated with less dense cements. A lingually inclined premolar with approximal caries located near the facial aspect is used here to demonstrate the clinical sequence. A post-treatment example of a facial slot Class II restoration with a (more ideal) interproximal relationship is also shown.

Croll¹⁰ reported the successful use of resin-modified and silver-cermet glass ionomers in restoring facial slot preparations. In this author's opinion, neither material advocated by Croll can be easily positioned approximally to ensure dense, void-free restorations. Resin-modified and conventional glass ionomers have lower density and are stickier than the highly viscous GICs, and they are associated with handling problems and voids in the restoration. No reports were found recommending composite resin as a restorative material for facial slot preparations, possibly because of isolation requirements, finishing difficulties and reduced potential for remineralization.

Identification and Selection Criteria

Class II lesions are candidates for facial slot preparations if they exhibit surface cavitation with some radiographic evidence of caries extending 0.5 mm into the dentin^{4,9} (**Fig. 1**). Until the caries has reached this point, evidence

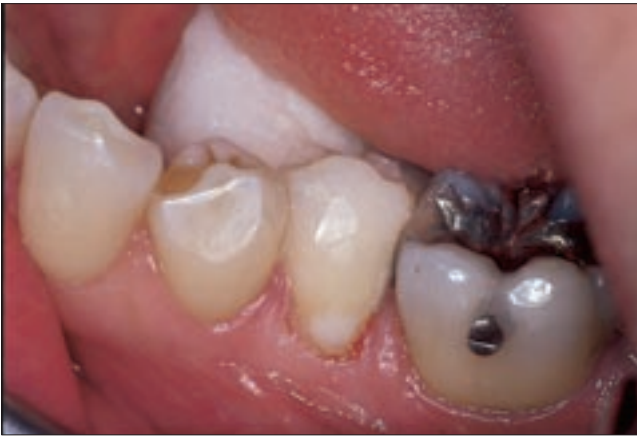

Figure 5: The matrix is removed after 3 minutes, and the peripheral excess is eliminated.

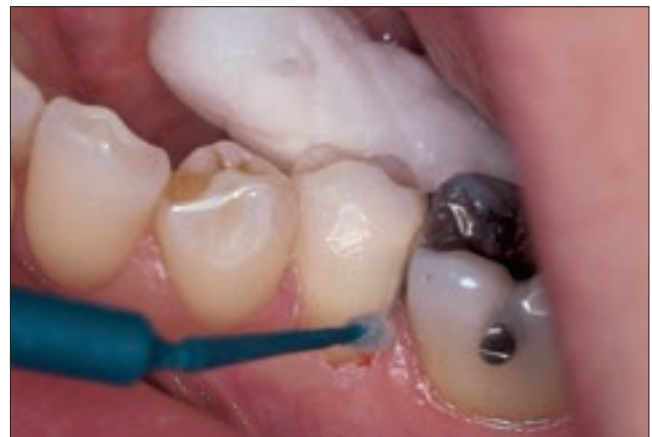

Figure 6: The restoration is protected with either Fuji Coat or Fuji Varnish (GC America).

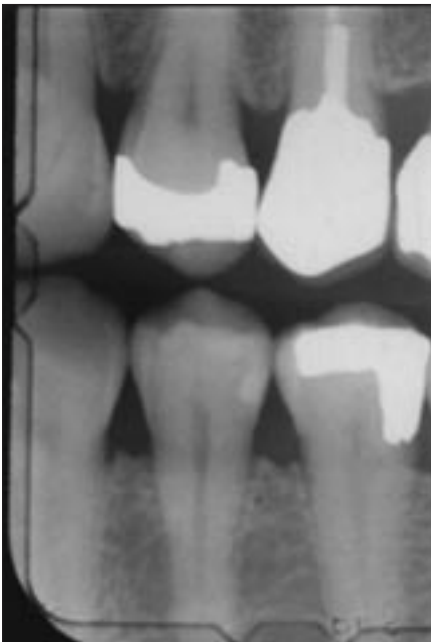


Figure 7: Radiograph of a facial slot Class II restoration (distobuccal 34) after 2¹/₂ years.

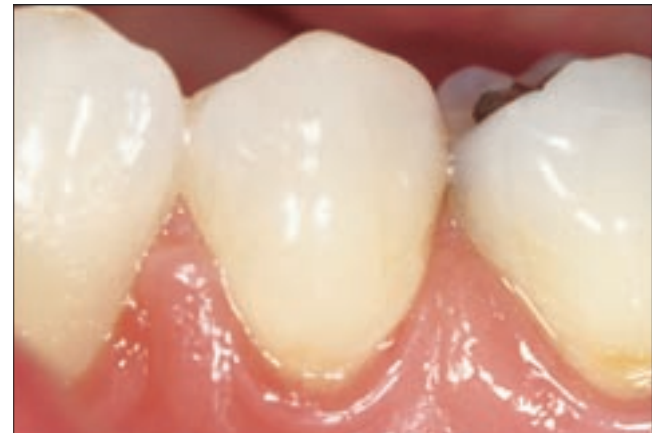

Figure 8: Clinical photograph of a facial slot restoration (distobuccal surface of tooth 34) after 2¹/₂ years.

supports the possibility of remineralization.¹¹⁻¹² Non-remineralizable lesions are candidates for facial slot preparations provided that 2 mm of intact enamel (located occlusogingivally) exists beneath the intact marginal ridge.⁹ A dental explorer may be used to establish the faciolingual extent of the lesion and to determine how the lesion can be most directly accessed. Frequently, however, the explorer provides no additional information, and in such cases it should be assumed that the lesion is centred beneath the proximal contact.

Anesthesia and Isolation

With more than 3 years' experience in using the facial slot preparation, this author recommends that more than

50% of preparations can be completed without local anesthesia. Without anesthesia, however, some patients find placement of a rubber dam clamp uncomfortable. When a rubber dam can be secured by wedge or ligation techniques, saliva control is optimal. If the procedure must be done without a dental dam, glass ionomers can be bonded even in the presence of limited amounts of saliva. Clinical reports of the successful use of a highly viscous GIC, Fuji IX (GC Corporation, Tokyo, Japan) without placement of a rubber dam indicate that isolation can be accomplished with absorbent pads, cotton rolls and a saliva ejector.^{11,13}

Instrumentation

Place an interdental wedge immediately beneath the lesion. Using a slow-speed handpiece and the smallest round bur available, access the lesion in the most direct manner possible (**Fig. 2**). Once through the enamel, use tactile skills to follow the dento-enamel junction occlusally, gingivally and lingually. If caries remain pulpally, switch to a #329 bur and remove softened dentin until sufficient

space exists to insert a small spoon excavator. Excavate the lesion until the spoon “rings” against affected dentin. At this point all infected dentin will have been removed. Use the spoon to excavate around the cavosurface margin to ensure extension into sound enamel.

Restoration

Before applying Cavity Conditioner (GC America, Alsip, Ill.), use reflected vision and a dental explorer to ensure that the preparation is complete and free of debris. Then position but do not tighten a Toffelmire-type matrix system. Leave the matrix loose to allow access to the cavity. Conditioner may be applied before or after placement of the matrix, as it will not etch the adjacent tooth structure (Fig. 3). Apply the conditioner for 15 seconds and rinse.

Blot away excess moisture with a cotton pellet (but do not dry the cavity) as the assistant activates and mixes the Fuji IX GP Fast capsulated glass ionomer.

With the matrix band still loose, place the cement capsule nozzle as close to the access site as possible, but sufficiently offset from the opening to allow venting and to prevent air entrapment. Figure 4 illustrates this step with a mock-up for better visibility. Deliver cement until overflow is evident. Immediately tighten the matrix band and allow it to remain in place for 3 minutes, to protect the setting glass ionomer from early contact with saliva as well as cracking due to dehydration. Tightening of the matrix band compresses the Fuji IX GP Fast glass ionomer into the cavity and frequently results in a dense, complete fill. After 3 minutes, remove the matrix, eliminate the excess material (Fig. 5), apply a protective coating (Fuji Coat, GC America) to the immature glass ionomer (Fig. 6), and light-cure for 10 seconds.

Discussion

The radiopacity of Fuji IX GP Fast glass ionomer is greater than that of other high-viscosity glass ionomers (3.7 mm aluminum), and the capsule design allows controlled delivery of the compound into inaccessible areas. It is reassuring to confirm the quality of the restoration radiographically, but immediate postoperative radiographs are only indicated if post-treatment sensitivity or other problems arise. However, the density and pressability of highly viscous conventional glass ionomers results in excellent filling of even the least accessible lesions. The ability of GICs to remineralize dentin affected by caries has been reported, and Fuji IX GP Fast glass ionomer has shown excellent cariostasis when used as a field restorative.¹¹ Post-treatment sensitivity is rarely reported with the technique described above. Chair time is significantly reduced because occlusal adjustment and marginal ridge carving are not necessary. Figures 7 and 8 show a post-treatment radiograph and slide of a distofacial restoration in tooth 34 after 2¹/₂ years of service.

The facial slot Class II cavity preparation, first described by Roggenkamp and others,⁹ and modified for use with GIC restoratives by Croll,¹⁰ represents a time-saving, tooth-saving, minimally invasive approach that yields an esthetic restoration acceptable to patients. This conservative approach represents responsible management of initial Class II carious lesions. ♦

Acknowledgment: A special thank-you is extended to Mr. David R. Riggerbach and Dr. Jeffrey B. Payne, UNMC College of Dentistry, for preoperative and post-treatment radiographs.

Dr. Ewoldsen is adjunct associate professor, adult restorative dentistry, UNMC College of Dentistry, Lincoln, NE. He is also director, clinical research and education, DENTSPLY Trubyte, York, PA. Formerly, he was director of new technologies and development at GC America.

Correspondence to: Dr. Nels Ewoldsen, 944 Country Club Road, York, PA 17403. E-mail: newoldsen@dentsply.com.

The author has no declared financial interests in any company manufacturing the types of products mentioned in this article.

References

1. Caron GA, Murchison DF, Cohen RB, Broome JC. Resistance to fracture of teeth with various preparations for amalgam. *J Dent* 1996; 24(6):407-10.
2. Castillo MD. Class II composite marginal ridge failure: conventional vs. proximal box only preparation. *J Clin Pediatr Dent* 1999; 23(2):131-6.
3. el-Mowafy OM. Fracture strength and fracture patterns of maxillary premolars with approximal slot cavities. *Oper Dent* 1993; 18(4):160-6.
4. Oderra M. Conservative amalgam restoration of Class II lesions – the “slot” restoration: a case report. *Quintessence Int* 1994; 25(7):493-8.
5. McMaster DR, House RC, Anderson MH, Pelleu GB Jr. The effect of slot preparation length on the transverse strength of slot-retained restorations. *J Prosthet Dent* 1992; 67(4):472-7.
6. Gorucu J, Tiritoglu M, Ozunaltay G. Effects of preparation designs and adhesive systems on the retention of Class II amalgam restorations. *J Prosthet Dent* 1997; 78(3):250-4.
7. Knight GM. The tunnel restoration – nine years of clinical experience using capsulated glass ionomer cements. Case report. *Aust Dent J* 1992; 37(4):245-51.
8. Hilton TJ, Ferracane JL. Cavity preparation factors and microleakage of Class II composite restorations filled at intraoral temperatures. *Am J Dent* 1999; 12(3):123-30.
9. Roggenkamp CL, Cochran MA, Lund MR. The facial slot preparation: a non-occlusal option for Class 2 carious lesions. *Oper Dent* 1982; 7(3):102-6.
10. Croll TP. Lateral-access Class II restoration using resin-modified glass-ionomer or silver-cermet cement. *Quintessence Int* 1995; 26(2):121-6.
11. Frencken JE, Makoni F, Sithole WD. ART restorations and glass ionomer sealants in Zimbabwe: survival after 3 years. *Community Dent Oral Epidemiol* 1998; 26(6):372-81.
12. Pitts NB. The use of bitewing radiographs in the management of dental caries: scientific and practical considerations. *Dentomaxillofac Radiol* 1996; 25(1):5-16.
13. Weerheijm KL, Kreulen CM, Gruythuisen RJ. Comparison of retentive qualities of two glass-ionomer cements used as fissure sealants. *ASDC J Dent Child* 1996; 63(4):265-7.