

Replantation of an Avulsed Incisor After Prolonged Dry Storage: A Case Report

- Shiu-yin Cho, BDS, MDS •
- Ansgar C. Cheng, BDS, MS •

A b s t r a c t

Management of tooth avulsion in the permanent dentition often presents a challenge. Definitive treatment planning and consultation with specialists is seldom possible at the time of emergency treatment. Replantation of the avulsed tooth can restore esthetic appearance and occlusal function shortly after the injury. This article describes the management of a child with an avulsed maxillary permanent incisor that had been air-dried for about 18 hours. The replanted incisor retained its esthetic appearance and functionality 2 years after replantation, yet the long-term prognosis is not good because of progressive replacement root resorption.

MeSH Key Words: *incisor/injuries; tooth avulsion/therapy; tooth replantation*

© J Can Dent Assoc 2002; 68(5):297-300
This article has been peer reviewed.

Tooth avulsion is defined as total displacement of the tooth out of its alveolar socket. It accounts for 0.5% to 16% of traumatic injuries in the permanent dentition.¹ Avulsion of permanent teeth occurs most often in children 7 to 9 years old, an age when the relatively resilient alveolar bone provides only minimal resistance to extrusive forces, and the maxillary central incisors are the teeth most commonly affected.¹ Management of avulsion of the permanent dentition often presents a challenge. Healing with a normal periodontal ligament (i.e., regeneration) after replantation will occur only if the innermost cell layers along the root surface are vital.¹ Clinical studies have shown that the prognosis is best for teeth replanted within 5 minutes after avulsion,²⁻⁶ yet such optimal treatment is not always possible.

Prolonged non-physiological storage of avulsed teeth before replantation results in total necrosis of the periodontal ligament, and healing by replacement root resorption (i.e., repair) becomes the only option.⁵ In this situation, the periodontal ligament, as well as the root surface of the replanted tooth, is resorbed and replaced by the surrounding alveolar bone, a process that results in ankylosis.¹ Ankylosis of the teeth in young patients eventually leads to infraocclusion, because of growth.⁷ If the resorption process exposes dentinal tubules and root canals that

contain infected necrotic tissues, inflammatory root resorption may also occur. Nevertheless, if managed properly, avulsed teeth with avital periodontal ligament can be replanted and will remain functional for some years.⁸ This article describes the management of a child with an avulsed maxillary permanent incisor that had been air-dried for about 18 hours.

Case Report

The patient, an 11-year-old boy, attended for emergency treatment during an afternoon session. He had slipped and fallen at a playground the previous evening, and his tooth 11 had been avulsed. The avulsed tooth had been left dry in an uncovered plastic container after the injury. The patient's medical history was unremarkable, but he was due for an antitetanus booster. On examination, the patient did not show any signs or symptoms of neurological or extraoral injury, and he presented with a class I skeletal relationship. The intraoral examination revealed late mixed dentition with mild crowding in the lower canine regions. In occlusion, he showed incisal overjet of 5 mm and class I molar relationships. Oral hygiene was fair, and no carious lesions were detected clinically. Tooth 11 was avulsed, and a blood clot was found in the alveolar socket. No other oral injury was detected clinically. All of the adjacent teeth showed positive response to a vitality test. A maxillary occlusal

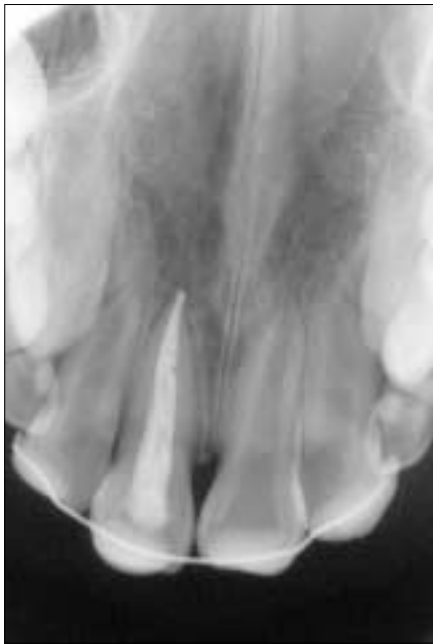

Figure 1: Maxillary occlusal radiograph taken immediately after replantation shows proper repositioning of avulsed tooth 11.

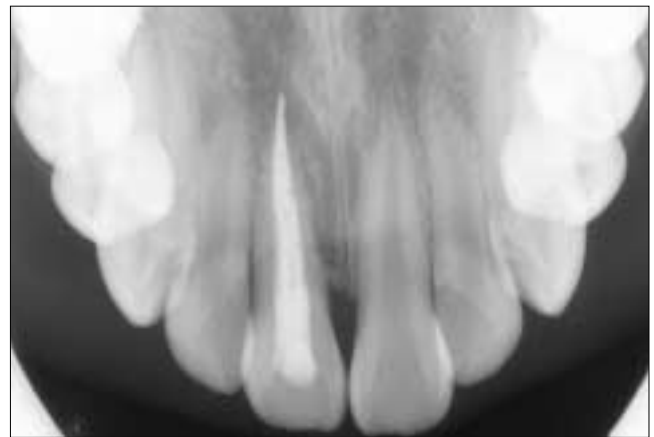


Figure 2: Radiograph taken 2 years after replantation. Replacement root resorption of tooth 11 is obvious.

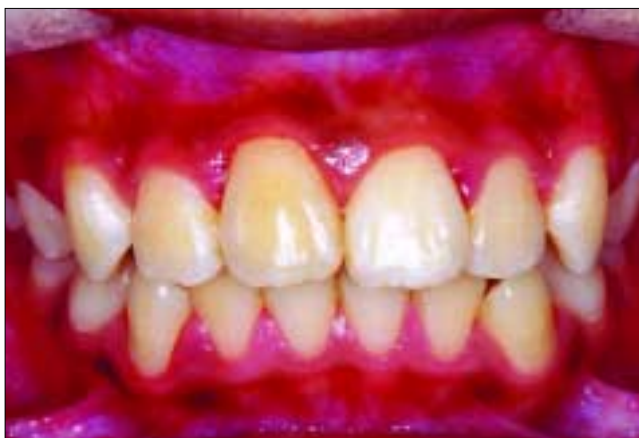

Figure 3: Anterior view of the replanted incisor 2 years after replantation. Mild infraocclusion of tooth 11 is visible.

radiograph was obtained, and no other hard-tissue injury was detected in that region. Examination of the avulsed tooth revealed that the crown was intact and that the root had a nearly closed apex, but the root surface was covered with dried remnants of periodontal tissue. It was estimated that the avulsed tooth had been kept dry for about 18 hours.

The available treatment options were explained to the parent, and it was decided to replant the avulsed incisor as an intermediate treatment. Local anesthetic was administered and the blood clot removed from the socket. The root of the avulsed tooth was planed to remove the necrotic periodontal tissue and was then filled with gutta-percha points and sealer. The tooth was then replanted into its socket and was splinted to the adjacent teeth with 0.018 × 0.025 inch

stainless steel rectangular wire and composite. Another maxillary occlusal radiograph was obtained to confirm proper positioning of the replanted incisor (Fig. 1), and the splint was left in place for 6 weeks. A 7-day course of systemic penicillin was prescribed, and the patient was referred to the medical practitioner for an antitetanus booster. The patient was seen again at 2, 6 and 12 weeks after replantation and then half-yearly. At the time of writing, the patient had been followed for 2 years. The replanted incisor developed mild infraocclusion (of about 1 mm) and progressive replacement root resorption (Fig. 2). Nevertheless, it remained functional and was esthetically acceptable (Fig. 3). All of the adjacent anterior teeth remained symptomless and showed no sign of pulp death or root resorption.

Because both the patient and his parent wanted to avoid orthodontic treatment in the future, it was decided to keep the replanted incisor as long as possible. The patient and his parent were informed that the infraocclusion would become more severe as the patient grew and that esthetic buildup of the incisal edge with composite resin might be needed. The replanted incisor will be replaced with a prosthesis when its root has been totally resorbed. Long-term treatment may also include prosthodontic replacement with an implant when the patient finishes his pubertal growth.

Discussion

Relative to other tooth injuries, avulsion is a more serious assault on the gingiva, the periodontal ligament and the pulp. In clinical studies, teeth replanted within 5 minutes after avulsion had the best prognosis and the chance of pulpal and periodontal healing was inversely related to the stage of root development and the period of dry storage.³⁻⁶ In the optimal scenario, the avulsed tooth should be replanted immediately or should be stored in a physiological medium such as saline for only a short period before replantation.^{9,10} The replanted tooth should be splinted

flexibly to the adjacent teeth for 7 to 10 days to enhance periodontal healing.¹⁰ If the tooth apex is closed or almost closed, prophylactic root canal treatment should be carried out on the day of splint removal to prevent the onset of inflammatory root resorption.^{1,10}

In the case presented here, the avulsed incisor had a nearly closed apex and had been air-dried for a prolonged period, so it was anticipated that the chance of pulpal and periodontal healing would be extremely low. As a result, the management of this case differed from the accepted replantation protocol. The treatment objective was to retain the avulsed incisor to maintain esthetic appearance and occlusal function, to prevent inflammatory root resorption and to achieve periodontal healing with replacement root resorption. Therefore, the avulsed incisor was splinted to the adjacent teeth with rigid wire for 6 weeks to facilitate rapid, solid ankylosis.^{1,8} The root of the avulsed incisor was also filled extraorally. Given that replacement root resorption was inevitable after the prolonged period of dry storage, it was thought that further drying and handling of the root surface was unlikely to worsen the prognosis.^{1,10}

Systemic antibiotics are often recommended after replantation, but their effectiveness in preventing root resorption is questionable.⁹ To date, the value of antibiotic therapy in replantation has been demonstrated only in the experimental setting.^{11,12} Andreasen and others,⁵ in their prospective study, showed that systemic antibiotics had no effect on periodontal healing clinically.

In cases of avulsed teeth with avital periodontal ligament, treatment with various agents such as tetracycline before replantation have been suggested in the hope of slowing down the resorption process.¹³ Andreasen and Andreasen¹ recommended that, after planing of the root to remove necrotic periodontal tissue, such teeth be soaked in 2.4% acidulated sodium fluoride solution (pH 5.5) for 20 minutes before extraoral root filling and replantation. However, because fluoride solution was not available in the clinic where this patient received emergency treatment, the avulsed incisor was replanted without any chemical treatment of the root surface.

Recently, Iqbal and Bamaas¹⁴ showed that extracted dogs' teeth air-dried for periods up to 60 minutes benefited from surface treatment with an enamel matrix derivative gel (Emdogain; Biora AB, Malmo, Sweden) before replantation. Periodontal healing was greater for the treated teeth than for control teeth, and there was less replacement resorption. It has been suggested that Emdogain has the potential to promote regeneration of periodontal ligament from the socket-side periodontal cell populations, and therefore may be useful in enhancing periodontal healing in teeth for which extra-alveolar storage has been extended.¹⁵ Filippi and others¹⁶ further applied the technique to treat replanted teeth at an early stage of replacement resorption.

However, the use of Emdogain in replantation is still experimental, and more data to support its clinical effectiveness are required.

The long-term prognosis for the replanted incisor in the case presented here is not good. Teeth replanted after 60 minutes of dry storage become ankylosed and are resorbed within 7 years in young patients, whereas teeth replanted under similar conditions in patients older than 16 may remain functional for considerably longer periods.¹⁷ Ebeleseder and others⁷ also found that replacement resorption of replanted mature teeth was more extensive and the overall prognosis worse for children and adolescents than for adults. It has been suggested that the more rapid resorption of teeth in children is related to the higher rate of bone remodelling in children than in adults.⁹ Ankylosis of the incisors in young patients also results in infraocclusion as the patients grow.⁷ Severe infraocclusion causes esthetic problems and may lead to tilting of the adjacent teeth if left untreated.

If the avulsed incisor had not been replanted in the present case, other treatment options might have included prosthetic replacement of the missing incisor, space closure with orthodontic treatment or autotransplantation of the premolar together with orthodontic treatment of the malocclusion.¹⁸ However, definitive treatment planning and orthodontic consultation with a specialist are seldom possible at the time of emergency treatment. Replantation can restore the patient's esthetic appearance and occlusal function shortly after the injury, and the replanted incisor can remain functional for some years. Nevertheless, replantation is usually not recommended if the avulsed tooth has a very immature root and has been air-dried for a prolonged period or if the patient's medical condition contraindicates replantation.¹⁰

In conclusion, in cases of avulsed permanent teeth with prolonged non-physiological storage, replantation should be performed if the patient and his or her parents are aware of the outcomes and request such treatment, although the risk of progressive replacement resorption and subsequent tooth loss is high. ♦

Acknowledgment: The authors thank Dr. Chun-kei Lee for his assistance in the preparation of the illustrations for this case report.

Dr. Cho is senior dental officer, Tuen Mun School Dental Clinic, Department of Health, Hong Kong.

Dr. Cheng is head, maxillofacial prosthetics, University Health Network-Princess Margaret Hospital, and an assistant professor, University of Toronto, Ontario.

Correspondence to: Dr. Shiu-yin Cho, Tuen Mun School Dental Clinic, 16 Tsun Wen Road, Tuen Mun, Hong Kong. E-mail: ronnycho@hotmail.com.

The authors have no declared financial interests in any company manufacturing the types of products mentioned in this article.

References

1. Andreasen JO, Andreasen FM. Avulsions. In: Andreasen JO, Andreasen FM, editors. Textbook and colour atlas of traumatic injuries to the teeth. Copenhagen: Munksgaard; 1994. p. 383-425.
2. Andreasen JO, Borum MK, Jacobsen HL, Andreasen FM. Replantation of 400 avulsed permanent incisors. 1. Diagnosis of healing complications. *Endod Dent Traumatol* 1995; 11(2):51-8.
3. Andreasen JO, Borum MK, Jacobsen HL, Andreasen FM. Replantation of 400 avulsed permanent incisors. 2. Factors related to pulpal healing. *Endod Dent Traumatol* 1995; 11(2):59-68.
4. Andreasen JO, Borum MK, Andreasen FM. Replantation of 400 avulsed permanent incisors. 3. Factors related to root growth. *Endod Dent Traumatol* 1995; 11(2):69-75.
5. Andreasen JO, Borum MK, Jacobsen HL, Andreasen FM. Replantation of 400 avulsed permanent incisors. 4. Factors related to periodontal ligament healing. *Endod Dent Traumatol* 1995; 11(2):76-89.
6. Kinirons MJ, Gregg TA, Welbury RR, Cole BO. Variations in the presenting and treatment features in reimplanted permanent incisors in children and their effect on the prevalence of root resorption. *Br Dent J* 2000; 189(5):263-6.
7. Ebeleseder KA, Friehs S, Ruda C, Pertl C, Glockner K, Hulla H. A study of replanted permanent teeth in different age groups. *Endod Dent Traumatol* 1998; 14(6):274-8.
8. Duggal MS, Toumba KJ, Russell JL, Paterson SA. Replantation of avulsed permanent teeth with avital periodontal ligaments: case report. *Endod Dent Traumatol* 1994; 10(6):282-5.
9. Barrett EJ, Kenny DJ. Avulsed permanent teeth: a review of the literature and treatment guidelines. *Endod Dent Traumatol* 1997; 13(4):153-63.
10. Gregg TA, Boyd DH. Treatment of avulsed permanent teeth in children. UK National Guidelines in Paediatric Dentistry. Royal College of Dental Surgeons, Faculty of Dentistry. *Int J Paediatr Dent* 1998; 8(1):75-81.
11. Hammarstorm L, Blomlof L, Feiglin B, Andersson L, Lindskog S. Replantation of teeth and antibiotic treatment. *Endod Dent Traumatol* 1986; 2(2):51-7.
12. Sae-Lim V, Wang CY, Choi GW, Trope M. The effect of systemic tetracycline on resorption of dried replanted dogs' teeth. *Endod Dent Traumatol* 1998; 14(3):127-32.
13. Selvig KA, Bjorvatn K, Claffey N. Effect of stannous fluoride and tetracycline on repair after delayed replantation of root-planed teeth in dogs. *Acta Odontol Scand* 1990; 48(2):107-12.
14. Iqbal MK, Bamaas N. Effect of enamel matrix derivative (EMDO-GAIN) upon periodontal healing after replantation of permanent incisors in beagle dogs. *Dent Traumatol* 2001; 17(1):36-45.
15. Kenny DJ, Barrett EJ, Johnston DH, Sigal MJ, Tenenbaum HC. Clinical management of avulsed permanent incisors using Emdogain: initial report of an investigation. *J Can Dent Assoc* 2000; 66(1):21.
16. Filippi A, Pohl Y, von Arx T. Treatment of replacement resorption with Emdogain — preliminary results after 10 months. *Dent Traumatol* 2001; 17(3):134-8.
17. Andersson L, Bodin I, Sorensen S. Progression of root resorption following replantation of human teeth after extended extraoral storage. *Endod Dent Traumatol* 1989; 5(1):38-47.
18. Stenvik A, Zachrisson BU. Orthodontic closure and transplantation in the treatment of missing anterior teeth. An overview. *Endod Dent Traumatol* 1993; 9(2):45-52.