

# Ameloblastic Fibro-odontoma: A Case Report

- Hyunho Chang, DDS, MSD, PhD •
- Michael S. Shimizu, BSc, DMD, MD, MSc •
- David S. Precious, DDS, MSc, FRCD(C) •

## A b s t r a c t

*Ameloblastic fibro-odontoma is a benign epithelial odontogenic tumour with odontogenic mesenchyme exhibiting the histologic characteristics of ameloblastic fibroma and complex odontoma. It is usually associated with developing teeth and occurs predominantly in children and adolescents. In many cases, such lesions are found on radiographic evaluation of patients in whom eruption of teeth is delayed. Ameloblastic fibro-odontoma is generally asymptomatic but may cause swelling and discomfort. This report describes an ameloblastic fibro-odontoma in the posterior mandible of a 26-year-old woman and discusses the histogenesis and clinical features of the lesion.*

**MeSH Key Words:** case report; mandibular neoplasms/pathology; odontoma/pathology

© J Can Dent Assoc 2002; 68(4):243-6  
This article has been peer reviewed.

Ameloblastic fibro-odontoma is a benign, slow-growing, expansile epithelial odontogenic tumour with odontogenic mesenchyme. It may inhibit tooth eruption or displace involved teeth, although teeth in the affected area are vital.<sup>1-3</sup> Radiography shows a well-defined, radiolucent area containing various amounts of radiopaque material of irregular size and form.<sup>1,3-5</sup> The lesions are usually diagnosed during the first and second decade of life.<sup>1,4-7</sup> It occurs with equal frequency in the maxilla and the mandible and with equal frequency in males and females.<sup>1,5-7</sup> This report describes an ameloblastic fibro-odontoma in a 26-year-old woman.

### Case Report

A 26-year-old woman was referred to the Department of Oral and Maxillofacial Surgery at the Queen Elizabeth II Health Sciences Centre in Halifax, Nova Scotia, by her family dentist for evaluation of an asymptomatic left mandibular lesion that had been discovered on routine radiography.

The medical, social and family histories were unremarkable, as were the results of a review of systems and a physical examination. Panoramic radiography showed an expansile, radiolucent lesion around an impacted lower left third molar. The lesion contained scattered foci of calcified material coronal to the impacted tooth. The root of the impacted third molar was 75% developed, and the lesion had displaced the tooth inferiorly. The lesion was well circum-

scribed except along the posterior aspect, where the margin was irregular and ill defined (**Fig. 1**).

The differential diagnosis included ameloblastic fibro-odontoma, immature complex odontoma, calcifying epithelial odontogenic tumour and calcifying odontogenic cyst. Excisional biopsy was performed, and the mass, including the third molar, was submitted for histopathologic diagnosis.

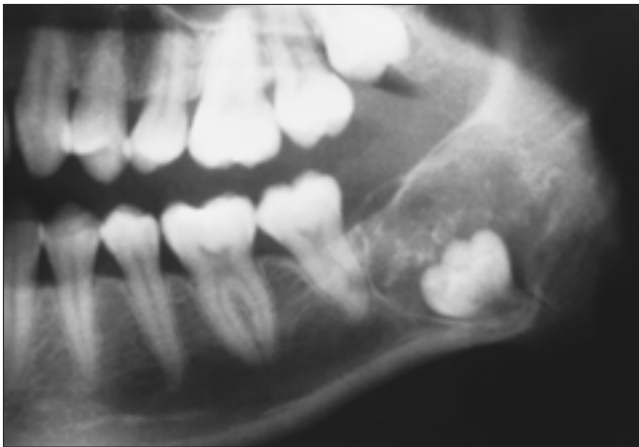
Light microscopic examination of sections stained with hematoxylin and eosin revealed characteristics of both ameloblastic fibroma and odontoma. The connective tissue was moderately cellular with spindle-shaped fibroblasts, and there were epithelial islands within the fibroblastic matrix (**Fig. 2**). High-power microscopy revealed epithelial cells producing enamel matrix and dentin. No evidence of malignancy, such as nuclear pleomorphism, was found (**Fig. 3**), and the tumour was diagnosed as ameloblastic fibro-odontoma.

The patient was followed postoperatively for 12 months, but there was no sign of recurrence. Soft-tissue healing was uneventful, and postoperative panoramic radiography demonstrated completion of bone healing.

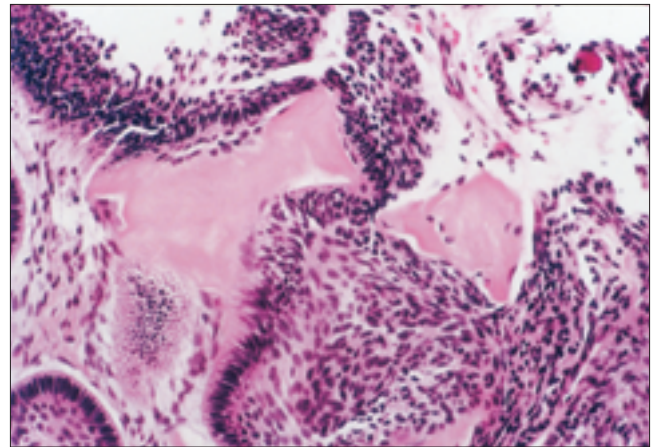
### Discussion

#### *Classification, Histogenesis and Histological Features*

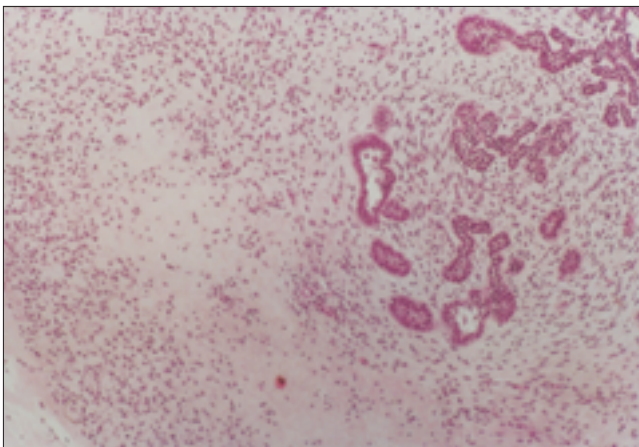
Ameloblastic fibro-odontoma has traditionally been classified as a benign mixed odontogenic tumour. The term "epithelial odontogenic tumour with odontogenic



**Figure 1:** Panoramic radiograph showing a mixed radiolucent-radiopaque lesion in the left angle of the mandible.



**Figure 2:** High-power microscopic view showing epithelial cells producing enamel matrix and dentin. (Hematoxylin and eosin, original magnification  $\times 250$ .)



**Figure 3:** Microscopic section showing epithelial islands surrounded by fibroblast connective tissue. (Hematoxylin and eosin, original magnification  $\times 65$ .)

mesenchyme” is becoming more widely accepted these days and avoids potential controversy over the nature of the neoplasia. The term “ameloblastic fibro-odontoma”<sup>7</sup> represents a histologic combination of ameloblastic fibroma and complex odontoma. This lesion exhibits the same benign biologic behaviour as ameloblastic fibroma. In contrast, the term “ameloblastic odontoma”<sup>7</sup> refers to tumors representing a histologic combination of ameloblastoma and complex odontoma, which behave in the invasive manner of classic ameloblastoma. The term “ameloblastic fibro-odontoma” appears in the World Health Organization (WHO) classification of odontogenic tumours, whereas ameloblastic odontoma is called odonto-ameloblastoma in the WHO classification.<sup>8,9</sup>

Controversy exists regarding the histogenesis of the mixed odontogenic tumors. Cahn and Blum<sup>10</sup> postulated that ameloblastic fibroma, the histologically least differenti-

ated tumour, develops first into a moderately differentiated form, ameloblastic fibro-odontoma, and eventually into complex odontoma. However, the concept that these lesions represent a continuum of differentiation is not widely accepted, and others feel that they are separate pathologic entities.<sup>6,8,11</sup> Most now agree that ameloblastic fibro-odontoma exists as a distinct entity, but it can be histologically indistinguishable from immature complex odontoma. The relative arrangement of the soft tissues and the stage of development of the involved tooth are useful criteria for diagnosis.

The tumour mass is surrounded by a fibrous capsule and is composed predominantly of a fibroblastic connective tissue matrix containing strands of odontogenic epithelium and immature tooth structures, including enamel and dentin. The connective tissue is moderately cellular with spindle-shaped fibroblasts. No evidence of malignancy is found.

### **Clinical Features**

Ameloblastic fibro-odontoma is relatively rare. The prevalence among oral biopsies is about 1%,<sup>12,13</sup> and the frequency of ameloblastic fibro-odontoma among odontogenic tumours is reported as 1% to 3%.<sup>12-15</sup> Daley and others<sup>12</sup> investigated the relative incidence of odontogenic tumours in the Canadian population and found that 3.06% of all odontogenic tumors were ameloblastic fibro-odontomas.<sup>2</sup>

Ameloblastic fibro-odontoma usually occurs in people less than 20 years old, and age is thus an important characteristic in the differential diagnosis.<sup>1,3,4,6,7,16-22</sup> Hooker<sup>7</sup> reported the mean age of patients as 11.5 years (range 6 months to 39 years). Slootweg<sup>6</sup> reviewed 50 patients with this lesion, for whom the mean age was 8.1 years (range 1 to 22 years).

There is no difference in prevalence between the sexes.<sup>6,7</sup>

Ameloblastic fibro-odontoma is usually found in the molar area.<sup>6,7</sup> The distribution is roughly equal between the maxilla and mandible.<sup>6,7</sup>

The 2 most common presenting complaints are swelling and failure of tooth eruption. The lesion may displace erupted teeth, but other symptoms, such as pain and paresthesia, are uncommon. Asymptomatic cases are usually discovered incidentally on radiography. This lesion is generally considered a slow-growing central jaw tumour; however, several exceptions to this pattern have been reported.<sup>23</sup> Occasionally, the tumour exhibits marked swelling, which results in facial disfigurement.<sup>3</sup>

### Radiographic Features

Radiography usually shows a well-defined radiolucent area containing various amounts of radiopaque material of irregular size and form. The ratio of radiopaque to radiolucent areas differs from one lesion to another; sometimes the mineralized element in the tumour predominates and the lesion may resemble an odontoma.<sup>18</sup> Some of the lesions are relatively small when first detected, measuring 1 to 2 cm in diameter, whereas others may be exceedingly large, involving a considerable portion of the body of the mandible<sup>17</sup> or maxilla.<sup>3,21</sup>

### Differential Diagnosis

When ameloblastic fibro-odontoma presents with the typical age, location and radiographic pattern, the diagnosis is usually obvious. The differential diagnosis should include lesions with mixed radiographic patterns, such as calcifying epithelial odontogenic tumour, calcifying odontogenic cyst, immature complex odontoma and possibly adenomatoid odontogenic tumour.

### Treatment, Recurrence and Malignant Transformation

Because ameloblastic fibro-odontoma is well encapsulated and there is little tendency to local invasion, the recommended treatment is conservative surgery with enucleation. When the lesion includes an unerupted tooth, the tooth should be removed with the mass. There is very little potential for recurrence.<sup>5,16</sup>

Malignant transformation of ameloblastic fibro-odontoma is rare, and its exact rate is not known. Howell and Burkes<sup>24</sup> reported 2 cases of ameloblastic fibro-odontoma that showed malignant transformation to ameloblastic fibrosarcoma. ♦

oral and maxillofacial sciences at Dalhousie University in Halifax, Nova Scotia. He is currently an assistant professor at Ulsan University, Asan Medical Center, in Seoul, Korea.

*Dr. Shimizu is a former clinical fellow of oral and maxillofacial surgery at the Queen Elizabeth II Health Sciences Centre and the faculty of oral and maxillofacial sciences at Dalhousie University in Halifax, Nova Scotia. He is currently a clinical assistant professor, division of oral and maxillofacial surgery and hospital dentistry, faculty of medicine and dentistry, University of Western Ontario, London, Ontario.*

*Dr. Precious is chief of oral and maxillofacial surgery at the Queen Elizabeth II Health Sciences Centre and professor and chair of oral and maxillofacial sciences at Dalhousie University in Halifax, Nova Scotia.*

*Correspondence to: Dr. David S. Precious, Oral and Maxillofacial Sciences, Dalhousie University, 5981 University Ave., Halifax, NS B3H 3J5. E-mail: d.s.precious@dal.ca.*

*The authors have no declared financial interests.*

### References

- Hutt PH. Ameloblastic fibro-odontoma: report of a case with documented four-year follow-up. *J Oral Maxillofac Surg* 1982; 40(1):45-8.
- Philipsen HP, Thosaporn W, Reichart PA, Grundt G. Odontogenic lesions in opercular of permanent molars delayed in eruption. *J Oral Pathol Med* 1992; 21(1):38-41.
- Miller AS, Lopez CF, Pullon PA, Elzay RP. Ameloblastic fibro-odontoma: Report of seven cases. *Oral Surg Oral Med Oral Pathol* 1976; 41(3):354-65.
- Bernhoft CH, Bang G, Gilhuss-Moe O. Ameloblastic fibroodontoma. *Int J Oral Surg* 1979; 8(3):241-4.
- Shafer WG, Hine MK, Levy BM. A textbook of oral pathology. 4th ed. Philadelphia, PA: W.B. Saunders Co.; 1983. p. 304-13.
- Slootweg PJ. An analysis of the interrelationship of the mixed odontogenic tumors — ameloblastic fibroma, ameloblastic fibro-odontoma, and the odontoma. *Oral Surg Oral Med Oral Pathol* 1981; 51(3):266-76.
- Hooker SP. Ameloblastic odontoma: An analysis of twenty-six cases. *Oral Surg* 1967; 24:375-6.
- Gardner DG. The mixed odontogenic tumors. *Oral Surg Oral Med Oral Pathol* 1984; 58(2):166-8.
- Pindborg JJ, Kramer IR, Torloni H. Histological typing of odontogenic tumors, jaw cysts, and allied lesions, International Histological Classification of tumors, No. 5, Geneva, 1967, World Health Organization.
- Cahn LR, Blum T. Ameloblastic odontoma: case report critically analysed. *J Oral Surg* 1952; 10:169-70.
- Eversole RE, Tomich CE, Cherrick HM. Histogenesis of odontogenic tumor. *Oral Surg Oral Med Oral Pathol* 1971; 32(4):569-81.
- Daley DT, Wysocki GP, Pringle GA. Relative incidence of odontogenic tumors and oral and jaw cysts in a Canadian population. *Oral Surg Oral Med Oral Pathol* 1994; 77(3):276-80.
- Regezi JA, Kerr DA, Courtney RM. Odontogenic tumors: analysis of 706 cases. *J Oral Surg* 1978; 36(10):771-8.
- Gunhan O, Erseven G, Ruacan S, Celasun B, Aydintug Y, Ergun E, and others. Odontogenic tumors: a series of 409 cases. *Aust Dent J* 1990; 35(6):518-22.
- Wu PC, Chan KW. A survey of tumors of the jaw bones in Hong Kong Chinese: 1963-1982. *Br J Oral Maxillofac Surg* 1985; 23(2):92-102.
- Furst I, Pharoah M, Phillips J. Recurrence of an ameloblastic fibro-odontoma in a 9-year-old boy. *J Oral Maxillofac Surg* 1999; 57(5):620-3.
- Savitha K, Cariappa KM. An effective extraoral approach to the mandible. A technical note. *Int J Oral Maxillofac Surg* 1998; 27(1):61-2.
- Hawkins PL, Sadeghi EM. Ameloblastic fibro-odontoma: report of case. *J Oral Maxillofac Surg* 1986; 44(12):1014-9.
- Sekine J, Kitamura A, Ueno K, Sano K, Inokuchi T, Takahashi H, and other. Cell kinetics in mandibular ameloblastic fibro-odontoma evaluated by bromodeoxyuridine and proliferating cell nuclear antigen immunohistochemistry: case report. *Br J Oral Maxillofac Surg* 1996; 34:450-3.

*Acknowledgment: The authors thank Dr. Bruce A. Wright for his help in histopathologic diagnosis and for his comments on the microscopic findings in our case.*

*Dr. Chang is a former clinical fellow of oral and maxillofacial surgery at the Queen Elizabeth II Health Sciences Centre and the faculty of*

20. Okura M, Nakahara H, Matsuya T. Treatment of ameloblastic fibro-odontoma without removal of associated impacted permanent teeth: report of cases. *J Oral Maxillofac Surg* 1992; 50(10):1094-7.
21. Piette EM, Tideman H, Wu PC. Massive maxillary ameloblastic fibro-odontoma: case report with surgical management. *J Oral Maxillofac Surg* 1990; 48(5):526-30.
22. Anneroth G, Modeer T, Twetman S. Ameloblastic fibro-odontoma in the maxillae. A case report. *Int J Oral Surg* 1982; 11(2):130-4.
23. Baker WR, Swift JQ. Ameloblastic fibro-odontoma of anterior maxilla. Report of a case. *Oral Surg Oral Med Oral Pathol* 1993; 76(3):294-7.
24. Howell RM, Burkes EJ Jr. Malignant transformation of ameloblastic fibro-odontoma to ameloblastic fibrosarcoma. *Oral Surg Oral Med Oral Pathol* 1977; 43(3):391-401.