

Implant Prosthodontic Management of Posterior Partial Edentulism: Long-Term Follow-Up of a Prospective Study

• Nikolai Attard, BChD, MSc •
• George A. Zarb, BChD, DDS, MS, MS, FRCD(C) •

A b s t r a c t

Objective: This paper reports on the long-term outcome of implant-supported posterior-zone prostheses in the first 35 consecutive, partially edentulous patients treated in the Implant Prosthodontic Unit (IPU) at the University of Toronto, Toronto, Ontario.

Methods: A total of 106 Brånemark dental implants were placed in 46 posterior edentulous spans in 35 patients for the management of multiple missing teeth; the patients were followed prospectively. Treatment planning principles involved a minimum of 2 or 3 implants at each edentulous site and scrupulous occlusal prosthodontic designs.

Results: The overall survival of posterior implants was 94%. No factors in the patients' history adversely affected implant survival.

Conclusions: This clinical update suggests that the use of Brånemark implants in the rehabilitation of patients who are partially edentulous in the posterior zone is highly effective and that survival of the implants is excellent.

MeSH Key Words: dental implants; denture, partial, fixed; jaw, edentulous, partially/surgery

© J Can Dent Assoc 2002; 68(2):118-24
This article has been peer reviewed.

Traditional prosthodontic management of partially edentulous patients has expanded with the introduction of osseointegrated dental implants. Previous Swedish results concerning the management of fully edentulous patients^{1,2} have been confirmed and expanded upon by other researchers,³⁻⁵ and more recent work has led to a lateral shift toward trials to determine the efficacy of implants in partially edentulous patients. The thrust of these initiatives has yielded several technical developments, including new abutment designs to meet the increased esthetic demands encountered in anterior partial edentulism and to address problems associated with reduced bone height in posterior partial edentulism. The premise that fewer than 5 or 6 implants can support a smaller bridge span than the one used to replace a full edentulous arch has been well demonstrated, albeit over the short term only.⁶⁻¹⁰ Recent research in the Implant Prosthodontic Unit (IPU) at the University of Toronto, Toronto, Ontario, has focused on both the effectiveness of

such treatment and the impact of selected medical conditions on the outcome of implant treatment,¹⁰⁻¹⁵ to help ensure informed decision-making by professionals and patients alike.

The aim of this survey is to report the long-term (10- to 15-year) outcome of implant-supported posterior-zone prostheses in the first 35 consecutive, partially edentulous patients treated in the IPU.

Materials and Methods

The charts of the first 35 consecutive patients with partial edentulism in the posterior zone treated in the IPU, who received a total of 46 implant-supported prostheses, were reviewed. The patients received Brånemark dental implants (Nobel Biocare AB, Gothenburg, Sweden), and all of them are included in an ongoing prospective study of partially edentulous patients that was initiated in 1983. After implant placement, each patient's information was stored in a central database, which was updated regularly. Inclusion criteria included a history of maladaptive

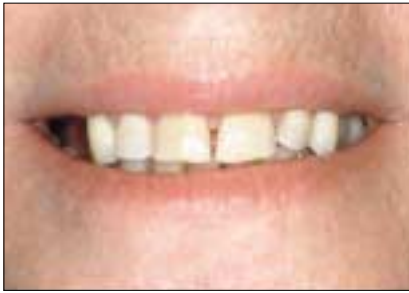

Figure 1a: Patient's smile reveals missing teeth in quadrant 1.

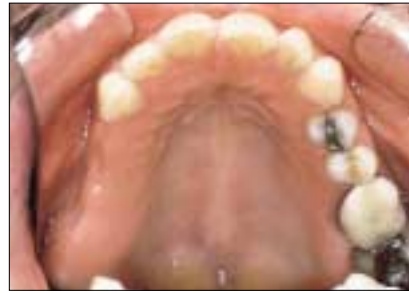

Figure 1b: The partially edentulous span in the right maxilla – occlusal view.

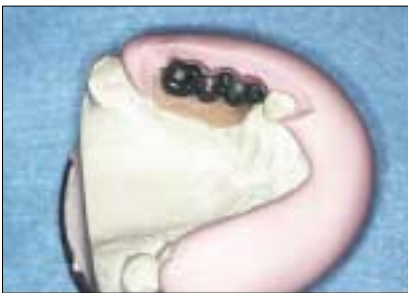

Figure 1c: After a try-in with prosthetic teeth, an index is made and then used to guide the technician's wax-up of a cast frame.

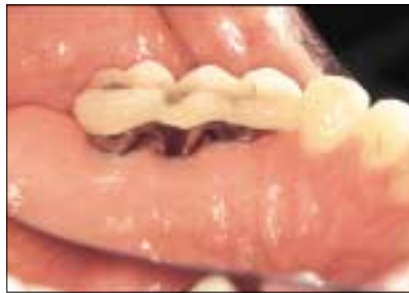

Figure 1d: A metal and ceramic fixed partial denture was selected because of restricted interarch space.

prosthetic experience or desire to avoid conventional removable prostheses.⁸ Patients were excluded if they had a brittle medical condition or a condition that precluded minor oral surgery, if their expectations of outcome were unrealistic, if they had a serious psychiatric disorder, if they had a history of substance abuse or if the quantity of the remaining bone was insufficient to accommodate an implant measuring 10 mm long and 3.75 mm in diameter.⁸ The problem of insufficient bone occurred infrequently, in patients with advanced resorption of the residual ridge and unfavourable proximity of pneumatized contents of the sinus or inferior alveolar canal. The implant dimensions mentioned were those of implants available at the beginning of the study. Subsequent availability of implants 7 mm long enabled their use as well. Treatment planning principles, which evolved on the basis of experience and published outcomes, led to the dual objectives of a

minimum of 2 or 3 implants at each edentulous site and scrupulous occlusal prosthodontic designs, to optimize the distribution of anticipated stress.

A variety of treatment options are available for implant-supported prostheses. Figures 1a to 1d demonstrate a routine fixed partial prosthesis supported by an implant, which is an effective alternative to a removable partial denture. Figures 2a to 2c illustrate a far more challenging clinical situation, the management of which demands reconciliation of traditional determinants of appropriate fixed prosthodontic designs, such as interarch space, occlusal considerations, size of the edentulous occlusal span, quality and quantity of the bone available for support, and esthetic and oral hygiene considerations.

For this study, the patients' edentulism fell into Kennedy Class I, II or III, wherein 2 or more posterior teeth were missing in an edentulous span. The design of the fixed prostheses required

that occlusal loading be shared between the implants and the natural teeth or, in certain Class I and Class II situations, that the implants bear exclusively the occlusal loading. The distribution of the partially edentulous sites and the opposing dentition is summarized in Table 1.

Patient management followed a set protocol. Each patient was first screened by a prosthodontist. The medical history was reviewed, and the presenting prosthodontic complaint was investigated clinically and radiographically. Specifically, in partially edentulous patients, a panoramic view taken as a scout film was supplemented with periapical, occlusal and tomographic radiographs to better determine the quantity and quality of bone available for implant placement. The patient was then presented with options, and his or her informed decision was obtained. If the implant option was chosen, another appointment (with an oral surgeon) was made. At the second consulta-

Table 1 Distribution of the 46 partially edentulous sites and opposing dentition in 35 patients treated in the Implant Prosthodontic Unit, University of Toronto

Kennedy Class of treated arches	No. of partially edentulous sites	Opposing arch		
		Natural dentition	Removable prosthesis	Implant-supported prosthesis
Class I	16	10	6	
Class II	19	13	4	2
Class III	11	9	2	

Table 2 Demographic characteristics of 35 partially edentulous patients treated in the Implant Prosthodontic Unit, University of Toronto

	Men	Women
No. of patients	11	24
Mean at stage I surgery	47.1	45.2
Range	30–64	20–65
Maxilla	3	13
Mandible	8	11

Table 3 Medical characteristics of 35 partially edentulous patients treated in the Implant Prosthodontic Unit, University of Toronto

Variable	No. (and %) of patients ^a
Medical status	
Healthy	16 (46)
Medical condition present	19 (54)
Medication use	
No medications	17 (49)
Medications used	18 (51)
Smoking status	
Active smokers	7 (20)
Nonsmokers	16 (46)
Former smokers	9 (26)
Missing data	3 (9)
Site for fixed prostheses (<i>n</i> = 46)	
Maxilla	17 (37)
Mandible	29 (63)

^aExcept where indicated otherwise.

tion, the patient was again presented with all the treatment options, and the nature of the surgical intervention was discussed, including possible risks and complications that might arise.

All patients were treated surgically by the Brånemark method¹⁶ by graduate residents and specialist staff. The protocol included an intermediate healing phase, the duration of which varied with implant location. For the posterior zone, the healing phase was typically 6 months. The number of Brånemark implants placed depended on the morphological features of the selected site, the proximity of anatomical structures and the expected occlusal forces.

At stage II surgery, the implant was uncovered and a transepithelial abutment attached. Graduate residents under the supervision of specialist staff then completed the prosthodontic treatment. The success or failure of osseointegration was determined at stage II surgery. After completion of the prosthodontic phase, annual follow-up visits were scheduled, although a number of patients did not regularly attend their recall appointments. Recall visits consisted of an update of the medical history, a clinical

examination, removal of the prosthesis where possible (for examination) and standardized periapical imaging. Individual implants were examined for signs of pain and mobility, and the health of the peri-implant tissues was also assessed. Osseointegration was monitored clinically and radiographically during these visits. The criteria used for determining implant success were those first proposed in 1986¹⁷ and subsequently revised at the Toronto consensus conference in 1998.¹⁸ These criteria define success both at the level of the individual implant and in terms of provision and maintenance of functionality, from the perspectives of both patient and dentist. All of the implant-supported prostheses were freestanding (not attached to natural teeth).

Clinical data were collected from the patients' dental charts, input in a Microsoft Excel worksheet and transferred to an SPSS statistical package (SPSS Inc., Chicago, Ill.) for analysis. Life-table analysis was performed for overall implant survival and also for factors that might have had an impact on implant survival. The analysis of survival automatically excluded implants for which data were missing (because patients did not attend during the follow-up period). Statistical significance for all tests was determined at $p < 0.05$.

Results

As of June 2000, the selected cutoff point for data entry, the 35 patients had received a total of 106 Brånemark dental implants for the management of multiple missing teeth in 46 posterior edentulous spans. All of the patients' updated charts were available for analysis. As described below, these patients originally accounted for 105 implants, but in one patient, a failed implant was replaced with 2 implants. This accounts for the discrepancy in total numbers of implants presented here and in an earlier report on this cohort.⁷

The demographic characteristics of the patients are presented in **Table 2**. The mean period of partial edentulism before stage I surgery was 12.2 years (standard deviation 8.78) with a range of 1 to 25 years. At the time of writing, the patients had been followed for 10 to 15 years.

Table 3 presents additional information about the patients. About half of the study population had a controlled medical condition. Nonsmokers constituted 46% of all patients, and the rest were active smokers or had a history of smoking. Nineteen (54%) of the patients had implants placed in the mandible. As outlined above, 105 implants were placed originally. Of these, 2 "sleeper" implants were not used in the final prosthesis designs because of their unfavourable location. Six implants had been lost by the time this report was prepared. Two were early failures diagnosed at stage II surgery, and the other 4 were late failures, diagnosed 2 to 7 years after loading. Three of these late failures were due to implant fracture rather than loss of osseointegration. The cause of the

Table 4 Impact of implant failure on prosthodontic outcomes

Type of failure	No. of implants affected	Prosthodontic outcome		
		Implant replaced	Implant not replaced	Tissue integrated, prosthesis lost
Sleeper implants*	2	0	0	4 in total (due to late failures)
Loss of implant				
Early	2	1	1	
Late	4	4	0	

*Unfavourable placement of implant precluded its use.

Table 5 Average survival time of 106 dental implants in relation to various factors in 35 patients with partial edentulism treated in the Implant Prosthodontic Unit, University of Toronto (Kaplan Meier method)

Variable	No. of implants	Survival (years)		p value	
		Mean	SE	Log-rank test	Breslow test
Sex					
Male	32	13.7	0.6	0.071	0.616
Female	74	14.7	0.2		
Smoking					
Group 1 (active and former smokers)	46	14.3	0.4	0.792	0.822
Group 2 (nonsmokers)	60	14.4	0.4		
Medical condition					
Present	61	14.5	0.3	0.667	0.662
Absent (healthy patient)	45	14.3	0.4		
Long-term use of medications					
Yes	58	14.4	0.4	0.987	0.993
No	48	14.0	0.4		
Jawbone					
Maxilla	42	14.6	0.3	0.560	0.529
Mandible	64	14.2	0.4		
Bone quality^a					
1	0	—	—	0.618	0.676
2	23	13.7	0.3		
3 ^b	54	14.3	0.4		
4	13	—	—		
Bone quantity^a					
A	11	—	—	0.619	0.676
B ^b	38	14.6	0.4		
C	37	14.3	0.4		
D	4	—	—		
Period of edentulism (years)^a					
Group 1 (lowest up to 10 years) ^b	36	14.1	0.6	0.510	0.580
Group 2 (11 years to highest)	33	14.4	0.3		
State of opposing dentition					
Natural or restored teeth	94	14.3	0.3	0.652	0.656
Removable partial denture	3	—	—		
Complete denture	9	—	—		
Implant length (mm)^a					
7.0 ^b	12	—	—	0.858	0.874
10.0	53	14.3	0.4		
13.0	22	14.1	0.7		
15.0	3	14.3	0.6		
18.0 ^b	16	—	—		

SE = standard error

^aMissing data were not included in analysis (and therefore implant numbers do not sum to 106).

^bFailure did not occur; mean survival time cannot be computed.

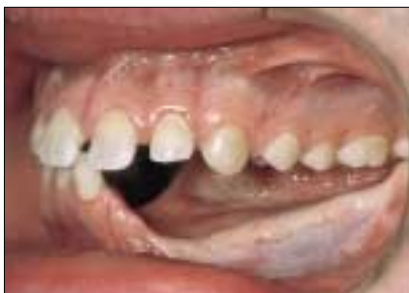

Figure 2a: The left mandibular dentition and its supporting tissues were lost after surgical resection for treatment of a tumour. The grafted site hosts 4 long implants placed in an offset manner to optimize lateral stress resistance.

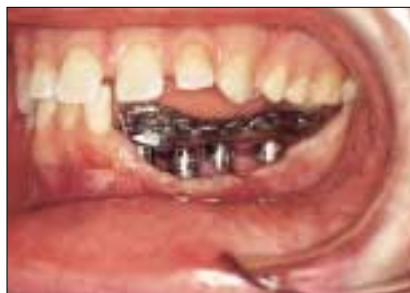

Figure 2b: Interarch space allowed for use of stock prosthetic teeth attached to a silver-palladium framework.

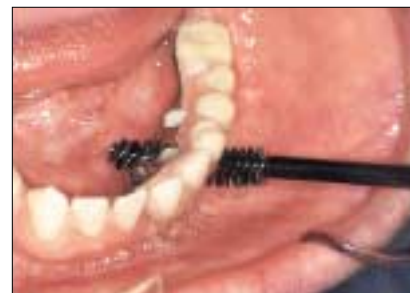

Figure 2c: The casting technique is similar to the one used when designing saddle areas for removable partial dentures. The favourable circumoral activity allows for generous space under the pontics and around the implant abutments for maintenance of hygiene.

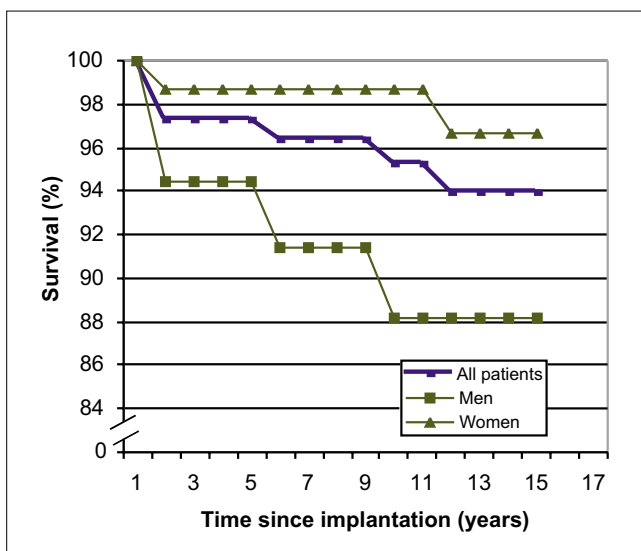


Figure 3: Overall survival of dental implants in 35 consecutive patients with posterior partial edentulism treated in the Implant Prosthodontic Unit at the University of Toronto. Time zero is the time of stage I surgery. There was no difference between men and women (Wilcoxon test, $p = 0.061$).

fractures is unknown, and they could not be correlated with bone levels around the implants. The 4 implant failures compromised prosthetic function and necessitated replacement (Table 4). In one patient, a single original implant was replaced with 2 implants after an appropriate healing phase. At the most recent clinical assessments, evaluations by both patients and dentists indicated successful prosthodontic results, in accordance with the success criteria proposed by Zarb and Albrektsson.¹⁸

The role of various patient factors on implant survival were analyzed (Table 5). None of these factors adversely affected implant survival in this patient group. In contrast, Wyatt,¹⁹ using similar criteria for a larger group of patients from the IPU database, reported a higher failure rate (25%) for 7-mm fixtures.

A graph based on a life-table analysis is presented in Fig. 3. The overall survival of implants in the posterior zones of both maxilla and mandible was 94% (92% if the 2 sleepers are regarded as failures). The difference in survival rate between men and women was not statistically significant at any point ($p = 0.061$) (Fig. 3). However, the graph suggests that the survival rate was lower for men 15 years after loading (88% in men and 97% in women).

Discussion

This study reports on the surgical and prosthodontic outcomes of Brånemark implants supporting fixed prostheses placed in the posterior zone of the first 35 partially edentulous patients treated in the IPU. This survey is part of an ongoing prospective study initiated in 1983 at the University of Toronto.

The benefits of employing the maximum number of implants possible (3 whenever feasible) plus strict adherence to Beyron's therapeutic occlusal objectives²⁰⁻²² appeared to be underscored by the outcomes reported here. The cumulative survival rate for Brånemark implants in the posterior zone was 94% after 10 years of observation, which compares favourably with the survival rate of 92.6% reported by Lekholm and others.²³ Although there was no statistical difference between men and women, the trend in the data suggested that overall survival was lower for men. Six (5.7%) of the implants failed. Two (1.9%) of these were early failures, that is, the implants had not osseointegrated. These proportions are comparable to the results published by Esposito and others,²⁴ who reported an overall failure rate of 3.8% in partial edentulism and a 2% early failure rate.

The condition of the marginal bone around the implants was not determined for this survey. Wyatt⁸ previously reported that annual loss of marginal bone among partially edentulous patients treated in the IPU was well within the suggested maximum of 0.2 mm after the first year of function. However, Wyatt,⁸ reporting on

the outcomes of implant-supported fixed partial dentures, noted that 15% of the patients in his study experienced bone loss exceeding 0.2 mm per year. This level of bone loss typically occurred in the mandible of younger male patients after one year of loading, and was more frequent when the prosthetic design included a posterior cantilevered pontic.

A number of practical considerations may have implications for the results reported here.

1. The limited sizes of implants that were available initially prevented the IPU from treating patients whose posterior edentulous sites had significant quantitative deficits (bone height < 7 mm). Consequently, the observations reported here apply exclusively to implant abutments of 10 mm or longer with occasional adjunctive support from a 7-mm implant. Therefore, our results cannot be extrapolated to sites where the deficit status could be improved by localized tissue engineering, augmentation or use of wider (if shorter) implants. All these options may prove to be of compelling significance. However, evidence for the use of such implants is lacking at this stage, and we can only report that support from multiple implants, mainly 10 mm or more in length and 3.75 mm in diameter, has proven efficacious and effective.
2. Our success with freestanding implant-supported prostheses should not be construed as negating the impressive results reported by researchers in Umea, Sweden. Gunne and others²⁵ have provided data to support the use of short-span fixed prostheses supported by one implant and one tooth. Their results are particularly significant in the context of a shortened dental arch²⁶ approach to posterior partial edentulism.
3. Although comprehensive quantitative studies reflecting patient satisfaction with implant therapy are unavailable for this patient group, traditional and time-proven indications of patient satisfaction were acquired through simple questioning. All of the patients were pleased with the results of their treatment and were free of the morbidity that is sometimes associated with surgical intervention for implant treatment.
4. The restorative materials used here could not be correlated with previously recorded outcomes. Consequently, as with most decision-making in prosthodontics, the choice of materials was made on the basis of interarch space available, other technical and esthetic dictates and, occasionally, patient input. These subjective yet prudent judgements appear to have served us well in the choice of prosthodontic materials for these patients.

Conclusions

This clinical update suggests that the use of Brånemark implants in the rehabilitation of patients who are partially edentulous in the posterior zone is highly effective and is associated with excellent survival rates. However, it seems

prudent to underscore the fact that these outcomes were obtained in a university clinic under the supervision of specialists, with stringent treatment planning and clinical examination, as part of an evidence-based approach to clinical decision-making in prosthodontics. ♦

Dr. Attard is a graduate resident in the department of prosthodontics, faculty of dentistry, University of Toronto, Toronto, Ontario.

Dr. Zarb is a professor and is head, prosthodontics, department of clinical sciences, faculty of dentistry, University of Toronto.

Correspondence to: Dr. George A. Zarb, Department of Clinical Sciences, 124 Edward St., Toronto, ON M5G 1G6. E-mail: g.zarb@utoronto.ca.

The authors have no declared financial interest in any company manufacturing the types of products mentioned in this article.

References

1. Brånemark PI, Hansson BO, Adell R, Breine U, Lindstrom J, Hallen O, and other. Osseointegrated implants in the treatment of the edentulous jaw: experience from a ten-year period. *Scand J Plast Reconstr Surg* 1977; 11(Suppl 16):1-132.
2. Adell R, Lekholm U, Rockler B, Brånemark PI. A 15-year study of osseointegrated implants in the treatment of the edentulous jaws. *Int J Oral Surg* 1981; 10(6):387-416.
3. Lindquist LW, Carlsson GE, Jemt T. A prospective 15-year follow-up study of mandibular fixed prostheses supported by osseointegrated implants. Clinical results and marginal bone loss. *Clin Oral Implants Res* 1996; 7(4):329-36.
4. Zarb GA, Schmitt A. The edentulous predicament. I: A prospective study of the effectiveness of implant-supported fixed prostheses. *J Am Dent Assoc* 1996; 127(1):59-65.
5. Henry PJ, Bower RC, Wall CD. Rehabilitation of the edentulous mandible with osseointegrated dental implants: 10 year follow-up. *Aust Dent J* 1995; 40(1):1-9.
6. Zarb GA, Schmitt A. The longitudinal clinical effectiveness of osseointegrated dental implants in anterior partially edentulous patients. *Int J Prosthodont* 1993; 6(2):180-8.
7. Zarb GA, Schmitt A. The longitudinal clinical effectiveness of osseointegrated dental implants in posterior partially edentulous patients. *Int J Prosthodont* 1993; 6(2):189-96.
8. Wyatt CC. Treatment Outcomes of patients with implant supported fixed partial prostheses [Master of Science Thesis]. Toronto (ON): University of Toronto; 1996.
9. Lekholm U, van Steenberghe D, Herman I, Bolender C, Folmer T, Gunne J, and others. Osseointegrated implants in the treatment of posterior partially edentulous jaws: A 5-year multi-center study. *Int J Oral Maxillofac Implants* 1994; 9:627-35.
10. Dao TT, Anderson JD, Zarb GA. Is osteoporosis a risk factor for osseointegration of dental implants? *Int J Oral Maxillofac Implants* 1993; 8(2):137-44.
11. Accursi GE. Treatment outcomes with osseointegrated Brånemark implants in diabetic patients: A retrospective study [Master of Science Thesis]. Toronto (ON): University of Toronto; 2000.
12. Attard NJ. Implant prosthodontic management of medically controlled hypothyroid patients [Master of Science Thesis]. Toronto (ON): University of Toronto; 2001.
13. Khadivi V, Anderson J, Zarb GA. Cardiovascular disease and treatment outcomes with osseointegration surgery. *J Prosthet Dent* 1999; 81(5):533-6.
14. Bryant SR. The effects of age, jaw site, and bone condition on oral implant outcomes. *Int J Prosthodont* 1998; 11(5):470-90.
15. Habsha E. Survival of osseointegrated dental implants in smokers and non-smokers [Master of Science Thesis]. Toronto (ON): University of Toronto; 2000.

16. Adell R, Lekholm U, Brånemark PI. Surgical procedures. Brånemark PI, Zarb GA, Albrektsson T, editors. *Tissue-integrated prostheses: osseointegration in clinical dentistry*. Chicago: Quintessence; 1985. p. 211-40.
17. Albrektsson T, Zarb G, Worthington P, Eriksson AR. The long-term efficacy of currently used dental implants: a review and proposed criteria of success. *Int J Oral Maxillofac Implants* 1986; 1(1):11-25.
18. Zarb G, Albrektsson T. Consensus report: towards optimized treatment outcomes for dental implants. *Int J Prosthodont* 1998; 11(5):389.
19. Wyatt CL, Zarb GA. Treatment outcomes with implant-supported fixed partial prosthesis. *Int J Oral and Maxillofac Implants* 1998; 13(2):204-11.
20. Beyron H. Characteristics of functionally optimal occlusion and principles of occlusal rehabilitation. *J Am Dent Assoc* 1954; 48:648-56.
21. Beyron H. Optimal occlusion. *Dent Clin North Am* 1969; 13(3): 537-54.
22. Beyron H. Occlusion: point of significance in planning restorative procedures. *J Prosthet Dent* 1973; 30(4):641-52.
23. Lekholm U, Gunne J, Henry P, Higuchi K, Linden U, Bergstrom C, and other. Survival of the Brånemark implant in partially edentulous jaws: a 10-year prospective multicenter study. *Int J Oral Maxillofac Implants* 1999; 14(5):639-45.
24. Esposito M, Hirsch JM, Lekholm U, Thomsen P. Biological factors contributing to failures of osseointegrated oral implants. (I). Success criteria and epidemiology. *Eur J Oral Sci* 1998; 106(1):527-51.
25. Gunne J, Astrand P, Lindh T, Borg K, Olsson M. Tooth-implant and implant supported fixed partial dentures: a 10-year report. *Int J Prosthodont* 1999; 12(3):216-21.
26. Kayser AF. Limited treatment goals — shortened dental arches. *Periodontol 2000* 1994 Feb; 4:7-14.

C D A R E S O U R C E
C E N T R E

CDA members can borrow a copy of *Implant therapy: clinical approaches and evidence of success*, by Myron Nevins and James T. Mellonig, Quintessence, 1998. Shipping charges and taxes apply. Contact the Resource Centre at tel.: 1-800-267-6354 or (613) 523-1770, ext. 2223; fax: (613) 523-6574; e-mail: info@cda-adc.ca.
