

A 5-Year Prospective Study of Implant-Supported Single-Tooth Replacements

- Leslie Laing Gibbard, BSc, BEd, MSc, PhD, DDS •
- George Zarb, BChD, DDS, MS, MS, FRCD(C) •

A b s t r a c t

Objective: Because osseointegration has been successful in the management of completely edentulous patients, it is tempting to extrapolate these results and infer the success of single-tooth replacement. Yet there are major clinical differences between edentulous and partially edentulous patients. This prospective study is a follow-up to one started at the University of Toronto in 1986. The purpose of this study was to continue longitudinal assessment of implant-supported single-tooth replacements.

Methods: The original study comprised 42 consecutively treated patients with a total of 49 implants. The patient group consisted of all University of Toronto patients treated with single Brånemark implants whose treatment had been completed more than 5 years previously (i.e., before 1994). No exclusion criteria applied. One implant was not osseointegrated at the time of stage 2 surgery, and 6 patients with reportedly successful osseointegrated implants were not available for recall. For the preparation of this report, 30 of the remaining 42 implants were assessed during recall examinations. Assessment of success was based on published criteria. In addition, soft-tissue appearance, implant immobility, occlusal contacts in centric occlusion and excursions, proximal contacts, tightness of crown and abutment screws, and patients' responses on satisfaction questionnaires were evaluated.

Results: The criteria defining success of treatment in implant prosthodontics were met by all 30 of the single-tooth implants, which had been in place for 5 or more years. Each implant was immobile, and each had a mean vertical bone reduction of less than 0.2 mm annually.

Conclusion: Stable long-term results can be achieved with single Brånemark implant-supported crowns.

MeSH Key Words: dental implants; dental prosthesis, implant-supported; osseointegration

© J Can Dent Assoc 2002; 68(2):110-6
This article has been peer reviewed.

The success of osseointegration^{1,2} in the management of completely edentulous patients is well documented in both in vitro and in vivo studies.³⁻⁹ Although it is tempting to extrapolate from these results to infer success of single-tooth replacement, there are major clinical differences between edentulous and partially edentulous patients, such as the presence of adjacent teeth; the more challenging esthetic demands, particularly in the anterior regions; and differences in occlusal forces and prosthetic designs. However, with broadening patient awareness of treatment alternatives, implant-supported crowns are being used increasingly in cases of single-tooth loss.

Preliminary outcomes of treatment with Brånemark single-tooth implant-supported prostheses inserted at the University of Toronto were reported in 1996.¹⁰ Those results, as well as results from a similar study,¹¹ indicated

promising performance in different jaw locations. At the time, there were no long-term studies offering specific criteria for optimal functional and esthetic results with minimal risk of morbidity.

The purpose of this study was to continue the longitudinal assessment of the same implant-supported single-tooth replacements, after service for 5 or more years. Outcomes were assessed clinically, radiographically and esthetically, the latter from the patients' perspective as well as the viewpoint of various dental personnel, including dental assistants, dental students and dentists.

Materials and Methods

Study Population

The original study was initiated in 1986 at the Implant Prosthodontic Unit (IPU) at the University of Toronto,

Table 1 Number of implants per patient

No. of implants per patient	No. (and %) of patients	
1	24	(80)
2	5	(17)
3	1	(3)
Total	30	(100)

Toronto, Ontario. The study population consisted of 42 consecutively treated patients with a total of 49 Brånemark single-tooth implants.¹⁰ Of the 42 patients, 17 (40%) were female and 25 (60%) were male; the patients ranged in age from 14.5 to 63.9 years (mean 33.5 years) at the time of implant placement. Thirty-six patients (86%) were treated with a single implant at one site, 5 patients (12%) received a single implant at each of 2 sites, and one patient (2%) received a single implant at each of 3 sites. The teeth being replaced had been missing for at least 1 year. The patient group for the current study, which started in 1999, consisted of all patients who had received a single tooth implant at the University of Toronto whose treatment had been completed over 5 years ago (before 1994). No exclusion criteria applied.

Thirty of the original 49 implants were assessed in the current study: 14 (47%) in women and 16 (53%) in men. The 24 patients ranged in age from 23 to 74 years (mean 42.7, median 40.5, standard deviation 13.9). The number of single-tooth implants per patient is listed in **Table 1**, the mean number of implants per subject being 1.2 ± 0.5 . Nineteen implants (63%) had been placed in zone 1 (anterior to the mental foramen), 18 (60% of the total) in the

maxilla and 1 (3%) in the mandible. Eleven implants (37%) had been placed in zone 2 (posterior to the mental foramen), 3 (10% of the total) in the maxilla and 8 (27%) in the mandible.

Clinical, Esthetic Radiographic Assessments

Each patient received a consent form, which included a written explanation of the nature of the assessment to be undertaken. One of the authors (L.L.G.) performed all of the clinical examinations. Soft-tissue appearance, implant mobility, occlusal contacts in centric occlusion and excursions, proximal contacts, tightness of crown and abutment screws, and patients' responses on a satisfaction questionnaire (**Table 2**) were evaluated.

In all but 2 cases, in which the crowns had been cemented, the crowns were removed, ultrasonically cleaned and re-inserted. Five standardized photographs were taken: full face, natural smile, full smile, cheek-retracted smile and occlusal view using a mirror. For this part of the study, dental assistants, dental students and dentists were asked to complete esthetic evaluation forms on the basis of the cheek-retracted smile and occlusal-view photographs.

Standardized intraoral periapical radiographs were obtained to assess for radiolucencies and changes in crestal bone level. To standardize the radiographs, a radiographic film holder was inserted into the implant and held in place by means of a guide pin while the radiograph was being taken. Each radiograph was then digitized. Measurements of bone reduction were determined by standardizing the distance between implant threads at 3 mm and by measuring crestal bone levels at the mesial and distal sides of each implant and at the adjacent surfaces of neighbouring teeth.

Table 2 Assessment of patient satisfaction

	Patient response; no. (and %) of patients				
	Extremely dissatisfied or unwilling	Somewhat dissatisfied or unwilling	Neither satisfied/willing nor dissatisfied/unwilling	Somewhat satisfied or willing	Extremely satisfied or willing
To what degree are you generally satisfied with the appearance of your implant-supported crown?				3 (10)	27 (90)
To what degree are you generally satisfied with the functioning of your implant-supported crown?				5 (17)	25 (83)
To what extent are you generally satisfied with the cleansability of your implant-supported crown?		2 (7)	1 (3)	9 (30)	18 (60)
To what extent would you be willing to undergo another implant-supported crown procedure?		2 (7)	4 (13)	8 (27)	16 (53)
To what extent would you be willing to recommend the implant-supported crown procedure to a relative or close friend?				4 (13)	26 (87)

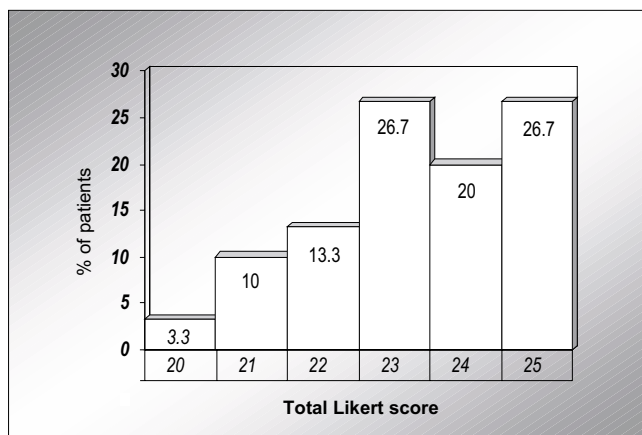


Figure 1: Distribution of total Likert scores for satisfaction among 24 patients. Total patient satisfaction scores, as determined by the 5-level Likert scale, had a potential range of 5 to 25. The mean score was 23.3 (standard deviation 1.44).

Statistical Analysis

Univariate analyses were used to describe the number of subjects, the number of implants, the number of implants per subject, the age of the subjects, the zone in which the implants had been placed, and the sex distribution. Univariate analyses were also used in the descriptions of fixture and abutment lengths; retrievability of the crown; parafunctional habits of the patient (grinding or clenching); history of occlusal splints and whether such splints were worn by the patient; contact in excursions; abutment reflections beneath the soft tissue; soft-tissue deficiencies; evidence of inflammation, fistulae, dehiscence or mobility; interproximal contact with adjacent teeth; tightness of the crown and abutment screws; and patient satisfaction as determined with a 5-level Likert scale. In addition, univariate analysis was used to describe annual mean bone reduction after a minimum of 5 years of loading on the mesial and distal sides of each implant and at adjacent surfaces of neighbouring teeth as well as overall annual bone reduction around the implant.

Bivariate analyses were carried out between the patient satisfaction scores and the various implant data. Chi-square and Fisher's exact tests were performed, with the null hypothesis that there was no association between patient dissatisfaction (dichotomous variable) and various implant parameters. Pearson's correlation coefficient was used to determine whether annual bone reduction on the mesial or distal side of the implant was significantly associated with annual bone reduction on the distal or mesial side of the adjacent tooth, respectively.

Multivariate analyses were performed with logistic regression models for predicting patient dissatisfaction as determined by the clinical, radiographic and esthetic measures on a forward stepwise basis.

Table 3 Short-term and long-term clinical success of 49 implants

Outcome	Definition	No. of implants	
		Short-term ^a	Long-term ^b
Success	Implant met success criteria ^{1, 2}	42	30
Survival	Implant not checked clinically or radiographically at last recall	6	12
Unaccounted	Patient died, dropped out or was not available at recall	0	6
Failure	Implant removed for any reason	1	1

^aAs of last recall visit in 1994.¹⁰

^bFollow-up after at least 5 years (in 1999).

Results

Treatment Outcome

Of the 42 patients with 49 implants in the original study,¹⁰ all but one, whose implant had not osseointegrated at stage 2 surgery, had been seen for regular recall visits for a minimum of 4 years after crown insertion. Six (14%) of the 42 patients, accounting for 6 (12%) of the 48 reportedly successful osseointegrated implants (5 in the maxilla and 1 in the mandible), had moved by the time of the current study and were unavailable for recall. Each had last been seen for their 4-year recall appointment in 1994. Twelve of the implants were not checked clinically or radiographically; 8 of the patients, accounting for 8 of these implants, were contacted by telephone. All reported both functional and esthetic satisfaction with their implant-supported crowns, which suggested that the implants had survived. All 30 of the examined implants met the published success criteria.^{1,2} Short-term clinical success (as of 1996) and the results of a minimum 5-year (maximum 13-year) loading period for the 49 implants are shown in **Table 3**.

Twenty (67%) of the fixtures were 13 mm in length, 5 (17%) were 10 mm, 4 (13%) were 15 mm, and 1 (3%) was 18 mm. Almost half of the abutments (14 [47%]) were 4.0 mm long, whereas the others were either 3.0 mm (7 [23%]) or 5.5 mm (9 [30%]). All but 2 of the crowns were retrievable through access openings in the restorations. Most were retained with slotted screws.

Nine (38%) of the 24 patients were aware of grinding their teeth, whereas 10 (42%) claimed that they clenched their teeth. Six patients (25%) had previously been prescribed an occlusal splint, but only 2 (8%) still used one.

Four (13%) of the 30 implants had contact in centric occlusion. Seven (23%) of the implants had contact in

Table 4 Annual bone reduction^a associated with 30 successful implants

Location	No. of implants	Mean	Annual bone reduction (mm)			
			Median	Standard deviation	Minimum	Maximum
Mesial side of implant	30	0.069	0.069	0.037	-0.028	0.140
Distal side of implant	30	0.070	0.070	0.058	-0.114	0.262
Distal side of adjacent tooth	14	0.302	0.217	0.280	0.007	1.060
Mesial side of adjacent tooth	15	0.277	0.228	0.289	0.005	1.138
Overall annual bone reduction ^b	30	0.073	0.071	0.044	-0.064	0.199

^aNegative values indicate bone gain.

^bOverall annual bone reduction is the mean of annual bone reduction at the mesial and distal sides of the same implant.

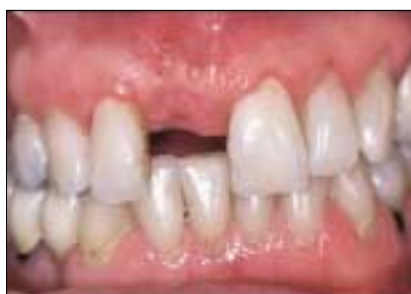

Fig. 2a: Pre-operative photograph of edentulous site 11 in a 67-year-old woman.

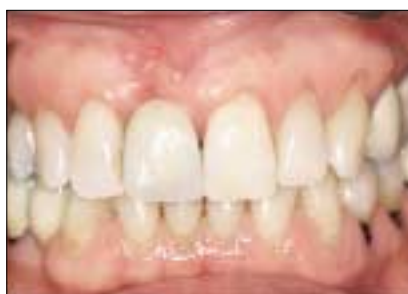

Fig. 2b: Post-operative photograph of the restored single-tooth implant at site 11.

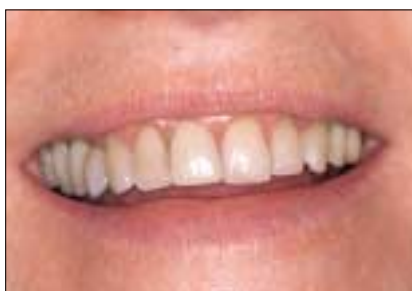

Fig. 2c: Photograph of the full smile of the patient showing the completed result of the restored implant at site 11.

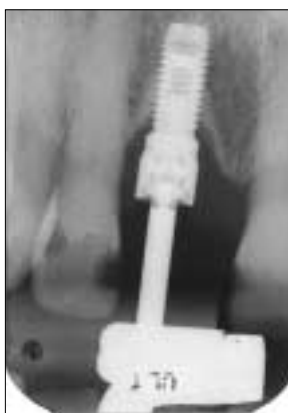

Fig. 2d: Periapical radiograph of the implant at site 11.

lateral and protrusive excursions. Abutment reflection (seen as a grey shadow) under the soft tissue was noted with 7 (23%) of the implants, whereas 8 (27%) had a soft-tissue deficiency. Gingival tissue around 3 (10%) of the implants showed signs of inflammation. None of the implants was associated with fistulae, dehiscence or mobility. Twenty-three implants (77%) had mesial interproximal contact with the adjacent tooth, and 25 (83%) exhibited distal contact. Loose gold screws were found in 4 (13%) of the crowns, but all had gone unnoticed by the patients. No looseabutment screws were observed.

Figures 2 to 4 are typical pre- and post-operative photographic and radiographic images of single-tooth implants in the anterior zone.

Self-Reported Satisfaction with Implant-Supported Prostheses

The distribution of responses from the 24 patients to questions about their satisfaction with and the esthetic characteristics of their implants are presented in Fig. 1 and Table 2. Total patient satisfaction scores, as determined by a 5-level Likert scale, had a potential range of 5 to 25. None of the implants received a total score less than 20. At least 80% of the responses were in the somewhat satisfied (or willing) or extremely satisfied (or willing) categories (see Table 2).

Radiographic Findings

All implants were free of radiographic signs of morbidity. Mean annual bone reduction was 0.069 mm at mesial sites, 0.070 mm at distal sites and 0.073 mm overall (Table 4). In situations where the implant-supported crowns had contact in centric occlusion or lateral and protrusive excursions, the mean annual bone reduction at the mesial side of both the implant and the adjacent tooth was

higher than in situations where there were no such contacts. However, the levels of bone reduction were within the defined range as successful according to the published criteria.^{1,2} Correlations between annual bone reduction on the mesial or distal side of the implant and annual bone reduction on the distal or mesial side, respectively, of the adjacent tooth were not significant (Table 5).

Esthetic Evaluation by Dental Personnel

Preliminary results of the esthetic evaluation by dental personnel revealed that all but 3 of the crowns had ideal esthetic appearance. Two of these crowns had satisfactory or reasonably good characteristics, and the characteristics of the third were considered poor. Further results from this

Table 5 Correlations between annual bone reduction on mesial or distal side of the implant with reduction on distal or mesial side, respectively, of the adjacent tooth

	Annual bone reduction on distal side of adjacent tooth	Annual bone reduction on mesial side of adjacent tooth
Annual bone reduction on mesial side of implant		
Pearson correlation	0.19	
p value (2-tailed)	0.52	
No. of implants	14	
Annual bone reduction on distal side of implant		
Pearson correlation		0.34
p value (2-tailed)		0.21
No. of implants		15

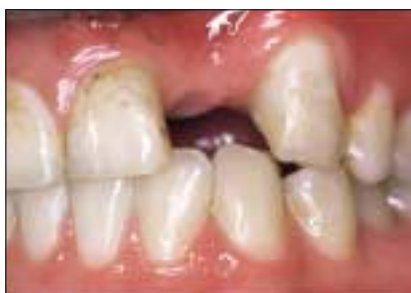

Fig. 3a: Pre-operative photograph of edentulous site 22 in a 37-year-old man.

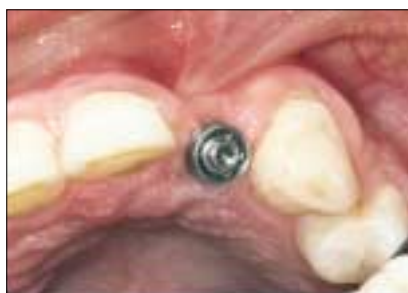

Fig. 3b: Post-operative photograph of the restored single-tooth implant at site 22.



Fig. 3c: Photograph of the full smile showing the completed result of restored implant at site 22.

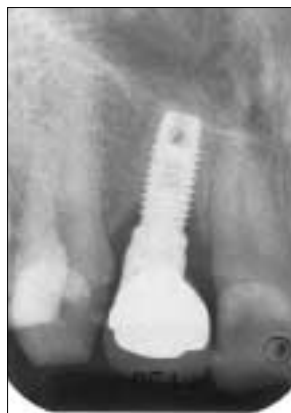

Fig. 3d: Periapical radiograph of the implant at site 22.

overload on implants is that of tactile sensitivity, which is reportedly 3 times less on implants than on teeth.¹² Although 7 implants had occlusal contacts in centric occlusion or excursions, only one patient with such contacts reported the use of an occlusal splint at night. The loading limits of a single implant in different host sites in the jawbones are not known. Long-term success for multiple splinted implants cannot be extrapolated to single implants. Hence the dentist must be particularly prudent in planning single-tooth implants in the context of anticipated differences in magnitude, frequency and duration of forces acting on the replaced single crown. The premise of treatment planning in the IPU has been to “protect” the single implant as much as possible by minimizing or even precluding occlusal contacts on the crown in both centric contact and excursive positions. In fact, the single implant is regarded more as an elegant and ecologically sound space maintainer than as a crown replacement. The comparison of full loading, partial loading and no load-

portion of the study will be submitted for publication at a later date.

Discussion

The present study indicates that predictable, long-term results can be achieved with single Brånemark implant-supported crowns.

The 30 implants examined had a mean vertical bone reduction of less than 0.2 mm per year, but the mean annual bone reduction was greater for implant-supported crowns with contacts in centric occlusion or excursions than for those for which there were no such contacts. An important consideration in the prevention of occlusal

ing for single implants at different jaw sites and over longer periods of observations clearly deserves investigation.

Annual marginal bone reduction around implants was less than 0.2 mm per year after the first year of loading, which corresponds with other published results.^{1,2} Mean annual bone reduction at mesial sites, at distal sites and overall (Table 4) was consistent with findings in other studies of single-tooth implants.¹³⁻¹⁸ Previous reports^{11,15} have confirmed that the presence of a single-tooth implant promotes crestal bone reduction at the implant-facing surfaces of adjacent teeth.

Patient satisfaction with single-implant crowns was very high in this patient group and in other studies.^{10,11,14,17,19}

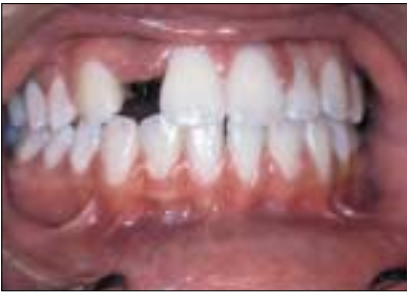

Fig. 4a: Pre-operative photograph of edentulous site 12 in a 25-year-old woman.

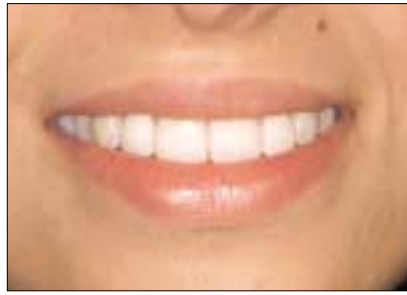

Fig. 4b: Post-operative photograph of the restored single-tooth implant at site 12.

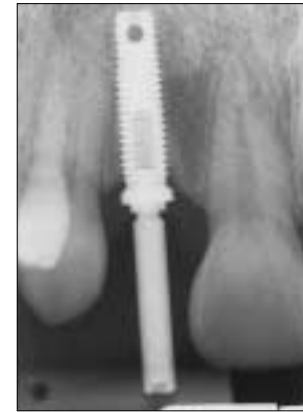

Fig. 4c: Periapical radiograph of the implant at site 12.

Dissatisfaction with the implants did not appear to be correlated with any complications that may have arisen during the loading period, such as loosening of crown or abutment screws or inflammation, although one patient reported dissatisfaction because of abutment reflection under the gingiva.¹⁷ Fistulae have been reported in association with loose abutment screws.^{10,13} However, neither fistulae formation nor loose abutment screws were observed in the current study.

At present, only preliminary data are available from the esthetic evaluation. However, indications are that the results will be similar to those previously reported,²⁰⁻²³ specifically, that patients and dentists have different criteria when judging esthetics and quality of dental care. Chang and others²³ found that no single factor used in multiple regression analysis influenced patients' satisfaction with the appearance of the crown at a statistically significant level. It appears that a patient's concept of esthetic appearance differs substantially from that of the dentist. Although both may have the same preferences for the shape of maxillary anterior teeth, for example, preferences for proportions of length and width appear to differ. Factors considered by professionals to be of significance for the esthetic result of restorative treatment may not be of decisive importance for patients. Of the data collected to date, dental students' opinions were between those of the patients and those of the dentists.

This study will be continued with expansion of the patient base, as a larger sample will afford more reliability. The analysis of esthetics will also continue.

Conclusion

In this study, the criteria for success of implant prosthodontics were met by all 30 of the single-tooth implants examined, which had been in place for 5 or more years. Each implant was immobile, and each had a mean vertical bone reduction of less than 0.2 mm annually. All but 3 of the implant-supported crowns met with patient and dentist satisfaction, exhibiting lack of pain, discomfort, altered sensation and infection. It appears that single-implant therapy to support a crown is a viable prosthodontic treatment option, at least in the short term. ♦

Acknowledgments: The authors would like to express gratitude to Snezana Djuric, Janet deWinter and the staff of the Implant Prosthodontic Unit for their ever-cheerful clinical assistance. The study was supported by a Staff Support Grant from Nobel Biocare Inc. and the University of Toronto Faculty of Dentistry.

Dr. Laing Gibbard is a prosthodontic resident at the faculty of dentistry, University of Toronto, Toronto, Ontario.

Dr. Zarb is a professor and is head of prosthodontics, department of clinical sciences, faculty of dentistry, University of Toronto.

Correspondence to: Dr. Leslie Laing Gibbard, Faculty of Dentistry, University of Toronto, 124 Edward St., Toronto, ON M5G 1G6. E-mail: leslie.lainggibbard@utoronto.ca

References

- Albrektsson T, Zarb GA. Current interpretations of the osseointegrated response: clinical significance. *Int J Prosthodont* 1993; 6(2):95-105.
- Zarb GA, Albrektsson T. Consensus report: towards optimized treatment outcomes for dental implants. *Int J Prosthodont* 1998; 11(5):389.
- Brånemark P-I, Hansson BO, Adell R, Breine U, Lindström J, Hallen O, and other. Osseointegrated implants in the treatment of the edentulous jaw. Experience from a 10-year period. *Scand J Plast Reconstr Surg* 1977; 11(suppl 16):1-132.
- Lindquist LW, Carlsson GE. Long-term effects on chewing with mandibular fixed prostheses on osseointegrated implants. *Acta Odontol Scand* 1985; 43(1):39-45.
- van Steenberghe D, Quirynen M, Calberson L, Demanet M. A prospective evaluation of the fate of 697 consecutive intraoral fixtures ad modum Brånemark in the rehabilitation of edentulism. *J Head Neck Pathol* 1987; 6:53-58.
- Albrektsson T. A multicenter report on osseointegrated oral implants. *J Prosthet Dent* 1988; 60(1):75-84.
- Adell R, Eriksson B, Lekholm U, Brånemark PI, Jemt T. Long-term follow-up study of osseointegrated implants in the treatment of totally edentulous jaws. *Int J Oral Maxillofac Implants* 1990; 5(4):347-59.
- Zarb GA, Schmitt A. Osseointegration and the edentulous predicament. The 10-year-old Toronto study. *Br Dent J* 1991; 170(12):439-44.
- Harle TJ, Anderson JD. Patient satisfaction with implant-supported prostheses. *Int J Prosthodont* 1993; 6(2):153-62.
- Avivi-Arber L, Zarb GA. Clinical effectiveness of implant-supported single-tooth replacement: the Toronto study. *Int J Oral Maxillofac Implants* 1996; 11(3):311-21.
- Henry PJ, Laney WR, Jemt T, Harris D, Krogh PH, Polizzi G, and others. Osseointegrated implants for single-tooth replacement: a prospective 5-year multicenter study. *Int J Oral Maxillofac Implants* 1996; 11(4):450-5.

12. Jacobs R, van Steenberghe D. Comparative evaluation of the oral tactile function by means of teeth or implant-supported prostheses. *Clin Oral Implants Res* 1991; 2(2):75-80.
13. Laney WR, Jemt T, Harris D, Henry PJ, Krogh PH, Polizzi G, and others. Osseointegrated implants for single-tooth replacement: progress report from a multicenter prospective study after 3 years. *Int J Oral Maxillofac Implants* 1994; 9(1):49-54.
14. Andersson B, Ödman P, Lindvall AM, Brånemark PI. Five-year prospective study of prosthodontic and surgical single-tooth implant treatment in general practices and at a specialist clinic. *Int J Prosthodont* 1998; 11(4):351-5.
15. Esposito M, Ekstubb A, Grondahl K. Radiological evaluation of marginal bone loss at tooth surfaces facing single Brånemark implants. *Clin Oral Implants Res* 1993; 4(3):151-7.
16. Scheller H, Urgell JP, Kultje C, Klineberg I, Goldberg PV, Stevenson-Moore P, and others. A 5-year multicenter study on implant-supported single crown restorations. *Int J Oral Maxillofac Implants* 1998; 13(2):212-8.
17. Scholander S. A retrospective evaluation of 259 single-tooth replacements by the use of Brånemark implants. *Int J Prosthodont* 1999; 12(6):483-91.
18. Johnson RH, Persson GR. Evaluation of a single-tooth implant. *Int J Oral Maxillofac Implants* 2000; 15(3):396-404.
19. Levine RA, Clem DS 3rd, Wilson TG Jr, Higginbottom F, Saunders SL. A multicenter retrospective analysis of the ITI implant system used for single-tooth replacements: preliminary results at 6 or more months of loading. *Int J Oral Maxillofac Implants* 1997; 12(2):237-42.
20. Brisman AS. Esthetics: a comparison of dentists' and patients' concepts. *J Am Dent Assoc* 1980; 100(3):345-52.
21. Abrams RA, Ayers CS, Vogt Petterson M. Quality assessment of dental restorations: a comparison by dentists and patients. *Community Dent Oral Epidemiol* 1986; 14(6):317-9.
22. Rimmer SE, Mellor AC. Patients' perceptions of esthetics and technical quality in crowns and fixed partial dentures. *Quintessence Int* 1996; 27(3):155-62.
23. Chang M, Ödman PA, Wennström JL, Andersson B. Esthetic outcome of implant-supported single-tooth replacements assessed by the patient and by prosthodontists. *Int J Prosthodont* 1999; 12(4):335-41.

C D A R E S O U R C E
C E N T R E

The CDA Resource Centre has prepared an information package on **single-tooth implants**. CDA members can order a copy of the package for \$10 (plus applicable taxes) by contacting the Resource Centre at tel.: **1-800-267-6354** or **(613) 523-1770**, ext. 2223; fax: **(613) 523-6574**; e-mail: **info@cda-adc.ca**.
