

CLINICAL PRACTICE



Design of a Cast Bar Reinforced Provisional Restoration for the Management of the Interim Phase in Implant Dentistry

Sebastian Saba, DDS, Cert. Prosth.

ABSTRACT

Implant therapy is becoming the treatment of choice for the replacement of teeth in partially edentulous arches. The interim phase of implant treatment often presents particular problems because of the position of the remaining teeth, their periodontal status, and the loss of vertical dimension of occlusion. This case report will discuss the design and fabrication of a cast bar reinforced long-span provisional restoration based on a diagnostic wax-up to simplify the management of the interim phase.

MeSH Key Words: dental implants; dental prosthesis design; dental restoration, temporary/methods.

© J Can Dent Assoc 1999; 65:160-2

The management of the interim phase in dental implant therapy is usually the most difficult phase for both the patient and the clinician.¹ Certain clinical conditions, such as long-span edentulous regions, loss of interocclusal space, and lack of posterior support, present problems for conventional fixed provisional restorations. The long-span and traumatic occlusions allow flexure in the provisional bridge, which results in fractures and washout of the cementing medium and associated complications to the natural abutments and implant recipient sites.

Provisional restorations may be reinforced with a variety of materials to avoid fracture. Youdelis and Faucher² report a technique that uses stainless steel wire to reinforce an autopolymerizing acrylic resin provisional restoration. Binkley and Irvin³ describe heat-processed provisional restorations reinforced with a 16- or 18-gauge cast metal framework.

In order to establish the proper vertical dimension of occlusion and protect the surgical site of the implant during the regenerative and osseointegration phases, a cast metal bar reinforced provisional restoration may be fabricated. The cast bar provides enough rigidity to prevent flexure in the bridge, thus avoiding fractures and cement washout. The added rigidity of a thick cast bar over the implant surgical site allows the pontic region of the provisional restoration to be relieved for post-surgical healing without compromising the patient. The provisional restorations allow for an assessment of the vertical dimension of occlusion and the protection of the surgical site, permitting an uncomplicated interim phase of treatment.⁴

Diagnostic Phase

A 60-year-old woman presented with failing prosthetic appliances (Figs. 1 and 2). Implant therapy was planned to replace the failing

bridge in the upper-right quadrant. The interocclusal space had been compromised and needed to be corrected. Initially, a cross arch fixed acrylic provisional restoration was placed, but the long-span edentulous area, premature washout and multiple fractures created the need for a reinforced fixed provisional restoration.

Study models were mounted and a diagnostic wax-up generated to help identify the occlusal pathology and diagnose the interocclusal violation and esthetic limitations. These limitations can be corrected in the design of the provisional restoration. The wax-up also simplifies communication of treatment plan options to the patient and helps him or her make a better informed decision. (Figs. 3, 4, and 5).

Laboratory Phase

A master cast was generated with an impression of the remaining prepared abutments, and a wax-bar pattern, adapted to cover

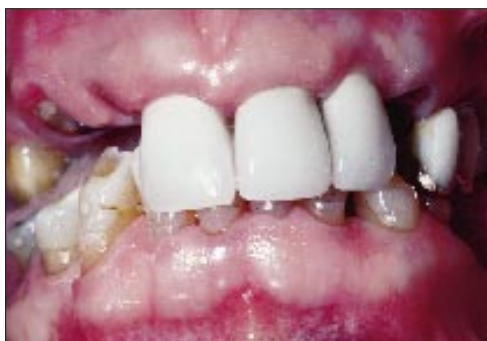

Fig. 1: Intraoral view of pre-operative condition.

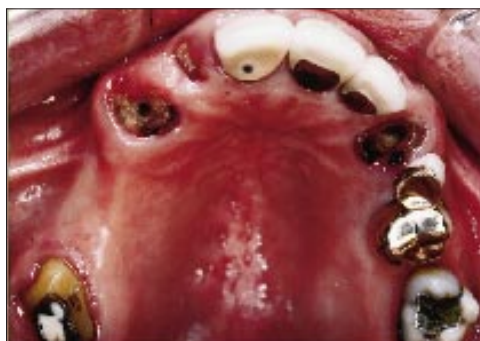

Fig. 2: Intraoral view of pre-operative condition.

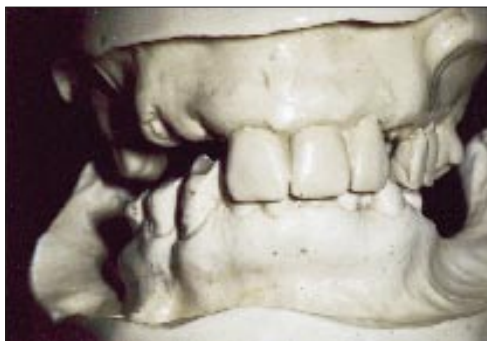

Fig. 3: Mounted study models.

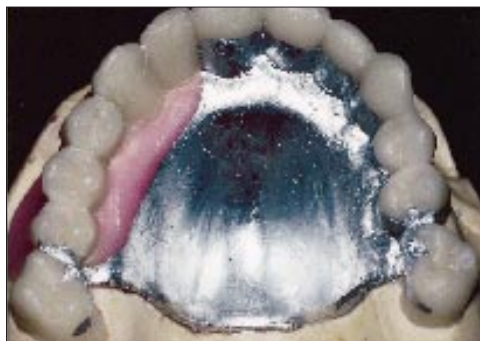


Fig. 4: Diagnostic wax-up.

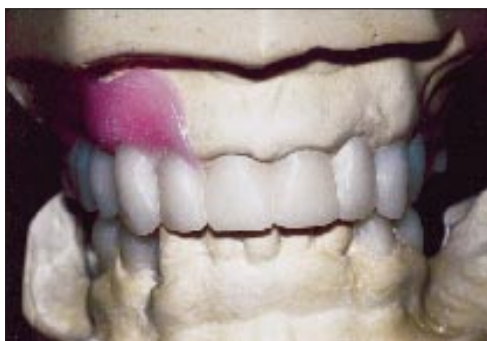

Fig. 5: Diagnostic wax-up.

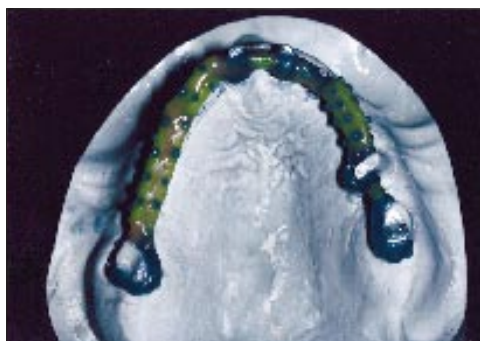


Fig. 6: Wax bar pattern on abutment master cast.

the lingual and proximal surfaces of each abutment (**Fig. 6**), was sprued, invested and cast in the alloy of choice (**Fig. 7**). A transparent index of the original provisional restoration allowed us to duplicate its contours, facilitating patient acceptance (**Fig. 8**). The cast bar was adapted to the master cast and liquid acrylic opaque was applied (**Fig. 9**). The final wax-up was completed (**Figs. 10 and 11**) and heat processed with tooth-coloured acrylic (**Fig. 12**). The cast metal bar reinforced provisional restoration was then ready for insertion (**Fig. 13**).

Conclusion

This long-span, long-term provisional restoration allows the management of implant surgery phases in a predictable fashion while maintaining the patient in a comfortable, problem-free fixed provisional stage. Occlusal stability and vertical dimension were maintained because of greater wear resistance of the hardened laboratory-processed acrylic and the rigid cast bar reinforcement.

After an acceptable period of time, the occlusion and contours developed in the provisional

restoration were duplicated in the final restoration. ■

Dr. Saba has a private practice in prosthetic and implant dentistry in Montreal, Que. He is also a lecturer at the Faculty of Dentistry at McGill University.

Reprint requests to: Dr. Sebastian Saba, 3550 Côte Des Neiges, Suite 240, Montreal, QC H3H 1V4.

The author has no declared financial interest in any company manufacturing the types of products mentioned in this article.

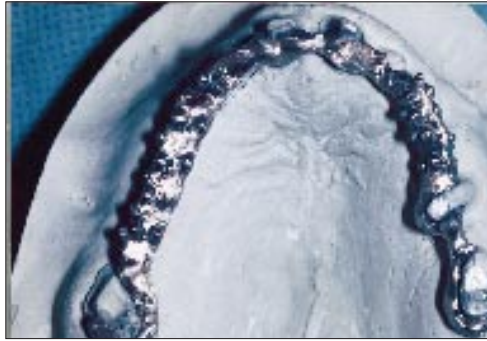


Fig. 7: Cast metal bar on abutment master cast.

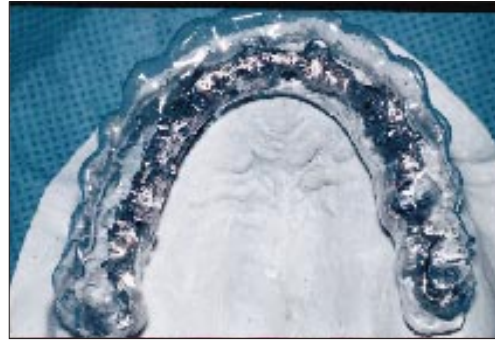


Fig. 8: Transparent index on abutment master cast.

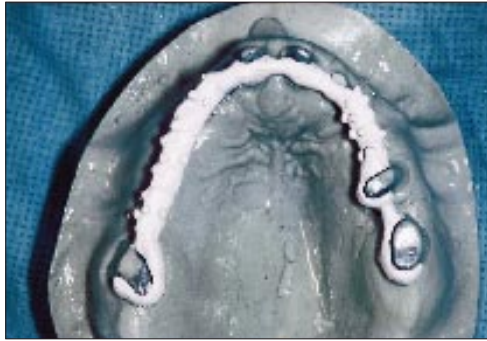


Fig. 9: Opaque applied to cast metal bar.

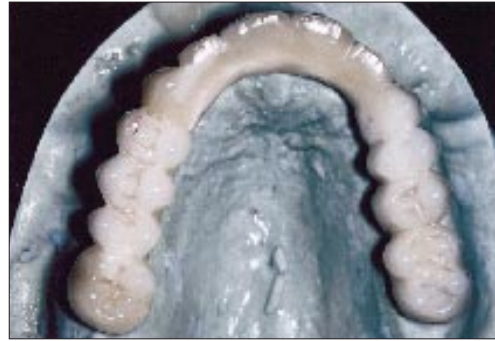

Fig. 10: Completed wax-up of provisional restoration incorporating cast metal bar.

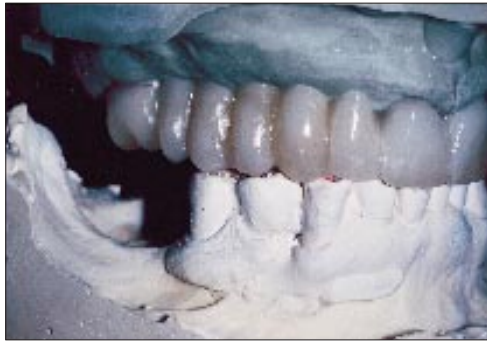

Fig. 11: Completed wax-up of provisional restoration incorporating cast metal bar.

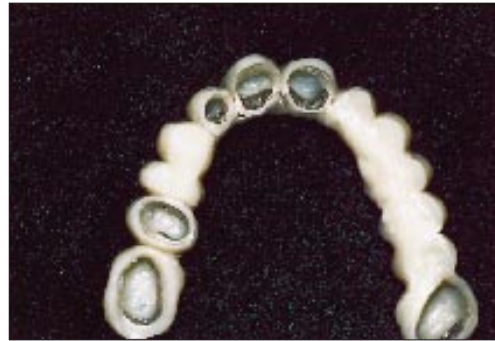

Fig. 12: Heat processed provisional restoration incorporating cast metal bar.

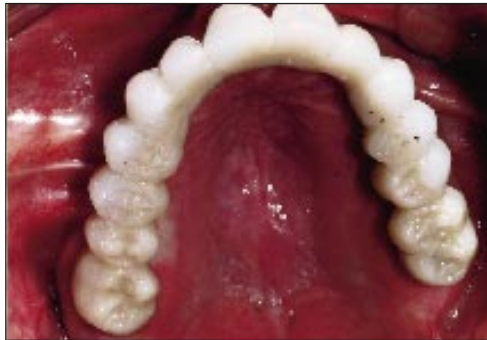

Fig. 13: Intra-oral view of cast metal bar reinforces provisional restoration.

References

1. Moscovitch M, Saba, S. The use of a provisional restoration in implant dentistry: a clinical report. *Int J Oral Maxillofac Implants* 1996; 11:395-9.
2. Youdelis RA, Faucher R. Provisional restorations: an integrated approach to periodontics and restorative dentistry. *Dent Clin North Am* 1980; 24:285-303.
3. Binkley CJ, Irvin PT. Reinforced heat-processed acrylic resin provisional restorations. *J Prosthet Dent* 1987; 57:689-93.
4. Saba, S. Anatomically correct soft tissue profiles using fixed detachable provisional implant restorations. *J Can Dent Assoc* 1997; 63:767-70.